



## Dysplasia epiphysealis hemimelica: A case report

### Hemimelična epifizealna displazija

Dalibor V. Jovanović\*, Milena B. Ilić\*, Miloš Z. Milosavljević†, Zorica Mihajlović†, Radiša H. Vojinović‡, Slobodanka Lj. Mitrović\*†, Goran Azanjac§

\*Faculty of Medical Science, University of Kragujevac, Kragujevac, Serbia;

†Department of Pathology, ‡Department of Radiology, §Clinic of Surgery, Clinical Center Kragujevac, Kragujevac, Serbia

#### Abstract

**Introduction.** Dysplasia *epiphysealis hemimelica*, also known as Trevor's disease, is an extremely rare skeletal developmental disorder of unknown etiology, characterized by an osteocartilaginous outgrowth of one or more epiphyses or of a tarsal bone during childhood. **Case report.** We presented a sporadic case of dysplasia *epiphysealis hemimelica* developed in the talus. A 6-year-old boy complained of swelling of his right ankle joint, with painful and reduced movements. Radiographies suggested excessive overgrowth of the dorsomedial aspect of the talus. The tumor was surgically excised and the gross and histological findings were consistent with those of osteochondroma. **Conclusion.** Dysplasia *epiphysealis hemimelica* is diagnosed by clinical, radiographic and histopathological examination. Early diagnosis is important for the condition to be treated before the deformity becomes disabling.

#### Key words:

osteochondrodysplasias; talus; pain; diagnosis; orthopedic procedures; treatment outcome.

#### Apstrakt

**Uvod.** Hemimelična epifizealna displazija, takođe poznata i kao Trevorova bolest, ekstremno je redak poremećaj razvoja skeleta nepoznate etiologije, koji se karakteriše koštanohrskavičavom proliferacijom, lokalizovanom na jednoj ili više epifiza ili na talusu, u toku detinjstva. **Prikaz bolesnika.** U radu je prikazan bolesnik sa hemimeličnom epifizealnom displazijom lokalizovanom na talusu. Kod 6-godišnjeg dečaka bolest se prezentovala otokom desnog skočnog zgloba, bolom i otežanim pokretima. Radiografija je ukazala na postojanje izrasline na dorzomedijalnoj strani talusa. Tumor je ekscidiran, a makroskopski i histološki nalaz bio je identičan osteohondromu. **Zaključak.** Hemimelična epifizealna displazija se dijagnostikuje kliničkim, radiološkim i patohistološkim pregledom. Rana dijagnoza je važna, da bi se pravovremenom terapijom sprečio nastanak deformiteta.

#### Ključne reči:

osteohondrodysplazije; talus; bol; dijagnoza; ortopedске procedure; lečenje, ishod.

#### Introduction

Historically, dysplasia *epiphysealis hemimelica* (DEH) has been referred to by many names. It was originally described as "tarsomegalie" in 1926 by Mouchet and Belot<sup>1</sup>. In 1950 Trevor used the name tarso-epiphysial aclasis, and this abnormality is also commonly referred to as Trevor's disease<sup>2</sup>. Subsequently, in 1956 Fairbank<sup>3</sup> coined the current most frequently used term dysplasia *epiphysealis hemimelica* (*hemi* – half and *melos* – limb). According to Fairbank, DEH refers to a developmental disorder, which is confined to the medial or lateral half of an epiphysis of a single limb.

The etiology and pathogenesis of DEH are still not clear. DEH can be differentiated from osteochondroma of long bones using clinical, radiologic and pathologic param-

eters and this is an instructive example for the necessity of interdisciplinary collaboration in the assessment of bone dysplasias<sup>4,5</sup>.

We reported the clinical, pathological and radiological features of our case both for the extreme rarity of dysplasia *epiphysealis hemimelica*.

According to our knowledge, this is the first description of DEH in the Serbian literature.

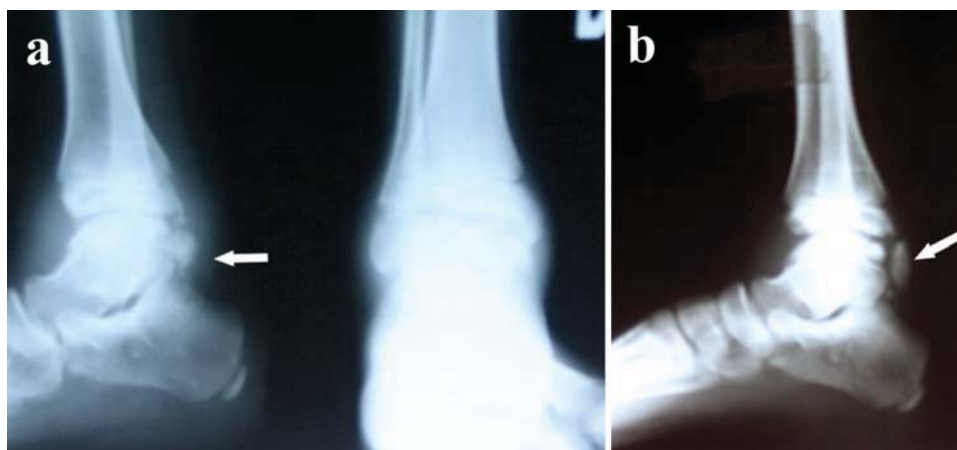#### Case report

A 6-years-old boy was admitted to the hospital for treatment because of motion pain and restriction of the right ankle. The patient had no history of trauma or excessive symptoms. The family history was negative for bone deformity or joint problems. At physical examination a painless

and hard protrusion could be palpated on the dorsomedial aspect of the right ankle. The neurologic examination was intact. Muscle wasting was not noted in the lower extremity. Standard laboratory blood parameters (blood count, coagulation, electrolytes, kidney function tests, liver function tests, and thyroid function tests) were all within the normal range. Radiographs showed an abnormal ossified mass occupying the dorsomedial aspect of the talus (Figure 1a). No areas of pathological contrast enhancement of muscles and subcutaneous tissue or joint effusion were present. Surgery was proposed and performed to improve the range of ankle motion.

endochondral ossification were observed, i.e. the columns of chondrocytes were disorganized, mineralization was incomplete and bone was incompletely replaced by lamellar bone.

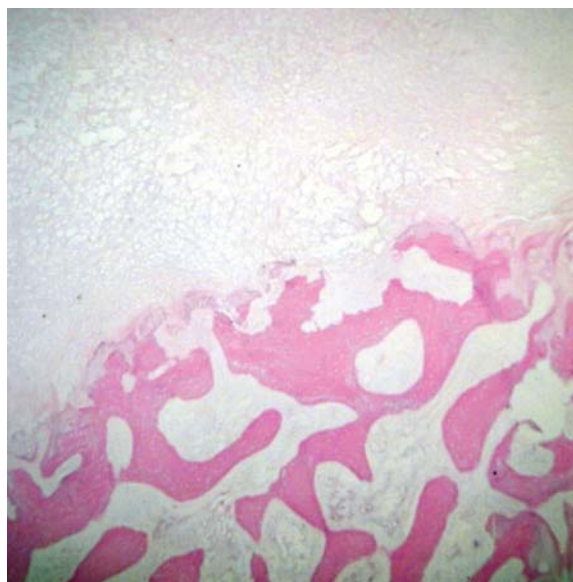
Eleven months later the patient again had pain and restriction in the range of right ankle motion, and visited our hospital. New radiography verified recidive (Figure 1b). Surgery was performed again and the specimen was sent for pathological examination. Again, the result showed that the trabecular bone was covered by a thick irregular cap of cartilage, suggestive of an osteochondroma.



**Fig. 1 – a) Preoperative radiographs (anteroposterior/lateral projection) and b) Radiograph of the recidive, showed an osteocartilaginous protuberance of the talus.**

Histopathologically, resected specimen taken from the lesion, showed a typical appearance of osteochondroma (Figure 2). The periphery of the bone lesion was

Actually, two years after the surgery, the boy had a complete range of motion and walking without limping and did not complain of pain in the right ankle during daily activity. The radiographs demonstrated no progression of osteoarthritic changes in the ankle joint nor further expansion of this osteocartilaginous lesion.



**Fig. 2 – Photomicrograph of a specimen showing the appearance of the osteochondroma (hematoxylin-eosin staining, original magnification  $\times 200$ ).**

covered by a cartilaginous cap. The cartilage cap was lobulated and lobules were arranged around blood vessels. At the base of the cap, areas of incomplete and irregular

### Discussion

Trevor's disease appears in the latest International Nomenclature of Constitutional Disorders of Bone, the Group 31: "disorganized development of cartilaginous and fibrous components of the skeleton"<sup>6</sup>. In that list it is recorded as sporadic in inheritance and with no evidence of malignant transformation.

There are three forms of DEH based on its extent and distribution: a localised form involving only one *epiphysis*, a classic form involving more than one area in a single limb and a generalised or severe form involving the whole lower limb, from pelvis to foot<sup>7</sup>. The reported incidence is 1 in million and approximately 200 cases of DEH have been reported since 1957<sup>8</sup>.

The etiology and pathogenesis of DEH are not known. Its origin and evolution have, initially, similarities to the development and growth of the secondary ossification centers in the *epiphysis* and show centrifugal mode of growth, probably induced by invasion of capillary vessels followed by endochondral ossification<sup>9</sup>. A recent molecular study of DEH demonstrated normal expression levels of

EXT1 and EXT2 genes, and therefore a normal Indian Hedgehog pathway of cell growth, comparable to normal growth plate<sup>10</sup>. Osteochondroma, on the other hand, has low expression levels of EXT1 and EXT2 genes because of gene mutation. These findings strongly favor the distinction of DEH and osteochondroma as separate entities<sup>10</sup>. Perl et al.<sup>11</sup> found that the cellular phenotype of clustered chondrocytes in DEH exhibited characteristics of chondroprogenitor cells and terminally differentiated cells, suggesting dysregulation of the resident progenitor cells<sup>11</sup>. Limited data are available on the entity, mainly consisting of small case series.

Boys are affected approximately three times as often as girls<sup>12</sup>. The age of onset is usually between 2 and 14 years<sup>13</sup>. DEH commonly affects the lower extremity (tarsus, distal tibia, and distal femur) on one side of the body and often is restricted to either the medial or the lateral side of the limb (hemimelic)<sup>12</sup>. Although asymmetrical involvement has been reported, the lesions typically affect only one side of the joint, with the medial side affected twice as frequently as the lateral side<sup>14</sup>. In approximately 2/3 of the cases, more than one epiphysis is affected<sup>15</sup>.

The most common symptom of DEH is painless swelling or deformity, and patients may complain of pain or decreased range of motion<sup>14</sup>. Radiographic findings are characteristic for DEH. Early lesions consisted of an irregular mass with multicentric ossification arising from either the lateral or the medial half of the affected epiphysis or tarsal bone; later this fused with the adjacent bone and resembled an exostosis<sup>16</sup>.

Histopathologically, it was not possible to distinguish DEH from osteochondroma<sup>17</sup>. The lesion may be a pedunculated bone mass with a cartilaginous cap, or it may be seen only as an enlarged irregularity of the articular surface<sup>14</sup>. Histologic findings include clumping of chondrocytes in a fibrillary chondroid matrix and immunohistochemical positive expression of Indian hedgehog/parathyroid hormone-like hormone (IHH/PTHrP)<sup>10</sup>.

DEH should be differentiated from other osteocartilaginous lesions such as synovial chondromatosis, capsular or para-articular chondroma, and particularly osteochondroma<sup>11</sup>. Differential diagnoses also include *myositis ossificans*, infection, chronic infantile neurologic, cutaneous, and articular (CINCA) syndrome, tumoral calcinosis, and vascular or parasitic calcification<sup>18</sup>.

The treatment of DEH is still discussed in the literature. Because of the variety of location and the extent of involvement, patients must be treated on an individual basis<sup>14</sup>. Treatment ranges from simple observation to surgical excision. Asymptomatic lesions may be treated nonsurgically since there is no known risk of malignant transformation. Surgical intervention is more frequently required for these lesions than for solitary osteochondromas because the epiphyseal location is often associated with pain, deformity or loss of normal mechanical function<sup>8,19</sup>. Surgery is often more directed at improving joint congruity to lessen subsequent development of secondary osteoarthritis; thus, treatment at an early stage of disease improves outcome<sup>4,19</sup>. If the lesion is extraarticular, as in our case, simple mass excision yields favourable results.

The prognosis of DEH is variable, and depends on the location and size of the lesion. If the lesion is intraarticular, resection may increase the risk of degenerative joint disease even further. In all cases, there is a risk of recurrence of this disease until the epiphyses are closed. Continuous monitoring may be needed.

## Conclusion

Dysplasia *epiphysealis hemimelica*, a rare deformity of unknown etiology, is diagnosed by clinical and radiographic examination. Early diagnosis is important for the condition to be treated before the deformity becomes disabling. Surgery is considered the treatment of choice, although surgical correction may lead to degenerative arthritis and instability of the ankle joint.

## R E F E R E N C E S

1. Mouchet A, Belot J. La tarsomegalie. J Radiol Electrol 1926; 10: 289–93.
2. Trevor D. Tarso-epiphyseal aclasis: a congenital error of epiphyseal development. J Bone Joint Surg Br 1950; 32-B(2): 204–13.
3. Fairbank TJ. Dysplasia epiphysealis hemimelica (tarso-epiphyseal aclasis). J Bone Joint Surg Br 1956; 38-B(1): 237–57.
4. Glick R, Khalidi L, Ptaszynski K, Steiner GC. Dysplasia epiphysealis hemimelica (Trevor disease): a rare developmental disorder of bone mimicking osteochondroma of long bones. Hum Pathol 2007; 38(8): 1265–72.
5. Zlotolow DA, Mills J, Ezaki M, Carter PR, Goitz RJ, Zornitzer M. Epiphyseal osteochondromas of the upper limb: a report of 7 cases. J Pediatr Orthop 2012; 32(5): 541–6.
6. Hall CM. International nosology and classification of constitutional disorders of bone (2001). Am J Med Genet 2002; 113(1): 65–777.
7. Aşgöz EM, Slomic AM, Marton D, Rigault P, Finidori G. The variable manifestations of dysplasia epiphysealis hemimelica. Pediatr Radiol 1985; 15(1): 44–9.
8. Struijs PAA, Kerkhoffs GM, Besselaar PP. Treatment of dysplasia epiphysealis hemimelica: a systematic review of published reports and a report of seven patients. J Foot Ankle Surg 2012; 51(5): 620–6.
9. Blumer MJ, Schwarzer C, Pérez MT, Konakci KZ, Fritsch H. Identification and location of bone-forming cells within cartilage canals on their course into the secondary ossification centre. J Anat 2006; 208(6): 695–707.
10. Bovée JV, Hameetman L, Kroon HM, Aigner T, Hogendoorn PC. EXT-related pathways are not involved in the pathogenesis of dysplasia epiphysealis hemimelica and metachondromatosis. J Pathol 2006; 209(3): 411–9.
11. Perl M, Brenner RE, Lippacher S, Nelitz M. Dysplasia epiphysealis hemimelica: a case report with novel pathophysiologic aspects. Clin Orthop Relat Res 2009; 467(9): 2472–8.
12. Smith EL, Raney EM, Matzkein EG, Fillman RR, Yandow SM. Trevor's disease: the clinical manifestations and treatment of dysplasia epiphysealis hemimelica. J Pediatr Orthop B 2007; 16(4): 297–302.

13. *Freihaut RB, O'Keane CJ, Stephens MM.* Dysplasia epiphysealis hemimelica with associated osteochondral lesion of the talus: a case report and review of the literature. *Foot Ankle Int* 2007; 28(6): 727–30.
14. *Bhosale SK, Dholakia DB, Sheth BA, Srivastava SK.* Dysplasia epiphysealis hemimelica of the talus: two case reports. *J Orthop Surg (Hong Kong)* 2005; 13(1): 79–82.
15. *Rosero VM, Kiss S, Terebesy T, Köllö K, Szöke G.* Dysplasia epiphysealis hemimelica (Trevor's disease): 7 of our own cases and a review of the literature. *Acta Orthop* 2007; 78(6): 856–61.
16. *Murphey MD, Choi JJ, Kransdorf MJ, Flemming DJ, Gannon FH.* Imaging of osteochondroma: variants and complications with radiologic-pathologic correlation. *Radiographics* 2000; 20(5): 1407–34.
17. *Fletcher C, Unni K, Mertens F.* Pathology and genetics of tumours of soft tissue and bone. In: *Fletcher C, Unni K, Mertens F*, editors. World Health Organization classification of tumours. Lyon: IARC Press; 2002. p. 229–30.
18. *Araujo CR, Montandon S, Montandon C, Teixeira KS, Moraes FB, Moreira MA.* Best cases from the AFIP: dysplasia epiphysealis hemimelica of the patella. *Radiographics* 2006; 26(2): 581–6.
19. *Kuo RS, Bellemore MC, Monsell FP, Frawley K, Kozłowski K.* Dysplasia epiphysealis hemimelica: clinical features and management. *J Pediatr Orthop* 1998; 18(4): 543–8.

Received on January 11, 2013.

Accepted on May 24, 2013.

OnLine-First March, 2014.