

ORIGINAL ARTICLE / ОРИГИНАЛНИ РАД

Selective laser trabeculoplasty as adjunctive treatment in pseudoexfoliative glaucoma patients

Marko Kantić¹, Dušan Todorović^{2,3}, Rada Zečević¹, Tatjana Šarenac-Vulović^{2,3}¹Belgrade Ophthalmological Center, Belgrade, Serbia;²Kragujevac Clinical Center, Clinic of Ophthalmology, Kragujevac, Serbia;³University of Kragujevac, Faculty of Medical Sciences, Department of Ophthalmology, Kragujevac, Serbia**SUMMARY**

Introduction/Objective Pseudoexfoliation syndrome is characterized by abnormal production and accumulation of fibrillar, white-gray, “dandruff-like” material in almost all ocular structures. The aim of this study was to examine effect of selective laser trabeculoplasty in pseudoexfoliation glaucoma patients.

Methods Thirty-two patients (47 eyes) with medically uncontrolled pseudoexfoliation glaucoma were enrolled. All the patients could not reach target intraocular pressure with maximal tolerated medical therapy before treatment. Selective laser trabeculoplasty was performed with about 100 non-overlapping spots. Intraocular pressure was measured one hour, seven days, four weeks, three, six, twelve, eighteen, and twenty-four months after the procedure.

Results The mean base intraocular pressure was 23.45 mmHg (SD = 3.07). Statistically significant reduction of mean intraocular pressure was observed at all follow-ups except one hour after treatment. Mean intraocular pressure after 24 months was 18.39 mmHg (SD = 1.82). Success, defined as intraocular pressure reduction from base intraocular pressure by more than 20% after 24 months, was achieved in 27 eyes (57.45%). We did not find any influence of sex and age on selective laser trabeculoplasty effects in pseudoexfoliative glaucoma patients. Baseline intraocular pressure is proved to be a reliable predictor of intraocular pressure-lowering effect, as there was a strong correlation between baseline intraocular pressure and the percentage of reduction of intraocular pressure after 24 months ($r = 0.71$, $p < 0.01$).

Conclusion Selective laser trabeculoplasty is a safe and effective method for the reduction of intraocular pressure in pseudoexfoliation glaucoma patients and should be used more often in this challenging form of glaucoma. Baseline intraocular pressure seems to be a reliable predictor of success.

Keywords: selective laser trabeculoplasty; pseudoexfoliative glaucoma; intraocular pressure

INTRODUCTION

Pseudoexfoliation syndrome is a systemic disease of the extracellular matrix with primary ocular manifestations. Syndrome is characterized by an abnormal production and accumulation of fibrillar, white-gray, “dandruff-like” material in almost all ocular structures. The pseudoexfoliative material is produced by cells of the anterior segment of the eye. This material is insoluble and floats in the aqueous humor, and is most often deposited on the structures of the eye in contact with aqueous humor, such as the lens, ciliary body, corneal endothelium, and trabecular meshwork (TM). In clinical presentation, it is usually seen on the pupillary margin, anterior capsule of the lens, and on TM. Pseudoexfoliative material can disturb the function of goblet cells in conjunctiva, which causes tear film instability and dry eye syndrome. Structure of this material is fibrillar and it contains parts of basal membranes and some enzymes [1, 2, 3].

Accumulation of this material in the TM can lead to its obstruction and to increased intraocular pressure (IOP). Pigment granules can be seen in the anterior chamber angle and they are probably released from the iris while rubbing

on the fibrillar deposits on the lens. Pigment granules can participate in clogging of TM.

Pseudoexfoliation (PXF) syndrome is the most common cause of secondary glaucoma, although not all patients with pseudoexfoliation syndrome will encounter this disease [1].

It is known that PXF glaucoma is a very difficult form of glaucoma to treat [2], with high IOP and rapid unpredictable progression of the disease [4]. It is quite challenging for treatment because it often responds poorly to medical therapy. Treatment of glaucoma includes medical, laser, and surgical treatment.

Laser trabeculoplasty as a method for lowering IOP has been in use for more than 40 years. It was first introduced by Wise and Witter in 1979 [5]. At that time, argon laser was user for this method, so it was called argon laser trabeculoplasty (ALT). ALT has shown good results in lowering IOP although its mechanism of action has never been completely understood. Later it was noticed that it is often followed by scarring in the iridocorneal angle and occurrence of peripheral anterior synechia. This finding limited ALT to a single application in one patient.

First results with selective laser trabeculoplasty in lowering IOP in patients with open angle glaucoma were presented in 1995 by

Received • Примљено:

August 23, 2021

Accepted • Прихваћено:

March 17, 2022

Online first: March 28, 2022**Correspondence to:**Dušan TODORVIĆ
Clinic of Ophthalmology
Kragujevac Clinical Center
Zmaj Jovina 30
34000 Kragujevac, Serbia
drdusantodorovic@yahoo.com

Park and Latina [6]. This method is in commercial use since 2001 [6]. For this procedure, Q-switched, frequency-doubled laser with a wavelength of 532 nm is used. Laser beam is directed at TM and duration of the pulse of laser energy is only 3 ns. Small amount of laser energy released is enough to heat and damage only pigmented cells of TM that absorbs light energy to a greater extent than surrounding non pigmented cells of TM.

The aim of this study was to analyze the effects of selective laser trabeculoplasty on patients with medically uncontrolled PXF glaucoma. We examined the significance of IOP reduction compared to baseline IOP during follow-up period of 24 months, influence of baseline IOP value to the percentage of reduction, as well as influence of demographic characteristics.

METHODS

In this prospective, nonrandomized, self-controlled, interventional cohort study 32 patients (47 eyes) with medically uncontrolled pseudoexfoliation glaucoma were enrolled to assess the response to SLT. With the approval of institutional Committee on Ethics and according to the tenets of the Declaration of Helsinki, all the patients gave their written consent at the beginning of the study.

All patients could not reach target IOP with maximal tolerated medical therapy. Patients underwent detailed ophthalmological examination before procedure: Snellen visual acuity, slit lamp examination of anterior segment, gonioscopic examination of anterior chamber angle, optic disc examination and visual field testing which confirmed diagnosis.

The study was conducted at an ophthalmological hospital, Belgrade Ophthalmological Center, Belgrade, Serbia from June 1, 2019 until June 1, 2021. All the procedures were done by one experienced ophthalmologist.

Selective laser trabeculoplasty was performed over 360 degrees of TM.

IOP was measured one hour, seven days, four weeks, three, six, 12, 18, and 24 months after the procedure. Baseline characteristics of all the patients were recorded at the beginning of the study. These include the following: age, sex, diagnosis, baseline IOP, and the number and the type of used medications.

Patient inclusion criteria were IOP above target IOP with maximal tolerated medical therapy in patients with pseudoexfoliation glaucoma. Patients had to be older than 18 years to participate in the study.

Exclusion criteria were advanced-stage glaucoma; patients who underwent any previous antiglaucoma laser or surgical procedure; eyes with previous anterior segment surgery, such as cataract extraction within the previous six months, and patients with baseline IOP > 30 mmHg with fully medicated local and per oral antiglaucomatous treatment (carbonic anhydrase inhibitors). Patients who could not be followed for at least 24 months were also excluded and their results were removed.

During four weeks before treatment, IOP was measured at least two times in all the patients in order to get the

baseline IOP as a mean value of these measurements. IOP was measured using the Goldmann applanation tonometer.

Immediately before treatment, IOP was measured and after that 0.5% solution of apraclonidine was instilled in the treated eye with the aim to prevent IOP spikes [7, 8].

The procedure was performed with a topical anesthetic – benoxinate hydrochloride 0.4%. With the patient seated at the laser slit-lamp system, a Goldmann three-mirror gonioscopes or Latina lens was placed on the eye with methylcellulose 2%.

All eyes were treated with Ellex, Tango® SLT laser (Ellex Medical Pty. Ltd, Adelaide, Australia) a frequency-doubled, Q-switched Nd: YAG laser emitting at 532 nm with fixed pulse duration of 3 ns and a spot size of 400 µm. Treatment began at 0.8 mJ and was titrated according to the response. If cavitation bubbles appeared the laser energy was reduced by 0.1 mJ until no bubbles formed and treatment was continued at this energy level. If no cavitation bubble was observed, the pulse energy was increased by 0.1 mJ until bubble formation and then decreased as described above. Sometimes higher energy was required for the treatment of the superior, less pigmented angle. Approximately 100 adjacent, but non overlapping, laser spots were placed over 360° of the TM [8].

Immediately after the laser treatment, nepafenac eye drops were administered once in treated eye than three times daily for three days. The IOP in the treated eye was measured and recorded one hour after surgery. The same preoperative anti-glaucoma medication regimen was continued. Patients were evaluated at one hour, one week, and at one, three, six, 12, 18, and 24 months. At each visit, the visual acuity and IOP were measured, and slit-lamp examination of the anterior segment was performed. All major and minor complications and complaints were recorded and treated appropriately.

Complete success of treatment was defined as IOP reduction of 20% and more and qualified success reduction of IOP between 10% and 20%.

The data was analyzed using IBM SPSS Statistics, Version 22.0 (IBM Corp., Armonk, NY, USA), using ANOVA for repeated measures and t-test for dependent samples. A p value of less than 0.05 was considered to be statistically significant.

RESULTS

From 47 eyes of 32 patients initially enrolled, 25 patients (38 eyes) completed the study. Seven patients (nine eyes) were sent for other surgical treatment or to repetition of SLT due to high IOP during follow-up period and they were excluded from the study. Patients that did not come on all follow-ups were also excluded, and their data erased.

Average age of our patients was 73.76 (SD = 5.79) and baseline IOP was 23.13 (SD = 3.06). There were 13 men (21 eyes) and 12 women (17 eyes) in our group. Baseline characteristics of included patients are presented in Table 1.

Seven days after the treatment, mean IOP was reduced to 18.26 (SD = 2.65). One month after SLT, mean IOP dropped to 16.74 (SD = 2.06). The lowest mean IOP was recorded three months after treatment and it was

Table 1. Baseline characteristics of the patients

Characteristics		Male	Female	All
Number (%)	Patients	13 (52)	12 (48)	25
	Eyes	21 (55.26)	17 (44.74)	38
Age (years)	Mean	75.19	72	73.76
	SD	5.19	6.14	5.79
	Min	67	60	60
	Max	82	83	83
Base IOP	Mean	23.14	23.12	23.13
	SD	2.89	3.35	3.06
	Min	19	18	18
	Max	29	30	30

IOP – intraocular pressure; SD – standard deviation; Min – minimal value; Max – maximal value

15.84 mmHg (SD = 1.87) or 31.51% reduction from the baseline. After that period, mean IOP showed mild but constant raise and 24 months after treatment the mean IOP was 18.03 mmHg (SD = 1.64) ($p < 0.01$) and that was 5.11 mmHg lower than baseline, or 22.07%. It is shown in Tables 2 and 3, and Figure 1.

Table 2. Intraocular pressure values over time (mm Hg)

IOP values	Means	SD	Min	Max
Baseline	23.13	3.06	18	30
1 hour	22.74	4.42	14	33
7 days	18.26	2.65	15	23
1 month	16.74	2.06	12	21
3 months	15.84	1.87	10	21
6 months	16.37	2.01	14	20
12 months	16.95	1.74	13	21
18 months	17.26	1.81	12	21
24 months	18.03	1.64	14	21

IOP – intraocular pressure; SD – standard deviation; Min – minimal value; Max – maximal value

Table 3. Intraocular pressure (IOP) reduction over time

Time	IOP reduction	
	mm Hg	%
1 hour	0.39	1.71
7 days	4.87	21.05
1 month	6.39	27.65
3 months	7.29	31.51
6 months	6.76	29.24
12 months	6.18	26.73
18 months	5.87	25.37
24 months	5.11	22.07

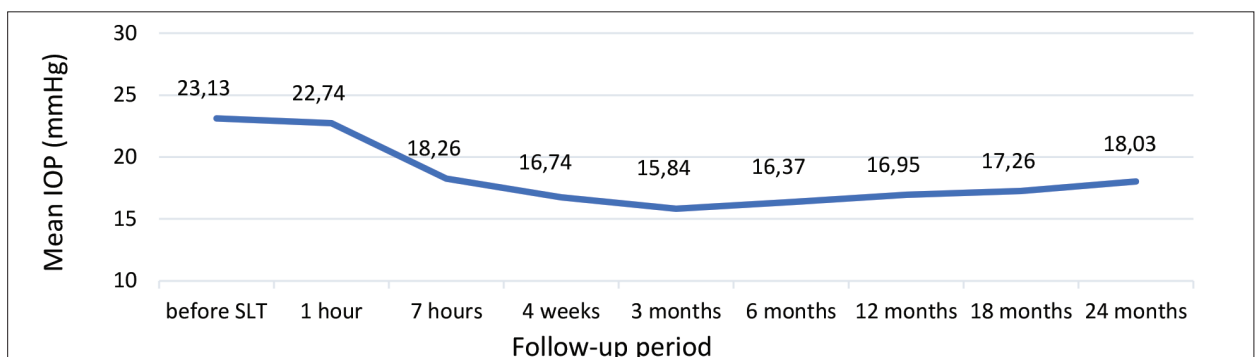


Figure 1. Mean intraocular pressure (IOP) values during the follow-up of 24 months

Success of treatment was defined as reduction of IOP of at least 20% from baseline IOP. Eleven eyes did not achieve IOP reduction of 20% after 24 months. When we take into account the nine eyes that were referred to surgery and 11 eyes that did not achieve IOP reduction of 20% or more, it makes 20 out of 47 eyes, or 42.55%. Success, after 24 months, was achieved in 27 eyes (57.45%).

Paired-samples t-test was used to compare the means of baseline IOP and IOP 24 months after treatment and difference is highly statistically significant ($p < 0.001$).

We also investigated the role of baseline IOP values as a predictor of SLT response in patients with pseudoexfoliative glaucoma. There was a strong correlation between the mean base IOP and the mean percentage of reduction after 24 months from treatment ($r = 0.71$, $p < 0.01$) (Table 4, Figure 2).

Table 4. Correlation between baseline intraocular pressure (IOP) and reduction percentage

		Baseline IOP	Reduction
Baseline IOP	Pearson correlation	1	0.710**
	Sig. (2-tailed)		0.000
	n	38	38
Reduction	Pearson correlation	0.710**	1
	Sig. (2-tailed)	0	
	n	38	38

**Correlation significant – $p < 0.01$

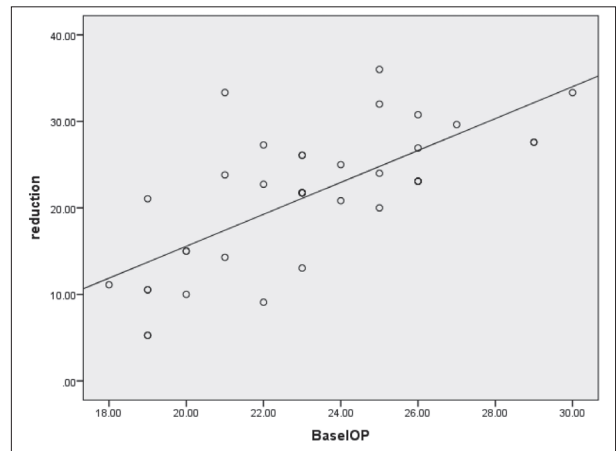


Figure 2. The influence of baseline intraocular pressure (IOP) on selective laser trabeculoplasty reduction percentage – significant correlation ($r = 0.71$, $p < 0.01$)

Most significant side effect of SLT was postoperative IOP spike, which was noticed in 10 eyes (26.31%) one hour after treatment. In six of them (15.79%), IOP spike was higher or equal with 5 mmHg. After seven days there were no eyes with IOP higher than baseline. In 11 eyes (28.95%) mild anterior chamber inflammation was present one hour after treatment, but at seven days all eyes were quiet. One patient complained at ocular discomfort, but did not require discontinuation of the treatment. There were no corneal complications.

DISCUSSION

In previous papers selective laser trabeculoplasty was proved to reduce IOP in primary open angle glaucoma as well as in pseudoexfoliative and pigmentary glaucoma. Although the percentage of reduction was similar in many reports, there were some papers that found reduction as high as 40% and others that reported less than 10% [9–18].

In our group of patients with pseudoexfoliative glaucoma, SLT was used as adjunctive treatment and we achieved mean reduction of IOP after two years of 22.07% from mean baseline IOP that was similar to expected values based on earlier papers [19–23]. At the beginning of the study it looked that reduction of IOP was even higher than compared to reduction found in primary open angle glaucoma, and it was more than 30% at three months, but at 24 months check-up it was the same and even lower than in POAG patients. Thus it seems that lowering effect of SLT in pseudoexfoliative glaucoma patients fades over time. It is possible that the reason for that is continuous releasing of pseudoexfoliative material that clogs iridocorneal and trabecular tissue. Even though the initial IOP lowering effect is accomplished, release of pseudoexfoliative material leads to continuous increase in IOP.

As complete success we defined lowering of IOP for at least 20%. We achieved this result in 57.45% of patients after 24 months. At 12 months this result was 65.96%, which suggests faster fading of SLT IOP reduction effect in PXF glaucoma patients. IOP reduction 10–20% we defined as qualified success, which was achieved in 7.89% after 24 months, so success was accomplished in 78.95% of the eyes that have finished the study or in 63.83% of the eyes that entered the study. Sometimes, even small reduction of IOP could be significant in reaching target IOP for some patients and delaying or avoiding the need for surgical

treatment and value of SLT for these patients should not be underestimated.

We did not find any difference between male and female eyes regarding the SLT response. This finding is consistent with other papers [24]. Also we did not find any influence of age on SLT effects.

Comparing all follow-ups and mean IOP it was obvious that after one month we had almost definite results and we thought that one should wait for one month to see if the SLT response was adequate for the patient, but that there was no reason to wait any longer if the result was not satisfactory.

IOP spike was the most significant side effect that occurred after treatment. It was noticed in 26.31% of the eyes and in 15.79% of the eyes it was higher or equal to 5 mmHg. Some mild anterior chamber inflammation was present in 28.95% of eyes one hour after treatment. At seven days follow-up there were no eyes with IOP higher than baseline and all the eyes were without anterior chamber inflammation. This suggest that SLT in this group of patients is a quite safe method, with no significant side effects. These results are similar to those of some other studies [25, 26, 27].

Our study confirmed that higher baseline IOP predicts higher hypotensive response and higher percentage of IOP reduction from baseline [28, 29].

In this group we did not aim for the reduction in the number of medications used because all the patients were on maximally tolerated medical therapy and did not reach target IOP, and we were looking for additional reduction of IOP, so the mean number of medications did not change before and after the study.

CONCLUSION

Selective laser trabeculoplasty is very effective in lowering IOP in medically uncontrolled patients with pseudoexfoliative glaucoma and should be used more readily in this challenging form of glaucoma. Also, it appears that effect of selective laser trabeculoplasty on those patients fades away with time. Intervention is safe and not accompanied with significant side effects. Baseline IOP seems to be a reliable predictor of IOP-lowering effect. Also, it looks like that definite IOP-lowering results can be estimated after one month.

Conflict of interest: None declared.

REFERENCES

1. Konstas AGP, Ringvold A. Epidemiology of Exfoliation Syndrome. *J Glaucoma*. 2018;27(1):4–11.
2. Sarenac Vulovic T, Pavlovic S, Jakovljevic V, Janicijevic K, Zdravkovic N. Nitric oxide and tumour necrosis factor alpha in the process of pseudoexfoliation glaucoma. *Int J Ophthalmol*. 2016; 9(8):138–42.
3. Todorovic D, Sarenac Vulovic T, Jovanovic S, Janicijevic-Petrovic M, Petrovic N, Kontic M, et al. The impact of pseudoexfoliation and artificial tear application on the tear film stability in a pseudophakic eye. *Srp Arh Celok Lek*. 2018;146(7–8):422–7.
4. Ritch R. Systemic Associations of Exfoliation Syndrome. *Asia Pac J ophthalmol (Phila)*. 2016;5(1):45–50.
5. Wise JB, Witter SL. Argon therapy for open angle glaucoma: a pilot study. *Arch Ophthalmol*. 1979;97(2):319–22.
6. Latina MA, Park C. Selective targeting of trabecular meshwork cells: in vitro studies of pulsed and CW laser interactions. *Exp Eye Res*. 1995;60(4):359–71.
7. Makri OE, Pallikari A, Pagoulatos D, Kagkellaris K, Kostopoulou E, Georgakopoulos C. Micropulse laser trabeculoplasty on pseudoexfoliation glaucoma patients under topical prostaglandin

- analogue monotherapy: 1-year results. Graefes Arch Clin Exp Ophthalmol. 2019;257(2):349–55.
8. Ilveskoski L, Taipale C, Tuunubek R. Selective laser trabeculoplasty in exfoliative glaucoma eyes with prior argon laser trabeculoplasty. Acta Ophthalmologica. 2020;98(1):58–64.
 9. Tekin K, Inanc M, Elgin U. Monitoring and management of the patient with pseudoexfoliation syndrome: current perspectives. Clin Ophthalmol. 2019;13:453–64.
 10. Schweitzer C. Pseudoexfoliation syndrome and pseudoexfoliation glaucoma. J Fr Ophtalmol. 2018;41(1):78–90.
 11. Sharma S, Chataway T, Klebe S, Griggs K, Martin S, Chegeni N, et al. Novel protein constituents of pathological ocular pseudoexfoliation syndrome deposits identified with mass spectrometry. Mol Vis. 2018;24:801–17.
 12. Greslechner R, Spiegel D. Laser Trabeculoplasty in Modern Glaucoma Therapy – a Review. Klin Monbl Augenheilkd. 2019;236(10):1192–200.
 13. Baser G, Cengiz H, Unsal U, Karahan E. The influence of selective laser trabeculoplasty on the success of trabeculectomy. Oman J Ophthalmol. 2018;11(1):28–32.
 14. De Keyser M, De Belder M, De Belder S, De Groot V. Where does selective laser trabeculoplasty stand now? A review. Eye Vis (Lond). 2016;3:10.
 15. Kontic M, Ristic D, Vukosavljevic M. Hypotensive Effect of Selective Laser Trabeculoplasty in Patients with Medically Uncontrolled Primary Open-Angle Glaucoma. Srp Arh Celok Lek. 2014;142(9–10):524–8.
 16. Francis BA, Loewen N, Hong B, Dustin L, Kaplowitz K, Kinast R, et al. Repeatability of selective laser trabeculoplasty for open-angle glaucoma. BMC Ophthalmol. 2016;16:128.
 17. Kent SS, Hutnik CM, Birt CM, Damji K, Harasymowycz P, Si F, et al. A randomized clinical trial of selective laser trabeculoplasty versus argon laser trabeculoplasty in patients with pseudoexfoliation. J Glaucoma. 2015;24(5):344–7.
 18. Katsanos A, Konstas AG, Mikropoulos DG, Quaranta L, Voudouragkaki IC, Athanasopoulos GP, et al. A review of the clinical usefulness of selective laser trabeculoplasty in exfoliative glaucoma. Adv Ther. 2018;35(5):619–30.
 19. Miraftebi A, Nilforushan N, Nassiri N, Nouri-Mahdavi K. Selective laser trabeculoplasty in patients with pseudoexfoliative glaucoma vs primary open angle glaucoma: a one-year comparative study. Int J Ophthalmol. 2016;9(3):406–10.
 20. Sharpe RA, Kammerdiener LL, Williams DB, Das SK, Nutaitis MJ. Efficacy of selective laser trabeculoplasty following incisional glaucoma surgery. Int J Ophthalmol. 2018;11(1):71–6.
 21. Song JSA, Vianna J, Shuba L, Rafuse P, Nicoleta M. Evaluating selective laser trabeculoplasty versus argon laser trabeculoplasty in pseudoexfoliation glaucoma patients. Can J Ophthalmol. 2018;53(1):70–5.
 22. Hutnik C, Crichton A, Ford B, Nicoleta M, Shuba L, Birt C, et al. Selective Laser Trabeculoplasty versus Argon Laser Trabeculoplasty in Glaucoma Patients Treated Previously with 360° Selective Laser Trabeculoplasty: A Randomized, Single-Blind, Equivalence Clinical Trial. Ophthalmology. 2019;126(2):223–32.
 23. Durr GM, Harasymowycz P. The effect of repeat 360-degree selective laser trabeculoplasty on intraocular pressure control in open-angle glaucoma. J Fr Ophtalmol. 2016;39(3):261–4.
 24. McAlinden C. Selective laser trabeculoplasty (SLT) vs other treatment modalities for glaucoma: systematic review. Eye. 2014;28(3):249–58.
 25. Lee J, Kagan D, Roumeliotis G, Liu H, Hutnik C. Secretion of MMP-3 by co-cultured pigmented and non-pigmented human trabecular meshwork cells following selective laser trabeculoplasty. Clin Exp Ophthalmol. 2016;44(1):33–42.
 26. Zhou Y, Pruet CM, Fang C, Khanna CL. Selective laser trabeculoplasty in steroid-induced and uveitic glaucoma. Can J Ophthalmol. 2021:S0008-4182(21)00176-9. Online ahead of print.
 27. Pose-Bazarrá S, López-Valladares MJ, López-de-Ullibarri I, Azuara-Blanco A. Surgical and laser interventions for pseudoexfoliation glaucoma systematic review of randomized controlled trials. Eye (Lond). 2021;35(6):1551–61.
 28. Soboka JG, Giorgis AT, Alemu AM, Hodge WG, Damji KF. Efficacy and Safety of Selective Laser Trabeculoplasty among Ethiopian Glaucoma Patients. J Ophthalmol. 2020;2020:7620706.
 29. Örnek N, Örnek K. Corneal endothelial changes following a single session of selective laser trabeculoplasty for pseudoexfoliative glaucoma. Int Ophthalmol. 2018;38(6):2327–33.

Селективна ласерска трабекулопластика као адјувантна терапија код пацијената са псеудоексфолијативним глаукомом

Марко Контић¹, Душан Тодоровић^{2,3}, Рада Зечевић¹, Татјана Шаренац-Вуловић^{2,3}

¹Београдски офталмолошки центар, Београд, Србија;

²Клинички центар Крагујевац, Клиника за офталмологију, Крагујевац, Србија;

³Универзитет у Крагујевцу, Факултет медицинских наука, Катедра за офталмологију, Крагујевац, Србија

САЖЕТАК

Увод/Циљ Псеудоексфолијативни синдром карактерише абнормална производња и накупљање фибриларног, белосивог материјала сличног перути у готово свим окуларним структурама.

Циљ ове студије био је испитати ефекат селективне ласерске трабекулопластике код пацијената са псеудоексфолијативним глаукомом.

Метод Тридесет два пацијента (47 очију) са медикаментно неконтролисаним псеудоексфолијативним глаукомом била су укључена у студију. Сви пацијенти нису могли постићи терапијски интраокуларни притисак са максимално толерисаном медикаментном терапијом пре почетка лечења. Селективна ласерска трабекулопластика изведена је са око 100 печата који се не преклапају. Интраокуларни притисак мерен је један час, седам дана, четири недеље, три, шест, дванаест, осамнаест и двадесет четири месеца после захвата.

Резултати Средњи базни интраокуларни притисак био је 23,45 mmHg (SD = 3,07). Статистички значајно смањење средњег интраокуларног притиска уочено је код свих кон-

трола осим једног часа након третмана. Средњи интраокуларни притисак након 24 месеца износио је 18,39 mmHg (SD = 1,82). Успех, дефинисан као смањење интраокуларног притиска од базног за више од 20% након 24 месеца, постигнут је код 27 очију (57,45%). Нисмо открили утицај пола и старости на селективне ефекте ласерске трабекулопластике код пацијената са псеудоексфолијативним глаукомом. Показало се да је почетни интраокуларни притисак поуздан предиктор ефекта снижавања интраокуларног притиска, јер је постојала снажна корелација између основног интраокуларног притиска и процента смањења интраокуларног притиска након 24 месеца ($p = 0,71$, $p < 0,01$).

Закључак Селективна ласерска трабекулопластика је сигурна и ефикасна метода за смањење интраокуларног притиска код пацијената са псеудоексфолијативним глаукомом и требало би је чешће користити у овом изазовном облику глаукома. Чини се да је основни интраокуларни притисак поуздан предиктор успеха.

Кључне речи: селективна ласерска трабекулопластика; псеудоексфолијативни глауком; интраокуларни притисак