SYNCHRONOUS MANEC (MIXEDADENO-NEUROENDOCRINE CARCINOMA) OF THE COLON AND RENAL CELL CARCINOMA - CASE REPORT

Bojan Milosevic[1,2], Nenad Markovic[1,2], Rade Markovic[2], Aleksandar Cvetkovic[1,2], Bojan Stojanovic[1,2], Dragce Radovanovic[1,2], Mladen Pavlovic[1,2], Maja Vulovic[4], Vesna Stankovic[3], Jelena Zivkovic[2], Danijela Cvetkovic[5] and Marko Spasic[1,2]

[1]*University of Kragujevac, Faculty of Medical Sciences, Department of Surgery, Kragujevac, Serbia*
[2]*Clinic for General and Thoracic Surgery, Clinical Center Kragujevac, Kragujevac, Serbia*
[3]*University of Kragujevac, Faculty of Medical Sciences, Department of Pathology, Kragujevac, Serbia*
[4]*University of Kragujevac, Faculty of Medical Sciences, Department of Anatomy, Kragujevac, Serbia*
[5]*University of Kragujevac, Faculty of Science, Institute of Biology and Ecology, Kragujevac, Serbia*

Received: 30.10.2019.
Accepted: 18.11.2019.

Corresponding author:

Nenad Markovic,

University of Kragujevac, Faculty of Medical Sciences, Department of Surgery, Kragujevac, Serbia and Clinic for General and Thoracic Surgery Clinical Center Kragujevac, Kragujevac, Serbia

E-mail: dr.nenadmarkovic@yahoo.com

sciendo

UDK: 616-006.6
Ser J Exp Clin Res 2022; 23(2):189-193
DOI: 10.2478/sjecr-2019-0064

ABSTRACT

Synchronous multiple carcinomas represent two or more primary carcinoma that occur sumultaneously in the same patient. In order to fulfill the condition that tumors are synchronous, each tumor must be primary and not a metastasis of another tumor. The occurrence of renal carcinoma synchronously with colonic carcinoma is not so common. On the other hand, the pathohistological image in rare cases shows a mixed glandular and neuroendocrine component described in earlier works. In this paper, we present a patient who made a colonoscopy, a biopsy from a tumor change in the cecum due to malady, fainting, loss of appetite, and a positive test for faecal occult bleeding, and confirmed that it is an adenocarcinoma of the cecum. Multi slise computerized tomography of the abdomen also described a tumor change in the uretero-pelocalrix system of the left kidney region. The patient had no urinary tract disorders. The diagnosis of the synchronous tumor of the cecum and left kidney was set. A right hemicolectomy with latero-lateral ileo-transverse anastomosis, as well as left nephroureterectomy, was performed. What is particularly interesting in this case is that the pathohistological picture of the cecum carcinoma shows a rare form of tumor tone, mixed adeno-neuroendocrine carcinoma. In patients with diagnosed colorectal cancer, routine as well as additional preoperative diagnostic procedures should be performed to exclude the existence of kidney cancer, since, when synchronous with colorectal carcinoma occurs, renal carcinoma is mainly asymptomatic. In rare cases, the pathohistological picture may also show the neuroendocrine component of the tumor, which directs further therapy to the other direction.

Keywords: *synchronic carcinomas, cecum carcinoma, renal carcinoma, MANEC tumors.*

INTRODUCTION

Synchronous multiple cancers represent two or more primary cancers that occur simultaneously in the same patient. To fulfill the requirement that the tumors are synchronous, each tumor must be primary, not the tumor metastasis (1).The incidence of primary malignancies in the kidneys and colon is difficult to determine. The term "synchronous" means identity, but some authors even extend the time interval to detect another malignancy of up to 90 days (2). Mixed exocrine-neuroendocrinal tumors are rarely detected. According to the recent classification of the World Health Organization (VHO), neoplasms with exocrine and neuroendocrine components are called "mixed adenoneuroendocrine carcinomas" (MANECs) (3). Some authors say that MANEC is a neoplasm with dual adenocarcinoma and neuroendocrine differentiation, with each component representing at least 30% of the tumor (4). Also, this is a very rare tumor, and most are presented as a case report. In English literature, only seven cases in cecum and about 35 cases in the stomach were reported (5).

In this paper, we present the case of a patient with a synchronous renal and colonic cancer with MANEC's pathohistological characteristics.

CASE REPORT

The male patient, aged 77, had problems in the form of fatigue, fainting, loss of appetite. Blood tests indicated anemia, and analysis of the chair on faecal occult bleeding was positive. A colonoscopy was performed, whereby the tumor change in the length of several centimeters was described on the step-ascendent part of the column, which involves the whole circumference of the column and narrows its lumen. A biopsy was taken and the finding confirmed that it was an adenocarcinoma of the cecum. A multi-slice computerized tomography of the abdomen was developed, which, in addition to the already proven carcinoma of the cecum (Figure 1), also describes a tumor change in the uretero-pelocalrix system of the left kidney (Figure 2).

Figure 1. CT image carcinoma of the cecum

Figure 2. CT image of left kidney cancer

A decision was made on the operative treatment of both tumors during the same operation ((Figures 3 and 4), and a right hemicolectomy with latero-lateral ileo-transverso anastomosis, as well as left nephroureterectomy, was performed.

Figure 3. Left kidney

Figure 4. Right colon

The post-operative course was carried out neatly, and the patient was discharged home 10 days after surgery.

A definitive histopathological finding revealed the following:

- Reserved portion of the colon with pericolic fatty tissue, in the length of 300 mm, the diameter of the lumen 12 and 25 mm. Upon opening at 75 mm from the distal edge of the resection, there is an ulceroinfiltration change in the length of 50 mm, which involves 2/3 circuits and obstructs 1/3 lumen. On the intersection of the tumor changes the infiltrise wall to the bottom of the serous. In the rest of the mucous membranes, the morphology is common. The length of the neck is 50 mm, the diameter from 6 to 11 mm, at the intersection of wall thickness up to 4 mm. In the pericolic fat tissue, 9 lymph nodes have been found, between 2 and 9 mm diameter. Mixed adenocarcinoma and neuroendocrine carcinoma (MANEC) cecum, collision mode of combination.Adenocarcinoma invasivum coeci, high grade, pT3N0Mx.NET coeci, G2-intermedijal gradus, pT3N0Mx. (Figure 5,6)

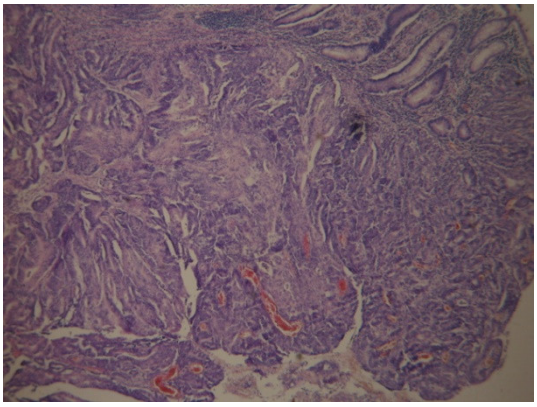

Figure 5. Colon carcinoma HEx100

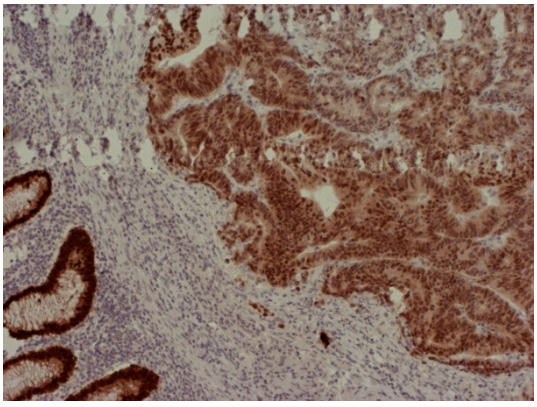

Figure 6. Colon carcinoma IHH LSABx2oo CDX2

- Kidney with perirenal fat tissue, total weight 780 g, diameter 91x67x26, with ureter length 100 mm, diameter from 6 to 9 mm, easily removable capsules. The surface is a lobular appearance, coarse-grained, yellow-brown color, with irregular leafy recesses, on the intersection of easily expanded renal sinus and kidney pelvis. There is a dual ureter, a hypoplastic appearance, a second ureter with a 30 mm long spatial enlargement that is filled with tumor mass, whitish colors, soft consistency that completely obstructs. Carcinoma papillare transitiocellular, histological grade I, nuclear grade II. Tumor infiltrate muscular layer, without elements of invasion of vascular structures. Pathological stage: pT2NxMx. (fig.7-10)

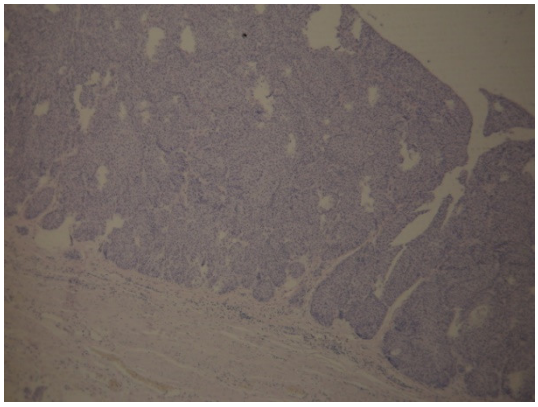

Figure 7. Ureter carcinoma HEx100

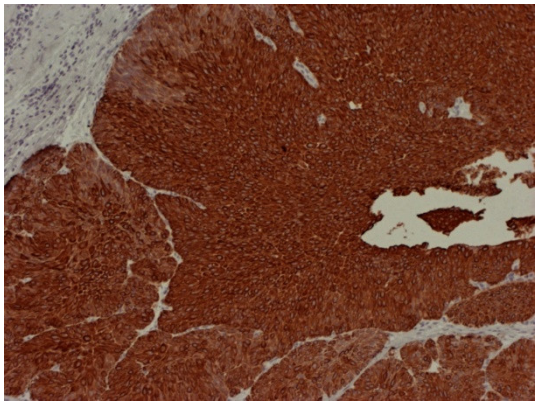

Figure 8. Ureter carcinoma IHH LSABx200 CK19

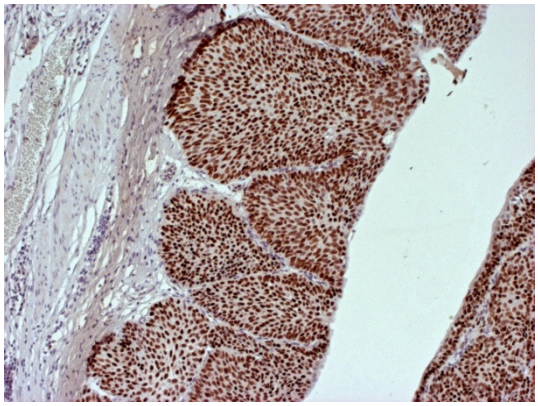

Figure 9. Ureter carcinoma IHH LSABx200 p63

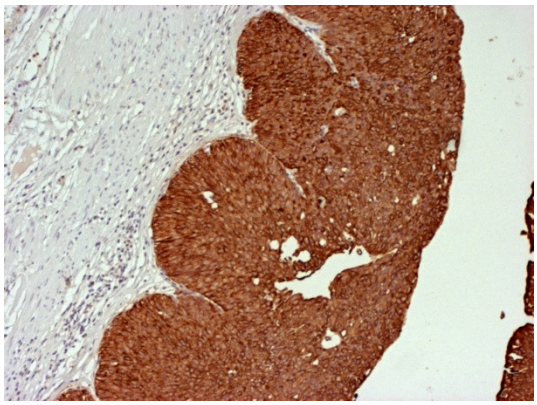

Figure 10. Ureter carcinoma
IHH LSABx200 CK7

DISCUSSION

Multiple primary carcinomas are present in about 16% of all diagnostic carcinoma (6). In relation to this percentage, most patients have two forms of the arm, but there are also patients with three or more carcinoma. The incidence of synchronous colon and kidney tumors is 0.1%. Synchronous asymptomatic carcinoma of cardiovascular diseases are found in 0.03-0.5% of patients with colorectal carcinoma (7). Not many studies have been done so far on this topic. One of these studies describes six cases of synchronous bowel and renal carcinoma between 1200 cancer patients with the current six-year period presenting a frequency of 0.5% (8). A synchronous tumor is defined as a tumor that has been reported at the same time or up to six months (although some authors define this period for 90 days) from the first tumors, if more than six months have passed since the onset of the first tumor, then tumors are called metacrons. In our patient, both tumors were diagnosed at the same time, so synchronous tumor criteria were released (9). It is known that carcinoma of the kidney can occur simultaneously with other primary carcinoma, and gastrointestinal carcinoma is most commonly carcinoma that has been reported synchronously with renal carcinoma (10).

In general, taking into account the synchronous primary carcinoma, usually occurs with the gastrointestinal and urogenital tract carcinoma. In our institution, this is the first description of the case of a synchronous tumor of the colon and kidneys. They are present in the patient, mostly over 74 years, and the main males are male. Our patient is male, aged 77 years. It is interesting to note that patients with urological cancer diagnoses have a higher risk of developing the following colorectal cancer than patients without cancer of urological diseases. Similarly, patients with colorectal cancer increased the risk of urologic cancer, especially in urethral carcinoma (11). The discovery of Renaissance cancer was purely accidental with a CT scan for setting up a tumor of the colon. As with other series of synchronous colon and renal carcinoma, the RCC was symptomatic, and the finding was an incident (12). A number of published works in the literature now describe only synchronic resections and colon on the same sides of the stomach.

When talking about surgical treatment as the initial and leading therapy of these diseases, the simultaneous resection of both malignancies was done in a single surgical session. The usual approach is open laparotomy, more convenient for the surgeons involved. However, some authors have shown that simultaneous laparoscopic resection of both malignancies is feasible with very low morbidity and zero mortality. In the literature, only three cases of synchronous laparoscopic resection of colorectal and renal cell carcinoma (13-15) were found.

In addition to the fact that there is a rare occurrence of synchronic cancer of the colon and kidneys, this case is especially interesting because of the pathohistological picture of the caecum carcinoma.

Exocrine-neuroendocrinal tumors of the gastrointestinal tract were first published in 1924 (16). Neoplasms are now referred to as "mixed adenoneuroendocrine carcinomas" (MANECs) according to the latest classification of the VHO classification of neoplasms of the gastrointestinal tract (17). These two components of the tumor can be in a different relationship and their treatment depends on the component that has prevailed in their relationship. Manecs containing a well-differentiated neuroendocrine tumor component and an adenocarcinoma component should be treated as adenocarcinoma. MANECs containing poorly differentiated neuroendocrine carcinoma (NEC) should be treated as NEC (18). For patients with MANEC lesions containing a higher proportion of the adenocarcinoma component, they could be expected to have a better prognosis than patients with a lower relationship. Chemotherapy protocols are not yet clearly defined because of the small number of patients with MANEC. Therefore, there is no one best mode of chemotherapy for patients with MANEC. The therapy is reduced to a case-by-case basis. New studies are necessary in terms of predicting the outcome of tumors with such pathohistological images.

CONCLUSION

In patients with diagnosed colorectal cancer, routine as well as additional preoperative diagnostic procedures should be performed to exclude the existence of kidney cancer, since, when synchronous, carcinoma of the kidney is mainly asymptomatic. On the other hand, people with urinary tract malignancies have a greater chance of malignancies of the gastrointestinal tract. The pathohistological image is of key importance first in determining the mixed forms of neoplasia, but also determining which component is more dominant, which in many ways is characterized by a clinical picture, a method of treatment, and in the outline and outcome of the disease.

ETHICS APPROVAL AND CONSENT TO PARTICIPATE

The study was conducted in accordance with the ethical standards of the committee responsible for human experimentation (institutional and national) and the Helsinki Declaration of 1975, as revised in 2013. Voluntary written and informed consent was obtained prior to enrollment in the study.

COMPETING INTERESTS

There are no conflicts of interest.

FUNDING

None.

REFERENCES

1. Ueno M, Muto T, Oya M, Ota H, Azekura K, Yamaguchi T. Multiple primary cancer: an experience at the Cancer Institute Hospital with special reference to colorectal cancer. Int J Clin Oncol. 2003;8:162-167.
2. Beisland C, Talleraas O, Bakke A, Norstein J, Multiple primary malignancies in patients with renal cell carcinoma: a national population-based cohort study, BJU Int, 2006, 97(4):698-702.
3. Rindi G, Arnold R, Bosman FT. Nomenclature and classification of neuroendocrine neoplasms of the digestive system. In: Bosman FT, Carneiro F, Hruban RH, Theise ND, et al., editors. WHO classification of tumors of the digestive system. Lyon: IARC Press; 2010:13-4.
4. Kitajima T, Kaida S, Lee S, Haruta S, Shinohara H, Ueno M, Suyama K, Oota Y, Fujii T, Udagawa H. Mixed adeno(neuro)endocrine carcinoma arising from the ectopic gastric mucosa of the upper thoracic esophagus. World J Surg Oncol. 2013;11:218.
5. Warren S, Gates DC. Multiple primary malignant tumors: a survey of the literature and statistical study. Am J Cancer. 1932;16.
6. Travis L.B., Rabkin C.S., Brown L.M. Cancer survivorship - genetic susceptibility and second primary cancers: research strategies and recommendations. Journal of the National Cancer Institute. 2006;98(1):15-25.
7. Capra F, Scintu F, Zorcolo L, Marongiu L, Casula G, Synchronous colorectal and renal carcinomas. Is it a definite clinical entity?, Chir Ital, 2003, 55(6):903-906.
8. O'BOYLE KP, KEMENY N, Synchronous colon and renal cancers: six cases of a clinical entity, Am J Med, 1989, 87(6):691-693.
9. Sarkar S, Kundu AK, Chakrabarti S. Lungs : Victim of Synchronous Double Malignancies. J Assoc Physicians India. 2007;55:235-7.
10. Sato S, Shinohara N, Suzuki S, Harabayashi T, Koyanagi T. Multiple primary malignancies in Japanese patients with renal cell carcinoma. Int J Urol 2004;11(5):269-75.
11. Calderwood AH, Huo D, Rubin DT. Association between colorectal cancer and urologic cancers. Arch Intern Med. 2008;168:1003-9.
12. HALAK M, HAZZAN D, KOVACS Z, SHILONI E, Synchronous colorectal and renal carcinomas: a noteworthy clinical entity. Report of five cases, Dis Colon Rectum, 2000, 43(9):1314-1315.
13. Kim SH, Park JY, Joh YG, Kim HH. Simultaneous laparoscopic radical nephrectomy and laparoscopic sigmoidectomy for synchronous renal cell carcinoma and colonic adenocarcinoma. Journal of Laparoendoscopic and Advanced Surgical Techniques. 2004;14(3):179-181.
14. Napolitano C, Santoro GA, Valvano L, Salvati V, Martorano M. Simultaneous totally laparoscopic radical nephrectomy and laparoscopic left hemicolectomy for synchronous renal and sigmoid colon carcinoma: report of a case. International Journal of Colorectal Disease. 2006;21(1):92-93.
15. Kim Sh, Park Jy, Joh Yg, Hoe He, Simultaneous laparoscopic radical nephrectomy and laparoscopic sigmoidectomy for renal cell carcinoma and colonic adenocarcinoma, J Laparoendosc Adv Surg Tech A. 2004. 14(3):179-181.
16. La Rosa S, Marando A, Sessa F, Capella C. Mixed adenoneuroendocrine carcinomas (MANECs) of the gastrointestinal tract: an update. Cancers (Basel) 2012;4:11-30.
17. Rindi G, Arnold R, Bosman FT. Nomenclature and classification of neuroendocrine neoplasms of the digestive system. In: Bosman FT, Carneiro F, Hruban RH, Theise ND, et al., editors. WHO classification of tumors of the digestive system. Lyon: IARC Press; 2010:13-4.
18. Hervieu V, Scoazec JY. Mixed endocrine tumors. Ann Pathol 2005; 25:511-28.