Carotid Artery Segmentation Using Convolutional Neural Network in Ultrasound Images

Radovanović, Nikola; Dašić, Lazar; Blagojević, Anđela; Šušteršič, Tijana; and Filipović, Nenad

Abstract: ***Cardiovascular disease (CVD) is one of the leading causes of death in urban areas. Carotid artery segmentation is the initial step in the automated diagnosis of carotid artery disease. The segmentation of carotid wall and lumen region boundaries are used as an essential part in assessing plaque morphology. In this paper, two types of Convolutional Neural Network (CNN) architectures are used for segmentation: U-Net and SegNet. The models used in this paper are applied on 257 ultrasound images containing a transverse section of the vessel acquired by ultrasound. Ultrasound imaging is noninvasive, completely unharming for the patient and a low-cost imaging method, but the main challenge when working with this kind of images is a very low signal to noise ratio and the process of imaging is highly dependent on the device operator. Different models are tested for various ranges of hyperparameter values and compared using different metrics. The model presented in this paper achieved over 94% Dice Coefficient for wall and lumen segmentation when trained during 100 epochs.***

Index Terms: ***carotid artery, convolutional neural network, SegNet, segmentation, U-Net***

1. INTRODUCTION

CAROTID artery disease (CVD) occurs under the influence of atherosclerotic narrowing, which usually forms most rapidly in the neck where the carotid artery is branching [1]. CVD is manifested by the formation of zones of lipid deposits, accumulated macrophages filled with lipids in the wall of the blood vessel. The deposition process continues and plaque forms. Narrowing of the arteries is usually caused by the accumulation of plaque, which consists of cholesterol, calcium, fibrous tissue and other cellular elements that keep forming at the microscopic sites of the lesion in the artery wall. In its early stages, carotid artery disease often shows no signs or symptoms. This condition can go unnoticed for a long time until the degree of stenosis and/or the shape of the plaque is such as to prevent blood flow to the brain, causing a stroke. Stroke is the third leading cause of death and disability in the world and 80% to 85% of strokes are ischemic strokes caused by stenosis [2]. A very important step in the prevention of this disease is understanding and constant monitoring of the changes in the geometry of the common carotid artery. Ultrasound examination is a non-invasive routine examination used to diagnose atherosclerosis. The manual examination consists of carotid artery ultrasound imaging and interpretation of acquired images by an expert.

Various systems have been created which can automatically segment the carotid artery in ultrasound images in a very efficient way, assess plaque morphology and single out a region of importance for diagnosis [3, 4, 5, 6]. These methods involve segmentation of the lumen and wall regions, which in combination give a segmented carotid artery.

Deformable models are shapes or curves on an image that can reshape or move under the influence of the information gathered from the image. These models found various applications in digital image processing such as edge detection, shape modeling and segmentation [7]. Mao et al. [8] developed a model for carotid artery segmentation in two-dimensional ultrasound images taken in B-mode based on a deformable model. The authors used one point for initialization of the deformable model, and

This paper is supported by the project that has received funding from the European Union's Horizon 2020 research and innovation programme under grant agreement No 755320 (TAXINOMISIS project). This article reflects only the author's view. The Commission is not responsible for any use that may be made of the information it contains. This research is also funded by Serbian Ministry of Education, Science, and Technological Development [451-03-9/2021-14/200107 (Faculty of Engineering, University of Kragujevac)]. Fourth author also acknowledges the support from L'OREAL-UNESCO awards "For Women in Science" in Serbia.

N. Radovanović, A. Blagojević, T. Šušteršič and N. Filipović is with the Faculty of Engineering, University of Kragujevac and Bioengineering Research and Development Center (BioIRC), Kragujevac, Serbia (e-mail: nradovanovic@kg.ac.rs, andjela.blagojevic@kg.ac.rs, tijanas@kg.ac.rs, fica@kg.ac.rs).

L. Dašić is with Bioengineering Research and Development Center (BioIRC), Kragujevac, Serbia (e-mail: ldasis345@gmail.com)

then based on mathematical morphologic operations generated the initial contour. The model was trained to fit the contour to the wall and lumen contour based on the geometric properties of the contour and gradient of the grey intensities calculated inside and outside of the current contour. Abolmaesumi et al. [9] presented their model for real-time segmentation of the carotid artery on the sequence of images acquired by ultrasound. They used the A* algorithm modified by temporal Kalman filter for tracking the center of the carotid artery through time, and spatial Kalman filter for contour estimation. Various methods have been also developed for the three-dimensional ultrasound image segmentation based on a geometrically deformable model [10, 11].

Machine learning and deep learning methods are state of the art for digital image segmentation. Xie et al. [12] used U-Net convolutional neural network for carotid artery lumen segmentation in the ultrasound images containing the longitudinal section of the carotid artery and achieved 91.9-96.6% accuracy depending on the carotid artery region that was segmented. Jiang et al. [13] used a modified U-Net architecture for carotid artery segmentation in the ultrasound images containing the transverse section of the artery. The authors used 3 different U-Net models along with SAN neural network for averaging the segmentation results given by three models and achieved a 70% Dice coefficient. Our goal is to improve the results achieved by current methods by extensive neural network architecture modifications along with preprocessing and postprocessing methods.

In this work, we present and compare the results achieved by convolutional neural network models based on U-Net and SegNet architecture for segmentation of lumen and wall regions of the carotid artery in two-dimensional greyscale ultrasound images.

2. *Materials and Methods*

The methodology consists of data preprocessing, model creation, and validation of created methods.

A. Preprocessing the Data

The dataset consists of original images acquired by an ultrasound exam and labels made by experts for the lumen and wall regions separately. The data was collected during the TAXINOMISIS project [14] by the University of Belgrade, Faculty of medicine, from 108 patients. The images in the dataset contain different segments of the artery in both the transverse and longitudinal sections. Every image in the dataset is anonymized for the data protection and security of the patients.

Ultrasound examination is well established as a completely safe, non-invasive method for atherosclerosis diagnosis, but there are many issues when working with this kind of images in digital image processing [15]. Ultrasound image acquisition is completely operator dependant and inadequate settings of the device can lead to poor image quality and wrong interpretation. Ultrasound images are usually degraded by multiplicative noise resulting in low image quality. These images can contain a lot of shadows which can obscure the regions of interest and have poor contrast that makes it even harder to extract important data [16].

Firstly, we manually separated only the images containing the transverse section leaving a total of 257 images for both lumen and wall segmentation. Since the examination was done in B-mode and Color mode simultaneously and the images contained some unusable data for segmentation like frequency and the gain of the ultrasound device, we had to crop only the greyscale ultrasound image and resize the images to the 256x256 resolution to be forwarded as input to the model. An example of the original image is shown in Figure 1.

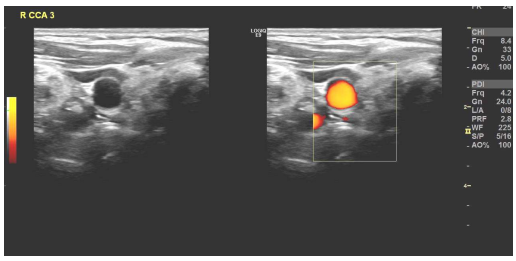

Figure 1: Original image.

Segmentation information delivered by the experts were obtained in the textual form of the spatial coordinates of the polygon that represents the lumen or wall region contour. For segmentation masks creation these polygons are loaded over the original image and resized along with it. Input image, expert contour, and generated mask are shown in Figure 2. For SegNet two masks are generated, one for marking the carotid artery and one for marking the background.

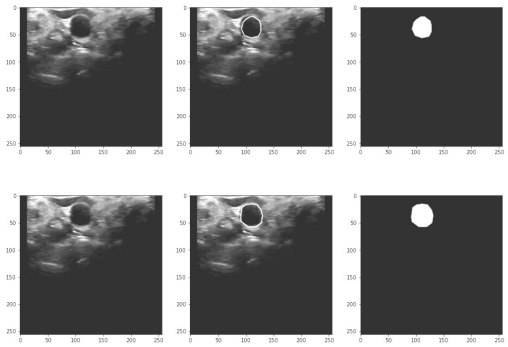

Figure 2: Examples of a) an original image, b) lumen (upper) and wall (lower) contours marked by an expert and c) generated masks.

Some images in the dataset have a very poor contrast that makes it very hard for an expert and an automatic segmentation tool to extract a region of interest (ROI). To reduce the effect of this problem and to improve the training quality of the model, a contrast improvement technique is implemented. We used CLAHE (Contrast Limited Adaptive Histogram Equalization) [17]. CLAHE is based on Adaptive Histogram Equalization that works by calculating multiple histograms for different regions of the image and then modifying them by stretching out the intensity distribution thus improving the contrast of every local region of the image. The main problem with this method is that the noise in the homogenous area of the image will be amplified which is always present in the ultrasound images. CLAHE method diminishes this problem by limiting the contrast gain to some predefined value. In Figure 3 the contrast improvement on the original image from the dataset is clearly visible when CLAHE method with 8x8 sized grid and clip limit 2 is used.

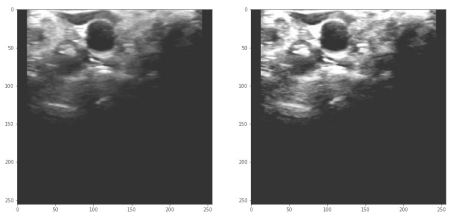

Figure 3: Contrast improvement using CLAHE method

B. U-Net Model

Two different models for wall and lumen regions are created. The architecture was based on [18], but it was modified in terms of finding the optimal hyperparameters. The modifications of the original architecture resulted in adding three additional blocks in the encoder and decoder part of the network. Additional block in the encoder part of the network consists of two convolutional layers with 3x3 kernels with a max-pooling layer with a 2x2 kernel following them. After each convolutional layer in the block, the ReLU activation function is applied. The additional blocks in the decoder part correspond to the blocks in the encoder part but with a deconvolutional layer for upsampling instead of max-pooling layer. These blocks are added at the start of the encoder part in the original architecture, that is after the last layer in the decoder part. In the original architecture, the convolutional layers in the first block have 64 kernels, doubling in every next block up to 1024 in the base of the network. The additional blocks have 8, 16 and 32 kernels. In addition, Dropout with probability 0.1 after every block in the encoder part is applied, and with 0.2 probability after every block in the decoder part to reduce overfitting of the model. The resulting architecture after modifications is shown in Figure 4.

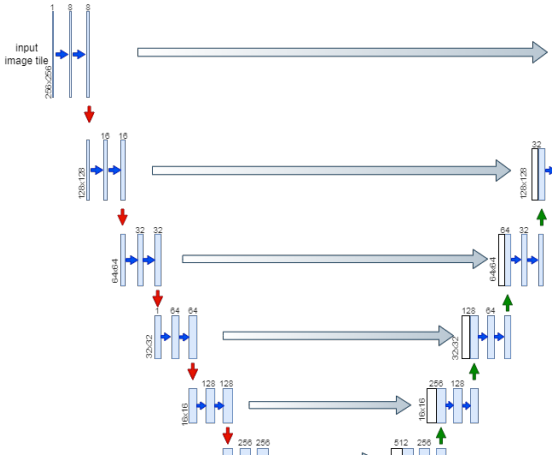

Figure 4: U-Net based architecture used for segmentation

C. SegNet model

Initially, the model was constructed based on [19]. This model was very prone to overfitting in the segmentation of both the lumen and outer wall regions and the training process was very time-consuming. We started by simplifying the architecture since the model already had batch normalization layers, so inserting the additional dropout layers made no difference. Simplification of the architecture resulted in removing convolutional layers from each block. Each block of the encoder part has one convolutional layer followed by ReLU activation function. After that, one batch normalization layer and one max-pooling layer that stores the indices of the maximal elements are added. Blocks of the decoder part of the network have a similar structure with unpooling layers instead of max-pooling layers that use the indices calculated in the max-pooling layer of the corresponding block in the encoder part. One block was also removed from both encoder and decoder parts of the

network resulting in an architecture shown in Figure 5.

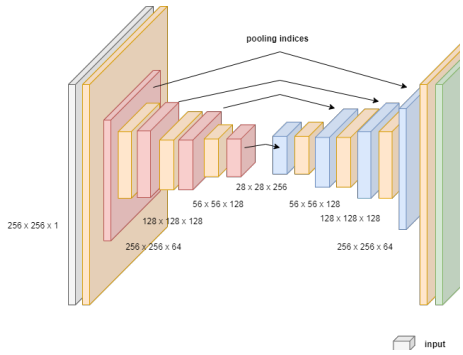

Figure 5: SegNet based architecture

D. *Post-processing*

We applied a post-processing procedure to reduce some of the false-positive pixels given by SegNet segmentation. The outputs of the SegNet model initially contained a lot of noise and disconnected components. The erosion and dilation operations were applied to the outputs. Firstly, erosion operation with a 3x3 sized kernel is applied to remove noisy parts and disconnected components except the one that is the wall or lumen region of the vessel. Because erosion reduced the area of the segmented wall and lumen region, dilation with 5x5 sized kernels is applied to expand the segmented area. We found that this technique significantly increased segmentation accuracy.

3. *Results and Discussion*

Both models for wall segmentation and lumen segmentation with U-Net architecture were trained for 100 epochs and for 150 epochs for models with SegNet architecture. The batch size was 8 for both architectures and the Adam method for stochastic optimization was used. The training was done using Tensorflow and ran on Intel i3-9100F quad-core CPU.

The models were trained on 231 images and tested on the remaining 26 images. Binary cross entropy metric was used to evaluate the U-Net models during training, and categorical cross-entropy for SegNet models. Binary cross-entropy loss values during training for each epoch when U-Net is trained for lumen and wall segmentation are displayed in Figure 6 and Figure 7 respectively.

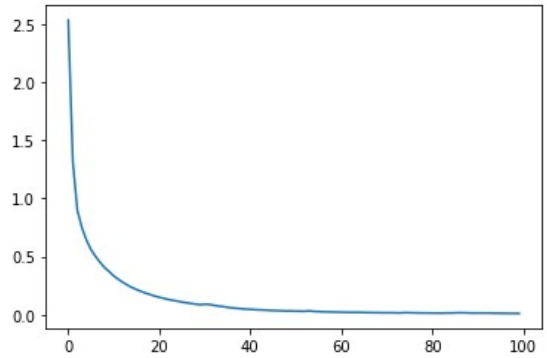

Figure 6: Loss function during training of U-Net model (lumen segmentation)

Loss function has two spikes (around epochs 40 and 80) when the U-Net model was trained for wall segmentation. This can happen due to batches containing unlucky data for optimization, e.g., contours with a deformed shape or a very small contour on the image.

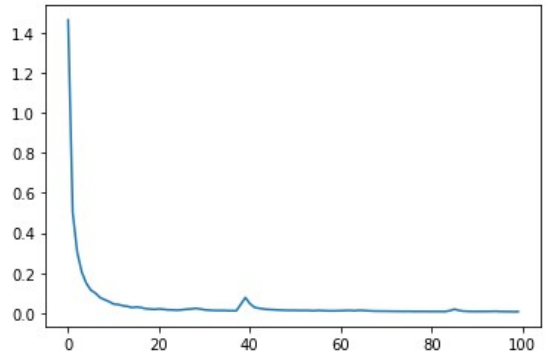

Figure 7: Loss function during training of U-Net model (wall segmentation)

Categorical cross-entropy loss values during training for each epoch when U-Net is trained for lumen and wall segmentation are presented in Figure 8 and Figure 9 respectively.

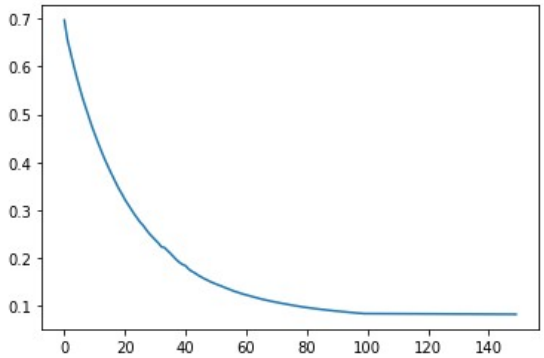

Figure 8: Loss function during training of SegNet model (lumen segmentation)

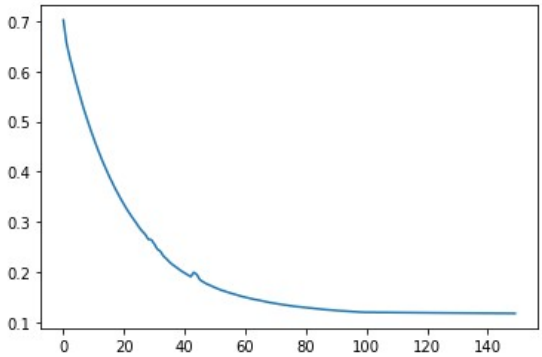

Figure 9: Loss function during training of SegNet model (wall segmentation)

Post-processing of the results improved segmentation given by the SegNet model by a significant margin i.e. from 62% Dice to 81% for wall segmentation and from 59% to 79% for lumen segmentation. Improvements after post-processing are visible in Figure 10.

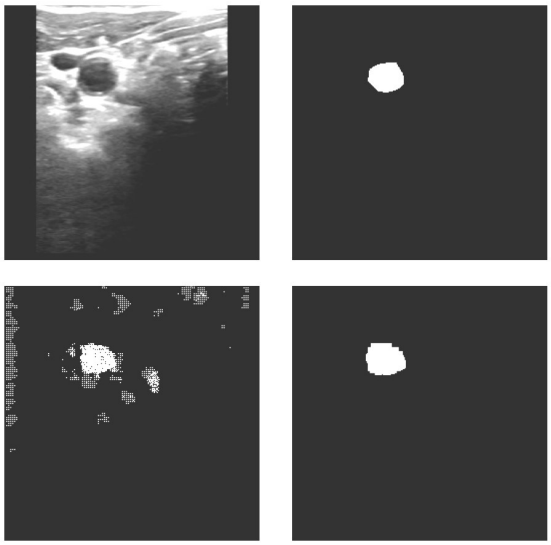

Figure 10: Input image (top-left), manual segmentation (top-right), SegNet output (bottom-left), Output after post processing (bottom-right).

Testing results of the models on the 26 images that were not presented during training for both wall and lumen segmentation are shown in Table 1. SegNet results are calculated after post-processing of the outputs given by models. The models are evaluated using Dice similarity coefficient and IoU (Intersection over Union) metrics.

Table 1: Dice coefficient and IoU values for U-Net and SegNet models

	U-Net		SegNet	
	Dice	IoU	Dice	IoU
Wall	94.91%	84.72%	81.23%	74.12%
Lumen	94.22%	77.90%	79.11%	70.08%

U-Net based model performs significantly better without any post-processing for both wall and lumen segmentation. The example of segmentation done by U-Net model is shown in Figure 11.

Figure 11: Unet segmentation example (original image, lumen mask and U-Net model output),

Segmentation outputs for wall and lumen regions can be overlapped to extract the important area which can be used for plaque assessment (Figure 12).

Figure 12: Carotid artery extraction.

4. CONCLUSIONS

The main purpose of this work was to create an automatic segmentation system for both lumen and wall regions of the carotid artery from two-dimensional ultrasound images with transverse sections. Segmented wall and lumen regions are then overlapped, thus extracting the region of interest which usually takes up to 5% of the original image area. The extracted region can be used by an expert or another automated system for plaque assessment to detect the signs of CVD early on and prevent catastrophic events for the patient.

Future work will be focused on creating an automatic plaque segmentation system from the extracted carotid artery.

REFERENCES

[1] Ratchford, E. V., & Evans, N. S., “Carotid artery disease”, Vascular medicine London, England, pp. 512–515, 2014.

[2] Prasad, K. “Pathophysiology and Medical Treatment of Carotid Artery Stenosis”, The International journal of

angiology: official publication of the International College of Angiology, Inc, pp. 158–172, 2015.

[3] Loizou, C., Pattichis, C., “Snakes based segmentation of the common carotid artery intima media”, Med. Biol. Eng. Comput., vol. 45, pp. 35-49, 2007.

[4] Rezaei, Z., Selamat, A., “Automatic plaque segmentation based on hybrid fuzzy clustering and k nearest neighborhood using virtual histology intravascular ultrasound images”, Applied Soft Computing, vol. 53, no. 39, pp. 380-395, 2017.

[5] Y. Li, “Segmentation of Medical Ultrasound Images Using Convolutional Neural Networks with Noisy Activating Functions”, Stanford Edu, 2016.

[6] Loizou, C., “A review of ultrasound common carotid artery image and video segmentation techniques,” Medical and Biological Engineering and Computing, 2014

[7] Chenyang Xu, Xiao Han, Jerry L. Prince, “Gradient Vector Flow Deformable Models”, Editor(s): ISAAC N. BANKMAN, Handbook of Medical Image Processing and Analysis (Second Edition), Academic Press, pp. 181-194, 2009.

[8] Mao, F., Gill, J., Downey, D. and Fenster, A., “Segmentation of carotid artery in ultrasound images: Method development and evaluation technique”, Med. Phys., pp. 1961-1970, 2020.

[9] Abolmaesumi, P., Sirouspour, M. R., Salcudean, S. E., "Real-time extraction of carotid artery contours from ultrasound images", Proceedings 13th IEEE Symposium on Computer-Based Medical Systems. pp. 181-186, 2000.

[10] Zahalka, A., Fenster, A., “An automated segmentation method for three-dimensional carotid ultrasound images”, Physics in medicine and biology, pp. 1321–1342, 2001.

[11] Li, X., Wang, Z., Lu, H., Liang, Z., "Automated segmentation method for the 3D ultrasound carotid image based on geometrically deformable model with automatic merge function", Proc. SPIE 4684, Medical Imaging 2002: Image Processing, 2002.

[12] Xie, M., Li, Y., Xue, Y., Shafritz, R., Rahimi, S. A., Ady, J. W., & Roshan, U. W., “Vessel lumen segmentation in internal carotid artery ultrasounds with deep convolutional neural networks”, 2019 IEEE International Conference on Bioinformatics and Biomedicine, BIBM, pp. 2393-2398, 2019.

[13] Jiang, M., Spence, J. D., Chiu, B., "Segmentation of 3D ultrasound carotid vessel wall using U-Net and segmentation average network", 2020 42nd Annual International Conference of the IEEE Engineering in Medicine & Biology Society (EMBC), pp. 2043-2046, 2020.

[14] TAXINOMISIS Project, Accessed: 22.12.2021., Available: https://taxinomisis-project.eu/

[15] Suri, J. S., “Advances in diagnostic and therapeutic ultrasound imaging”, Artech House, 2008

[16] Hashimoto, Beverly E. “Pitfalls in Carotid Ultrasound Diagnosis”, Ultrasound Clinics, pp. 463–476, 2011.

[17] Manju, R.A., Koshy, G., Simon, P., “Improved Method for Enhancing Dark Images based on CLAHE and Morphological Reconstruction”, Procedia Computer Science, vol. 165, pp. 391-398, 2019.

[18] Ronneberger, O., Fischer, P., Brox, T., “U-Net: Convolutional Networks for Biomedical Image Segmentation”, In: Navab N., Hornegger J., Wells W., Frangi A. (eds) Medical Image Computing and Computer-Assisted Intervention – MICCAI 2015. MICCAI 2015. Lecture Notes in Computer Science, vol 9351. Springer, Cham, 2015.

[19] Badrinarayanan, V., Kendall, A., Cipolla, R., “SegNet: A Deep Convolutional Encoder-Decoder Architecture for Image Segmentation,” in IEEE Transactions on Pattern Analysis and Machine Intelligence, vol. 39, no. 12, pp. 2481-2495, 2017.