

WELLS' SCORE IN DIAGNOSIS OF PULMONARY EMBOLISM IN PATIENT WITH THROMBOCYTOPENIA: A CASE REPORT

Dragan Panic¹, Andreja Todorović¹, Milica Stanojević² and Violeta Irić Čupić³

¹Department of Cardiology, General Hospital Čuprija, Čuprija, Serbia

²High Medical School of Professional Studies, Čuprija, Serbia

³Department of Internal medicine, Faculty of Medical Sciences, University of Kragujevac, Clinical Center Kragujevac, Serbia

VELSOV SKOR U DIJAGNOSTICI PLUĆNE EMBOLIJE KOD PACIJENTA SA TROMBOCITOPENIJOM: PRIKAZ SLUČAJA

Dragan Panić¹, Andreja Todorović¹, Milica Stanojević² i Violeta Irić Čupić³

¹Odeljenje kardiologije, Opšta bolnica Čuprija, Čuprija, Srbija

²High Medical School of Professional Studies, Čuprija, Srbija

³Katedra za internu medicinu, Fakultet medicinskih nauka, Univerzitet u Kragujevcu, Klinički centar Kragujevac, Srbija

Received / Priljubljen: 08. 08. 2017.

Accepted / Prihvaćen: 30. 10. 2017.

ABSTRACT

Current diagnostic workup of patients with suspected acute pulmonary embolism (PE) usually starts with the assessment of clinical pretest probability, using clinical prediction rules and plasma D-dimer measurement. Although an accurate diagnosis of acute pulmonary embolism (PE) in patients is thus of crucial importance, the diagnostic management of suspected PE is still challenging.

A 60-year-old man with chest pain and expectoration of blood was admitted to the Department of Cardiology, General Hospital in Čuprija, Serbia. After physical examination and laboratory analyses, the diagnosis of Right side pleuropneumonia and acute pulmonary embolism was established. Clinically, patient was hemodynamically stable, auscultative slightly weaker respiratory sound right basal, without pretibial edema. Laboratory: C-reactive protein (CRP) 132.9 mg/L, Leukocytes (Le) 18.9x10⁹/L, Erythrocytes (Er) 3.23x10¹²/L, Haemoglobin (Hgb) 113 g/L, Platelets (Plt) 79x10⁹/L, D-dimer 35.2. On the third day after admission, D-dimer was increased and platelet count was decreased (Plt up to 62x10⁹/L). According to Wells' rules, score was 2.5 (without symptoms on admission), a normal clinical finding with clinical manifestation of hemoptysis and chest pain, which represents the intermediate level of clinical probability of PE. After the recidive of PE, Wells' score was 6.5. In summary, this study suggests that Wells' score, based on a patient's risk for pulmonary embolism, is a valuable guidance for decision-making in combination with knowledge and experience of clinicians. Clinicians should use validated clinical prediction rules to estimate pretest probability in patients in whom acute PE is being considered.

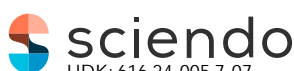Keywords: *pulmonary embolism, thrombocytopenia, Wells' score, antiphospholipid syndrome*

SAŽETAK

Aktuelni dijagnostički pristup kod pacijenata sa sumnjom na akutnu plućnu emboliju (PE) obično počinje sa procenom kliničke pretest verovatnoće korišćenjem kliničkih prediktivnih skorova i određivanjem D-dimera u plazmi. Iako je precizna dijagnoza akutne plućne embolije kod pacijenata od velikog značaja, dijagnoza suspektne PE je i dalje veliki izazov.

Pacijent muškog pola, 60 godina star, je primljen na Odeljenje kardiologije Opšte bolnice u Čupriji, Srbija, zbog bola u grudima i iskašljavanja krvi. Nakon fizikalnog pregleda i urađenih laboratorijskih analiza, postavljena je dijagnoza pleuropneumonije sa desne strane i sumnja na plućna emboliju. Klinički, pacijent je bio hemodinamski stabilan, auskultatorno neznatno slabiji respiratorni šum desno, bazalno, bez pretibijalnih edema. Laboratorija: C-reaktivni protein (CRP) 132.9 mg/L, leukociti (Le) 18.9x10⁹ /L, eritrociti (Er) 3.23x10¹²/L, hemoglobin (Hgb) 113 g/L, trombociti (Tro) 79x10⁹/L, D-dimer 35.2. Trećeg dana nakon prijema, dolazi do porasta D-dimera i pada broja trombocita na 62x10⁹/L. Korišćenjem Velsovog skora kliničke verovatnoće dobijen je rezultat 2,5 (bez simptoma na prijemu) uz normalan klinički nalaz i jedine kliničke manifestacije (hemoptizije i bol u grudima), što predstavlja srednji stepen kliničke verovatnoće za PE. Posle recidiva PE, Velsov skor je porastao na 6,5. Ukratko, ova studija ukazuje na to da je korišćenje Velsovog skora za procenu rizika od plućne embolije predstavlja dragocen dijagnostički vodič, u kombinaciji sa znanjem i iskustvom kliničara. Kliničari treba da koriste proverene prediktivne kliničke skorove za procenu kliničke pretest verovatnoće, kod pacijenata kod kojih se razmatra akutna PE.

Ključne reči: *plućna embolija, trombocitopenija, Velsov skor, antifosfolipidni sindrom.*



UDK: 616.24-005.7-07
616.155.2-06

Ser J Exp Clin Res 2019; 20 (3): 281-285

DOI: 10.1515/SJECR-2017-0061

Corresponding author:

Panic Dragan, MD;
General Hospital Čuprija,
Miodraga Novakovića Str. 78, 35230 Čuprija, Serbia
E-mail: panicdr1@gmail.com



INTRODUCTION

European Guidelines for the diagnosis and treatment of pulmonary embolism (PE) estimated annual incidence rate of venous thrombosis and pulmonary embolism at about 0.5 to 1.0 per 1000 inhabitants.^{1,2} Diagnosis of PE is not easy and autopsy studies have already confirmed that fact. Percentage of correct diagnosis during the lifetime is approximately 30% (10-65%).³ Untreated PE is associated with a high mortality rate ranging up to 30%, while the mortality in diagnosed and treated PE is 8%. About 10% of patients with PE die of sudden death.² Pulmonary embolism is a potentially lethal complication in surgery patients and the proximal deep venous thrombosis was complicated by pulmonary embolism in approximately one-third of cases, often without clinical manifestations.^{4,5}

Current diagnostic workup of patients with suspected acute pulmonary embolism (PE) usually starts with the assessment of clinical pretest probability, using clinical prediction rules and plasma D-dimer measurement. Indeed, recent studies have demonstrated the safety of rejecting the diagnosis of PE by the combination of a low clinical probability and a normal quantitative D-dimer test result, thereby decreasing the need for further radiologic diagnostic imaging in up to 30% of patients. On the third day of hospitalization the patient we are talking about had symptoms of sudden anxiety and heart palpitations.

Although an accurate diagnosis of acute pulmonary embolism (PE) in patients is thus of crucial importance, the diagnostic management of suspected PE is still challenging.

CASE PRESENTATION

A 60-year-old man with chest pain and expectoration of blood was admitted to the Department of Cardiology, General Hospital in Cuprija, Serbia. Problems had begun the day before the admission when he started coughing blood content and had a long-lasting pain in the right shoulder blade. His medical history reveals that 10 days before that he had Aorto-Bi-Iliac bypass as a surgical intervention for abdominal aortic aneurysm. After that, patient was discharged from vascular surgery with symptoms and signs of urinary infection and he was prescribed a macrolide antibiotic therapy.

After physical examination and laboratory analyses, the diagnosis of *Right side pleuropneumonia* and *pulmonary embolism* was established. Clinically, patient was hemodynamically stable, auscultative slightly weaker respiratory sound right basal, without pretibial edema. Laboratory findings were the following: C-reactive protein (CRP) 132.9 mg/L (normal (N) 0-3), Leukocytes (Le) $18.9 \times 10^9/L$ (N 4,1-10,9 G/L), Erythrocytes (Er) $3.23 \times 10^{12}/L$ (N 4.2-6.3 T/L) Haemoglobin (Hgb) 113 g/L (N 120-180 g/L), Platelets (Plt) $79 \times 10^9/L$ (N 140-440 G/L), D-dimer 35.2 (N < 0,5 mg/L FEU), 2 plus protein in urine, 30-35 Le in urine, bacteriuria (the following devices were used to obtain laboratory parameters: the hematology analyzer *CELLDYN 1800 Abbot*; for biochemical analysis *DIMENSION RXL MAX Siemens* and for obtaining D-dimer *SISMEX 1500 Siemens*). Electrocardiography record: sinus rhythm: frequency 70 beats per minute, present left deviation of heart (Figure 1A). Radiographic findings: the right costophrenic angle bronchopneumonic shading in lungs. Echocardiographic findings: dimensions of cardiac chambers in reference values (Figure 2). Bacteriological examination of sputum: *Streptococcus pneumoniae*. Therapy: the third generation cephalosporin, half a dose of low molecular weight heparin (LMWH)-enoxaparin.

On the third day of hospitalization the patient had symptoms of sudden anxiety and heart palpitations (Figure 1B) with normal blood pressure and a heart rate of 110/min, respiration rate of 20/min and oxygen saturation (Sa O₂) of 92%. Urgent echocardiography showed signs of acute increased load of the right ventricle (RV dilated with TR 2-3 + SPDK to 57 mm Hg). MSCT pulmonary angiography confirmed thrombosis of distal part of the right pulmonary artery and the segmental branch of the right pulmonary artery with subsequent infarct Right side Pleuropneumonia. D-dimer was increased and platelet count was decreased (Plt up to $62 \times 10^9/L$). Oral and parenteral anticoagulants were included and in the next few days patient's status was slowly stabilizing with the normalization of platelet counts (170 and $300 \times 10^9/L$).

On the sixth day of first admission, only discreetly larger circumference of the left lower leg, without painful sensitivity, was registered. A Color Doppler Ultrasound imaging device was used to evaluate partially passable femoralis vein filled with thrombus masses. Additional microbiological analy-

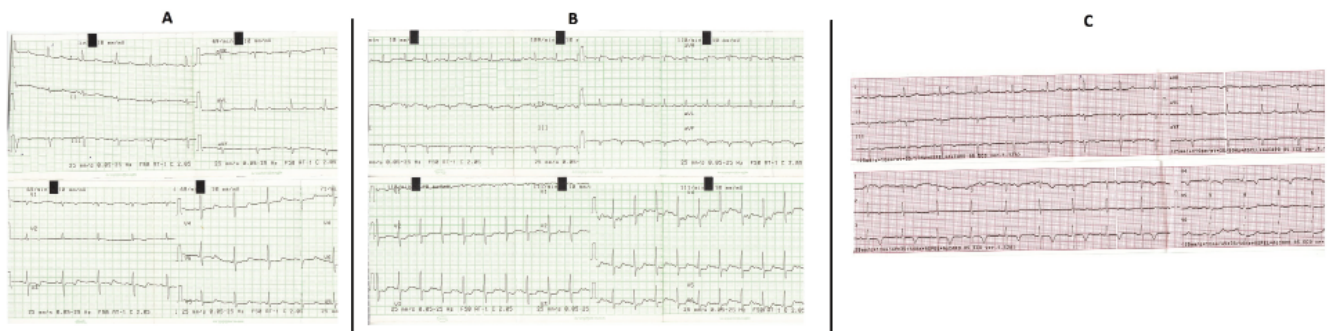


Figure 1. An electrocardiogram (ECG) records the electrical activity of the heart at admission (A), during the worsening of disease and hospitalization (B) and at discharge (C).

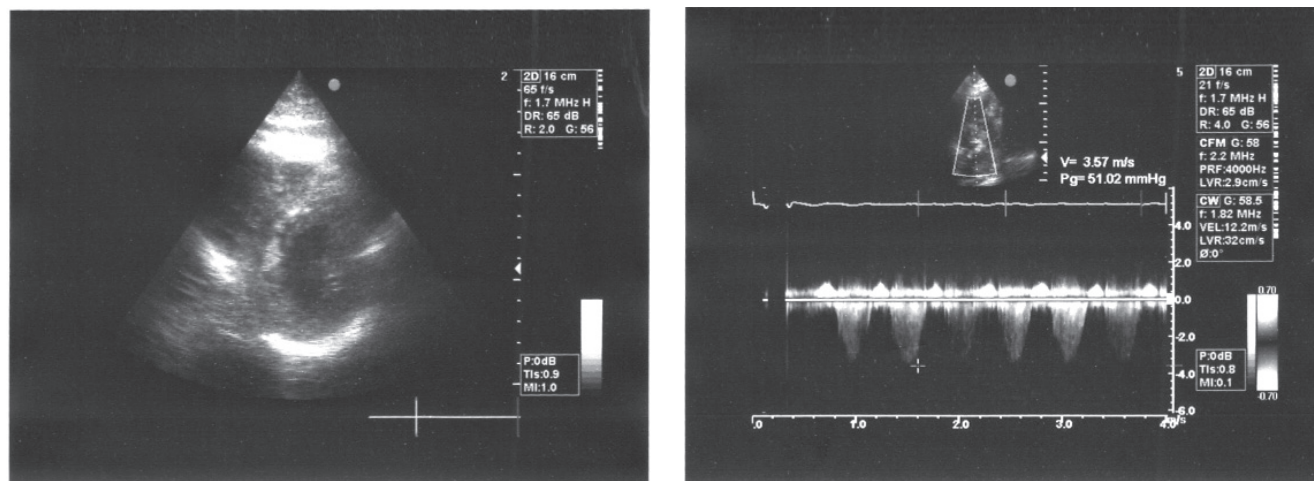


Figure 2. Echocardiographic findings in PE: normal left ventricle and enlarged right ventricle, elevated RVSP (right ventricular systolic pressure).

ses were done: sputum-culture - *Streptococcus pneumoniae*, urine culture - negative finding, hemoculture - negative finding, stool culture - *Clostridium difficile toxin A/B*-positive finding. At the same time, this patient was diagnosed with acute *Enterocolitis* with diarrhea, the existing anemia (Hgb 92 g/l) and hypoproteinemia (albumin 20.5 g/L, N 34-50 g/l). The infectologist who set that diagnosis suggested intensive therapy: rehydration, albumin solution, metronidazole (parenteral) and vancomycin (*per os*) administration. After the laboratory tests, Antiphospholipid syndrome (APS) was established as a definitive diagnosis. The patient recovered and on the seventeenth day of hospitalization (Figure 1C), he was dismissed from the department with a recommendation to do consultative hematologist examination.

DISCUSSION

Diagnosis of PE is a major challenge for clinicians because the spectrum of clinical symptoms can range from dramatic clinical picture followed by cardiogenic shock and sudden cardiac death to absent, minor and clinically non-specific symptoms that can mimic many other diseases. Concomitant diseases and dominant clinical presentation of the underlying disease may mask symptoms of PE. The clinical form of the disease is conditioned by numerous factors such as the size of affected blood vessels in the lungs, the presence of arterial spasm, the size and distribution of thrombus, the nature of occlusion, the previous cardiopulmonary status, the application of therapy, and others. For the rapid orientation and triage of patients with suspected PE, there are several scores of clinical probability of PE. Most often used are Wells' and Geneva score, but Wells' score has the priority in suspected PE cases as well as in elderly high risk patients.^{6,7,8,9} These score systems are based on scoring the presence of certain clinical parameters and, on the basis of the total score, assign the patient to the category with the corresponding degree of probability for PE. Since the PE disease is a highly variable clinical course,

the emergence of new clinical symptoms and the signs that these score systems show are necessary because the overall score can be significantly changed over a short period of time. At first glance our case seems simple, but it hides diagnostic and therapeutic dilemmas. No symptoms on admission, a normal clinical finding with clinical manifestation of hemoptysis and chest pain were present the day before admission. If these symptoms apply to Wells' original score of the clinical probability of PE (hemoptysis, 1 point + recent surgery, 1.5 points), we get 2.5 points. This means that diagnosis of pulmonary embolism is unlikely (grading on two levels) or there is an intermediate level of clinical probability of PE (grading in three levels) (Table 1). The same level of clinical probability we get if we apply the original revised Geneva score (hemoptysis, 2 points + major surgery in the past month, 2 points). Thirty-day mortality rate estimated over PESI score was 1.7-3.5% (Class II).^{6,7} The normal clinical findings on admission and good general condition of the patient did not speak in favor of a pulmonary embolism, or the emergence of new clinical symptoms. But signs of the situation had changed drastically in less than 48 hours. Wells' score rose by 6.5 points (heart rate > 100, 1.5 points, an alternative diagnosis is less likely, 3 points) and the revised Geneva score increased by 5 points (heart rate > 95), which made the diagnosis of pulmonary embolism more likely in both cases. At the same time the thirty-day mortality by PESI soon grew to double the value (Table 1).

Those normal clinical findings on admission must not be misleading for doctors because pulmonary embolism is often an asymptomatic disease. This fact was indicated in a review of 28 trials with 5233 patients with deep venous thrombosis where asymptomatic pulmonary embolism occurred in 1665 patients (32%).¹⁰ The majority of patients with PE is normotensive on admission and almost a third of them are without clinical symptoms. However, it is in this group of patients that most of the early deaths occur due to the sudden deterioration during hospital treatment.¹¹ In our case, the patient was hemodynamically stable on admission, which is in accordance with the fact that microembolites obstructing



Table 1. Well's score on admission and after repeated PE episode

Variable	Points	Points
Clinical signs and symptoms of DVT (minimum of leg swelling and pain with palpation of the deep veins)	0	0
An alternative diagnosis is less likely than PE	0	0
Heart rate greater than 100	1.5	1.5
Immobilisation or surgery in the previous four weeks	0	1.5
Previous DVT/PE	0	3
Hemoptysis	1	1
Malignancy (on treatment, treated in the last 6 months or palliative)	0	0
Clinical probability for PE <i>Low</i> <i>Intermediate</i> <i>High</i>	(Score is 2.5) <2 total 2–6 total >6 total	(Score is 6.5) <2 total 2–6 total >6 total

DVT, deep vein thrombosis; PE, pulmonary embolism.

pulmonary circulation are most often clinically silent or give unspecified symptomatology. However, massive thrombus, suddenly released, usually from the venous system of the lower extremities, can obstruct the large pulmonary artery branch and lead to pulmonary hypertension with acute right ventricle load, followed by dramatic clinical symptomatology. Due to ventricular blindness, there is hypoxia with subsequent tachycardia, and reflex hyperventilation initially causes formation of hypocapnia. Associated bronchopulmonary constriction leads to the occurrence of pulmonary hypertension, resulting in desiccation of the right ventricle with compressed left ventricular filling and manifest clinical symptomatology. Nonspecific symptoms and signs should be carefully considered: confusion, unexplained fever, wheezing, transient shortness of breath, pleural effusions, infiltrates in the lungs, coughing, resistant cardiac arrhythmias, cardiovascular collapse, syncope, and hemoptysis.

Chest pain in PE is present in almost every second patient (52%), while incidence of hemoptysis is considerably lower, ranging 7%-11% (mostly related to pulmonary infarction).^{1,2,7} The guide of the European Association of Cardiologists diagnostic algorithm for patients without shock and hypotension with low and medium level of clinical probability for PE, implies that after positive D-dimer, CT angiography is necessary, and in case of positive finding the PE should be treated.⁷ In our case due to highly positive inflammatory syndrome at the reception, the absence of clinical signs of DVT, left heart deviation on the ECG and normal echocardiographic findings, we did not do CT angiography at the reception. Particularly disturbing were the clinical facts such as a major surgical intervention two weeks earlier and the findings of thrombocytopenia on admission ($79 \times 10^9/L$), which in the case of massive thromboembolism further complicated the narrowed range of therapeutic options.¹² Thrombolytic therapy would not be taken into account in this case since, due to the recent surgery, its application was absolutely contraindicated. According to ESC, recommendations for the treatment of pulmonary embolism in case of a contraindication for thrombolytic therapy or the failure

of thrombolytic therapy are surgical embolectomy (Class I, level of evidence C) as well as percutaneous treatment with a guidance catheter (class IIa, level of evidence C) that are limited in our conditions.⁷

Thrombocytopenia is not the state that favors thrombosis and its findings required careful analysis. Numerous cases of pulmonary embolism and thrombocytopenia were recorded in literature. In the study of 225 patients with PE, in the group of patients with thrombocytopenia on admission, thirty-day mortality was 38.7% and in the group without thrombocytopenia was 15.95%. The predictive value of thrombocytopenia for the thirty day mortality had a sensitivity of 78.4%, a specificity of 49%.¹³

Mild thrombocytopenia is a common cause of venous thromboembolism, but pronounced thrombocytopenia may be the cause of diagnostic confusion especially when it occurs during the treatment with heparin. In our case thrombocytopenia on admission was new symptom since it was not present during the previous surgery. It could be a reflection of septic conditions, iatrogenic in connection with the previous hospitalization, but also due to consumption caused by extensive thrombosis, as well as of many other, less likely, complex reasons. The possibility of pseudothrombocytopenia was discarded since no platelet aggregates were detected under the microscope and a low platelet count was also obtained by determining the number of platelets using citrate as an anticoagulant. Because of thrombocytopenia, as well as the fact that the clinical finding on admission was unlikely to PE, we decided to use a half of the therapeutic dose of low molecular weight heparin. But on the third day, when we had clear signs of PE and the lowest level of platelets ($62 \times 10^9/L$), we used full therapeutic dose of enoxaparin that led to the stabilization and normalization of the patient's platelet count (up to $300 \times 10^9/L$). According to ESC recommendations for the treatment of pulmonary embolism in patients with no shock and hypotension (no high risk patients), as our patient was, the therapeutic approach during the acute phase involves the use of parenteral anticoagulant therapy-LMWH or fondaparinux (class I, level of evidence A) with parallel



administration of oral anticoagulant therapy (class I, level of evidence B). However, thrombolytic therapy should also be considered in patients with moderately high risk with clinical signs of haemodynamic instability (class IIa, level of evidence B).⁷ Since LMWH and fondaparinux significantly less induce large haemorrhage, most patients do not require laboratory monitoring in relation to unfractionated heparin and carry significantly less potential to induce heparin-induced thrombocytopenia, in addition to non-heparin anticoagulants (lepirudin, danaparoid, bivalirudin, argatroban), where fondaparinux is preferred because there is only a small number of reported cases of heparin-induced thrombocytopenia.^{14,15} Since the European Guidelines for the diagnosis and treatment of pulmonary embolism do not provide guidelines for therapeutic approach for patients who have, in addition to pulmonary embolism, initial thrombocytopenia, individual approach and careful evaluation of each patient is needed. Decrease in platelet count during treatment with heparin was not a result of heparin-induced thrombocytopenia as has already been described in the literature. In earlier literature, four patients with PE were described, where in average in the first 18 hours after initiation of therapy with heparin, a decrease in the number of platelets was shown and continuation of therapy with heparin that had already started had an excellent final hemodynamic result and normalization of platelet counts due to inhibition of platelet consumption.¹⁶

Our case is complicated by severe diarrhea accompanied by dehydration, hypoalbuminemia and anemia that required prolonged hospitalization and patient immobilization because there was the increased risk of new thromboembolic events and not rarely relapsed diarrhea induced by *Clostridium difficile*. The risk of re-infection within eight weeks is 10-20%.¹⁷ The final closure is certainly a definitive diagnosis of antiphospholipid syndrome where thrombocytopenia is the most common hematologic event.

CONCLUSION

In summary, this study suggests that the Wells' score based on a patient's risk for pulmonary embolism is valuable guidance for decision-making in combination with knowledge and experience of clinicians. Clinicians should use validated clinical prediction rules to estimate pretest probability in patients in whom acute PE is being considered.

REFERENCES

1. Torbicki A, Perrier A, Konstantidines S et al. Guidelines on the diagnosis and management of acute pulmonary embolism. *Eur Heart J*. 2008; 29: 2276–315.
2. Bělohávek J, Dytrych V, Linhart A. Pulmonary embolism, part I: Epidemiology, risk factors and risk stratification, pathophysiology, clinical presentation, diagnosis and nonthrombotic pulmonary embolism. *Exp Clin Cardiol*. 2013; 18(2): 129–138.
3. Bricola SA, Paiva EF, Lichtenstein A et al. Fatal pulmonary embolism in hospitalized patients: a large autopsy-based matched case-control study. *CLINICS* 2013; 68(5): 679-685.
4. Konstantinides SV. Trends in Pulmonary Embolism Outcomes. Are We Really Making Progress? (Editorial Comment). *JACC* 2016. 67 (2) 171-2.
5. Heit JA. Predicting the risk of venous thromboembolism recurrence. *Am J Hematol* 2012; 87 (S1): S63–S67.
6. Ferrer M, Morillo R, Elías T et al. Validation of two clinical prognostic models in patients with acute symptomatic pulmonary embolism. *Arch Bronconeumol* 2013; 49(10): 427–431.
7. Konstantinides SV, Torbicki A, Agnelli G et al. 2014 ESC Guidelines on the diagnosis and management of acute pulmonary embolism. *Eur Heart J* 2014; 35: 3033–3069.
8. Di Marca S. Comparison of Wells and Revised Geneva Rule to Assess Pretest Probability of Pulmonary Embolism in High-Risk Hospitalized Elderly Adults. *J Am Geriatr Soc*. 2015; 63(6): 1091-7.
9. Shen JH, Chen HL, Chen JR, Xing JL, Gu P, Zhu BF. Comparison of the Wells score with the revised Geneva score for assessing suspected pulmonary embolism: a systematic review and meta-analysis. *J Thromb Thrombolysis* 2016 Apr; 41(3):482-92.
10. Stein PD, Matta F, Musani MH, Diaczok B. Silent pulmonary embolism in patients with deep venous thrombosis: A systematic review. *American Journal of Medicine*. 2010; 123: 426-431.
11. Baglin T. What happens after venous thromboembolism? *Rewiew. J Thromb Haemost* 2009; (7)S1: 287-90.
12. Beckman MG, Hooper WC, Critchley SE, Ortel TL. Venous Thromboembolism A Public Health Concern. *Am J Prev Med* 2010; 38(4S): 495–501.
13. Hsiao JF, Chu CM, Chung CM, Chang ST, Kuo CT and Hsu JT. Prognostic significance of thrombocytopenia in acute pulmonary embolism. *J Intern Med Taiwan* 2008; (19)6: 499–507.
14. Bhatt VR1, Aryal MR, Shrestha R, Armitage JO. Fondaparinux-associated heparin-induced thrombocytopenia. *Eur J Haematol*. 2013; 91(5): 437-41.
15. Warkentin TE, Pai M, Sheppard JI, Schulman S, Spyropoulos AC, Eikelboom JW. Fondaparinux treatment of acute heparin-induced thrombocytopenia confirmed by the serotonin-release assay: a 30-month, 16-patient case series. *Thromb Haemost*. 2011; 9(12): 2389-96.
16. Kitchens CS. Thrombocytopenia due to acute venous thromboembolism and it's role in expanding the differential diagnosis of heparin-induced thrombocytopenia. *Am J Hematol*. 2004; 76(1): 69-73.
17. Kuijper EJ, Coignard BB, Teull PP. Emergence of *Clostridium difficile*-associated disease in North America and Europe. *Clin Microbiol Infect* 2006; 12(Suppl 6): 2–18.