

TREATMENT OF COMPLEX FEMORAL FRACTURES WITH THE LONG INTRAMEDULLARY GAMMA NAIL

Aleksandar Juskovic¹, Goran Pesic¹, Miroslav Kezunovic¹, Jovana Jeremic², Nikola Bulatovic¹ and Zarko Dasic¹

¹Orthopedic and Traumatology Clinic, Clinical Center Montenegro, Podgorica, Montenegro

²University of Kragujevac, Faculty of Medical Sciences, Department of Pharmacy, Kragujevac, Serbia

TRETMAN KOMPLEKSNIH PRELOMA BUTNE KOSTI DUGIM INTRAMEDULARNIM GAMA KLINOM

Aleksandar Jušković¹, Goran Pešić¹, Miroslav Kezunović¹, Jovana Jeremić², Nikola Bulatović¹ i Žarko Dašić¹

¹Orthopedic and Traumatology Clinic, Clinical Center Montenegro, Podgorica, Montenegro

²Univerzitet u Kragujevcu, Fakultet medicinskih nauka, Katedra za Farmaciju, Kragujevac, Srbija

Received / Priljen: 31. 08. 2017.

Accepted / Prihvaćen: 07. 09. 2017.

ABSTRACT

The purpose of the current study was to present the authors' experiences with the long intramedullary Gamma nail in the treatment of patients with complex femoral fractures. This retrospective study included 48 patients with complex femoral fractures. All patients had received fracture fixation treatments with long intramedullary Gamma nails from January 2007 to December 2015. The complex fractures of all patients were classified into 3 types, according to the anatomical locations of the fractures. Type I included combined fractures of the shaft and the proximal femur. Type II included segmental fractures. Type III included combined fractures of the shaft and distal femur. According to the Harris Hip Score, 85.4% of our patients had excellent and very good functional outcomes of the operative procedure. Complications occurred in 7 (14.58%) patients. The most common complications occurred in patients with combined fractures of the shaft and distal femur (50%). Based on the findings of this study, we conclude that the clinical and radiological results after the treatment of complex femoral fractures with the long intramedullary Gamma nail show good outcomes, with a high rate of bone union and minimal soft tissue damage. Experience with this procedure is important to prevent and minimise technical complications.

Keywords: long intramedullary Gamma nail; complex femoral fractures; Harris Hip Score

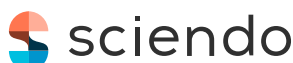SAŽETAK

Cilj ove studije bio je da predstavi iskustvo autora u lečenju kompleksnih preloma butne kosti dugim intramedularnim gama klinom. Ovo je retrospektivna studija koja obuhvata 48 pacijenata sa kompleksni prelomom butne kosti. Svi pacijenti su u periodu od januara 2007. do decembra 2015. godine lečeni metodom intramedularne fiksacije dugim Gama klinom. Kompleksni prelomi su prema anatomskoj lokalizaciji klasifikovani u tri tipa. Tip I obuhvata kombinovane prelome dijafize i proksimalnog dela femura. Tip II obuhvata segmentalne prelome. Tip III obuhvata kombinovane prelome dijafize i distalnog dela femura. 85,4% naših pacijenata imalo je odličan i vrlo dobar funkcionalni rezultat nakon operativne procedure, procenjen na osnovu Harris Hip Scor-a. Komplikacije su nastale kod 7 (14,58%) pacijenata. Najčešće komplikacije su primećene kod pacijenata sa kombinovanim prelomom dijafize i distalnog dela femura (50%). Na osnovu ove studije možemo zaključiti da nakon intramedularne fiksacije dugim Gama klinom klinički i radiološki rezultati imaju dobar ishod uz visok stepen srašćivanja kostiju i minimalno oštećenje mekog tkiva. Iskustvo je važno za sprečavanje i smanjenje tehničkih komplikacija.

Ključne reči: dugi intramedularni Gama klin; kompleksni prelomi butne kosti; Harris Hip Scor

ABBREVIATIONS

DHS-dynamic hip screw HHS-Harris Hip Score
DCP-dynamic compression plate LCP-locking compression plate



UDK: 616.718.4-001.5-089.23
Ser J Exp Clin Res 2019; 20 (4): 337-342
DOI: 10.2478/sjcr-2018-0038

Corresponding author:

Aleksandar Juskovic,
Orthopedic and Traumatology Clinic, Clinical Center Montenegro
Podgorica, Montenegro
E-mail: aleksandar.juskovic@gmail.com



INTRODUCTION

With aging populations and a prolonged average life expectancy, the incidence of femoral fractures has sharply increased and is expected to double in the next 25 years in industrialised countries (1). It is estimated that half of these fractures will be intertrochanteric, which have a high morbidity and mortality and seriously affect a patient's quality of life (1, 2).

Complex femoral fractures have been defined as unstable, combined fractures of the shaft and proximal or distal femur, as well as segmental fractures of the femur. These fractures are often difficult to treat and represent an important challenge in the field of traumatology (3). Complex femoral fractures occur more often in a younger population and are most commonly caused by high-energy trauma, either in traffic accidents or falls from heights (4). On the other hand, the most common cause of femoral fractures in older populations is a mild trauma (5). An early stabilisation of the fractured bone contributes to the preservation of blood supply and is essential for the healing process (6, 7). Surgical treatments are gradually becoming the first-choice treatments of complex femoral fractures. The primary goal of operative treatments for complex femoral fractures is to restore the anatomical alignment of the bony fragments, which allows early mobilisation of the patient and the limb (8). Although technologies and instruments have been continuously improved, fixation failure still poses a problem in the treatment of unstable femoral fractures. The operative treatment of complex fractures is very complicated because complex fractures are often associated with other serious injuries, and it is necessary to treat two or more levels of fractures with dislocation at the same time (9). The combination of two different fixation methods (such as dynamic hip screw (DHS) and dynamic compression plate (DCP), or condylar plate and DCP, or locking compression plate (LCP) and DHS) on the same femur is associated with numerous complications and poor functional results. Therefore, the use of a plate to achieve osteosynthesis of complex fractures necessitates a wide operative exposure and extensive stripping of soft tissue, which results in increased blood loss and a longer operating time. All of these techniques require a very long period of rest and an avoidance of support in the injured leg, which also leads to more frequent postoperative complications (10).

Considering previously mentioned facts, as well as long-term clinical experiences and follow-up observations, the use of an osteofixation system is necessary. The simultaneous repair of all fractures with an osteofixation system will improve the results of treatment of these complex injuries. Accordingly, the Gamma nail was developed in an attempt to overcome some of these problems. The Gamma nail, introduced in the late 1980s, combines intramedullary fixation in the shaft with a screw in the proximal fragment (8-12). In the 1990s, some authors were describing treatment with the Gamma nail as being equivalent to, or bet-

ter than, treatment with the dynamic hip screw (13, 14). In contrast, other authors have observed that the Gamma nail has a higher rate of serious complications, such as perioperative fractures of the femoral shaft (15, 16). However, since 1988, the Gamma nail has been modified several times. Modifications in the nail design and attention given to specific details during the nail insertion have significantly decreased the rate of perioperative complications. These decreases in complications have been observed in recent papers, which have described the use of a newer generation of the Gamma nail (8, 17). The Gamma nail comes in two types; the standard nail (20 cm) is mainly used for trochanteric fractures, while complex fractures are treated with the longer (32-42 cm) version (12). Theoretically, the re-designed Gamma nail should reduce the occurrence of complications, such as the removal and extension of the nail, over-compression of the fracture, and collapse (18).

The use of the long Gamma nail during treatment has provided good results, in terms of less invasiveness, better fixation and faster rehabilitation of patients with complex femoral fractures. However, despite the good and reliable results, some typical failures and complications may occur (19). In addition to the quality of the implant, the success of femoral fracture treatment depends on the quality of the bones, the age of the patient, the general health status of the patient, the time interval between the fracture and treatment, the treatment adequacy, the patient's comorbidity, and the stability of fixation. (20, 21).

The purpose of the current study was to present the authors' experience with the long intramedullary Gamma nail in the treatment of patients with complex femoral fractures, in order to assess the success and safety of the technique.

PATIENTS AND METHODS

This retrospective study included patients with complex femoral fractures who had received fracture fixation treatments with the long intramedullary Gamma nail (produced by Synthes Switzerland, Stryker SAD, LIMA Italy) from January 2007 to December 2015. Forty-eight patients were included, and all patients were recruited from the Orthopedics and Traumatology Clinics of the Clinical Center Montenegro in Podgorica. A retrospective review of clinical charts and preoperative, perioperative, postoperative, and final radiographs were performed. The resulting outcomes and complications were recorded, while rehabilitation was supervised by physiotherapists.

Inclusion criteria were patients with complex femoral fractures who were treated with the long intramedullary Gamma nail and who were older than 16 years of age. Exclusion criteria were as follows: pathologic fractures, previous chemotherapy and/or radiotherapy, rheumatic diseases, a previous operation in the same hip/femur, and a traumatic amputation through or above the knee.

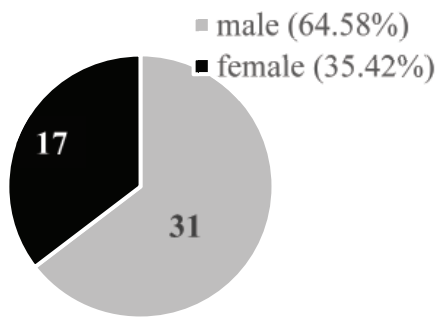


Figure 1. Gender distribution of the study population

The complex fractures of all patients were classified into 3 types, according to the anatomical locations of the fracture. Type I included combined fractures of the shaft and proximal femur. Type II included segmental fractures. Type III included combined fractures of the shaft and distal femur. To estimate the functional outcome of the operative procedure, we used the Harris Hip Score (HHS). This is a time-tested scoring system used for the evaluation of hip function, and is based on the best responses from the patient regarding different aspects of life. All patients were divided into 3 categories, based on the HHS: (1) excellent and very good HHS, (2) good HHS, and (3) poor HHS (22). Patients who were unable to come regularly were contacted via telephone, and the Harris Hip Score was evaluated and documented for analysis.

Bone healing was assessed both radiologically and clinically by using conventional X-ray studies, as well as by evaluating clinical symptoms, including pain associated with full weight-bearing. Healing was concluded with the formation of a bridging callus and the crossing of bone trabeculae on the fracture line in at least three out of four cortices, as well as the absence of pain with full weight-bearing (23).

The median duration of follow-up of all patients was 4.7 years (with a range of 30 months to 8.3 years).

RESULTS

Altogether, 48 patients, including 31 males and 17 females, were included in this retrospective study. The gender distribution of the study population is presented in **Figure 1**. The mean age was 42 years. The youngest patient was 17, while the oldest patient was 74 years old. As we mentioned before, the complex fractures of all patients were classified into 3 types (**Table 1**).

According to the Harris Hip Score, 41 patients were rated as excellent and very good, 4 patients were rated as good, and 3 patients were rated as poor (**Table 2**). Complications occurred in 7 (14.58%) patients with complex femoral fractures that were treated with the intramedullary long Gamma nail. In addition, one patient presented with both complications (infection and malunion). The overall

Table 1. Clinical characteristics of the study population

Classification of fracture	Number (percentage)
Type I	30 (62.5%)
Type II	12 (25%)
Type III	6 (12.5%)

Table 2. Functional outcome of the operative procedure

Harris Hip Score (HHS)	Excellent and very good	41 (85.4%)
	Good	4 (8.3%)
	Poor	3 (6.3%)
The presence of complications	Without complications	41 (85.42%)
	Infection	1 (2.08%)
	Non-union	2 (4.17%)
	Mal-union	2 (4.17%)
	Lag screw cut-out	2 (4.17%)
	Broken nail	1 (2.08%)

Table 3. Connection between the type of fracture and frequency of complications

Classification of fracture	Number of patients
Type I	2 (6.67%)
Type II	2 (16.67%)
Type III	3 (50%)

complications encountered in the perioperative and postoperative periods are listed in **Table 2**.

Two patients with type I fractures, two patients with type II fractures, and three patients with type III fractures had some of the previously mentioned complications. The connections between the type of fracture and the frequency of perioperative and/or postoperative complications are presented in **Table 3**.

DISCUSSION

The treatment and surgical stabilisation of complex femoral fractures is a challenge for orthopaedics. Both design and technical problems have been found in various osteofixation systems. Consequently, the ideal implant for complex femoral fractures remains a matter of discussion (24, 25). Older implants (Jewett nails, McLaughlin nails, Ender intramedullary nails) have been reported to have unacceptably high complication rates (26, 27). Alternatively, the use of modern implants, such as dynamic hip screws, Gamma nails, and Medoff sliding plates, can reduce the incidence of complications and the patient's recovery time (10, 17). Consequently, the aim of the current study was to present the authors' experiences with the long intramedullary Gamma nail in the treatment of patients with complex femoral fractures.



In this retrospective study, 85.4% of our patients had excellent and very good functional outcomes of the operative procedure, according to the HHS. On the other hand, only 6.3% of patients were rated as poor by the HHS (Table 2). Considering the severity of the fractures, these findings suggests that treatment with the long Gamma nail produces more than satisfactory functional results in our hospital.

In the 48 reported cases, complications occurred in 14.58% of patients treated with the long intramedullary Gamma nail. Data from the literature data suggest that infections are the most common complications of fractures and predominantly occur in open fractures (28). Only one (2.08%) of the 48 patients had a mild infection. This rate is lower than that usually reported for Gamma nailing procedures (28-31). Other frequent complications, such as nonunions (where the fractured bone fails to heal) or malunions (where the fractured bone heals in a deformed manner) were noted in our patients. A union was defined as a callus formation at the fracture site, with the fracture line visible for less than a quarter of the circumference. Nonunions were reported in two patients (4.17%), and malunions were also reported in two patients (4.17%). Nellaiyappan and coworkers reported 2 (10.52%) cases of nonunions in 19 patients with complex femoral fractures (9). The most common nail-related complication (cut-out of the lag screw, mainly because of poor positioning in an osteoporotic bone) was observed in two patients (4.17%). The literature showed cut-out frequencies up to 10% (29, 30). In addition, a broken nail occurred in only one patient. The broken nail was easily removed using the technique involving an olive-tripped guide wire (32). The frequency of complications in our study (Table 2) is in accordance with previous literature data (14, 28-31). Most importantly, almost all of the complications occurring after Gamma nail fixation can be prevented by following strict observance of the recommended surgical technique, careful preoperative planning, and rigid postoperative protocols. The choice of the appropriate length for the lag screw, its best position in the femoral neck, and its dynamic proximal locking will considerably reduce the incidence of screw cut-out (32, 9).

Alternative devices described for the treatment of these fractures showed higher complication rates than the long Gamma nail. A study conducted by Aktseles and coworkers suggested that the intramedullary Gamma nail is superior to a sliding hip screw in the treatment of multi-fragmentary intertrochanteric fractures (33).

Many studies have examined long Gamma nail efficacy in the treatment of different femoral fractures. In a paper by Sehat and coworkers, it was shown that the long Gamma nail is effective in the treatment of proximal femoral fractures (31). Zhang and coworkers concluded that the locking intramedullary Gamma nail is a simple and safe treatment for unstable intertrochanteric femoral fractures, with a satisfactory clinical efficacy (34, 35). However, in a comparative study of the Gamma nail versus the proximal femoral nail, Woo-Kie and coauthors demonstrated no differences in clinical outcomes for the treatment of reverse obliquity intertrochanteric fractures (36).

Finally, we examined the connection between the type of fracture and the frequency of complications, in order to complete the picture of the efficacy of the long intramedullary Gamma nail. The most common complications occur in patients with combined fractures of the shaft and distal femur (50%), while patients with segmental and with combined fractures of the shaft and proximal femur had a lower rate of complications (Table 3). In combined shaft and distal femur fractures, the indications for treating fractures with the long intramedullary Gamma nail should be carefully considered.

The present study had certain limitations. First, this study was retrospective, which is not the best method when compared to a prospective study. Second, this study included a small number of patients, due to the uncommon nature of this injury.

CONCLUSION

Complex femoral fractures are generally difficult to treat and provoke high complication rates. From the findings of this study, we can summarise that the clinical and radiological results after the treatment of complex femoral fractures with the long intramedullary Gamma nail show good outcomes, high rates of bone union, and minimal soft tissue damage. Experience with this procedure is important to prevent and minimise technical complications.

REFERENCES

1. Melton 3rd LJ, Gabriel SE, Crowson CS, et al. Cost-equivalence of different osteoporotic fractures. *Osteoporos Int.* 2003; 14: 383-8.
2. Rüedi TP, Murphy WM. *AO principles of fracture management.* Stuttgart: Thieme. 2000; 441-4.
3. Morris AH, Zuckerman JD, American Academy of Orthopaedic Surgeons Council of Health Policy and Practice. National Consensus Conference on Improving the Continuum of Care for Patients with Hip Fracture. *J Bone Joint Surg Am.* 2002; 84:670-4.
4. Davidovitch RI, Jordan CJ, Egol KA, et al. Challenges in the treatment of femoral neck fractures in the non-elderly adult. *J Trauma.* 2010; 68(1):236-42.
5. Abdel MP, Houdek MT, Watts CD, Lewallen DG, Berry DJ. Epidemiology of periprosthetic femoral fractures in 5417 revision total hip arthroplasties. *Bone Joint J.* 2016; 98(4):468-74.
6. Shane E, Burr D, Ebeling PR, et al. Atypical subtrochanteric and diaphyseal femoral fractures: report of a task force of the American society for bone and mineral research. *J Bone Miner Res.* 2010; 25:2267-94.
7. Bone LB, Johnson KD, Weigelt J, Scheinberg R. Early versus delayed stabilization of femoral fractures. A prospective randomized study. *J Bone Joint Surg Am.* 1989; 71:336-40.



8. Pervez H, Parker MJ. Results of the long Gamma nail for complex proximal femoral fractures. *Injury*. 2001; 32(9):704-7.
9. Nellaiyappan B, Ramesh Vyravan P, Mohankumar M, Doraikumar R. Complex Femoral Fractures - An Analysis. *Journal of Dental and Medical Sciences*. 2016; 15(3):10-5.
10. Aune AK, Ekeland A, Odegaard B, Groggaard B, Alho A. Gamma nail vs compression screw for trochanteric femoral fractures: 15 reoperations in a prospective, randomized study of 378 patients. *Acta Orthopaedica Scandinavica*, 1994; 65(2):127-30.
11. Halder SC. The Gamma nail for peritrochanteric fractures. *Bone & Joint Journal*. 1992; 74(3):340-4.
12. van Doorn R, Stapert JW. The long gamma nail in the treatment of 329 subtrochanteric fractures with major extension into the femoral shaft. *European Journal of Surgery*. 2000; 166(3):240-6.
13. Leung KS, So WS, Shen WY, Hui PW. Gamma nails and dynamic hip screws from peritrochanteric fractures. A randomized prospective study in elderly patients. *J Bone Joint Surg*. 1992; 74-B-:345-51.
14. Bridle SH, Patel AD, Bircher M, Calvert PT. Fixation of intertrochanteric fractures of the femur. A randomised prospective comparison of the gamma nail and the dynamic hip screw. *Bone & Joint Journal*. 1991; 73(2):330-4.
15. Parker MJ, Pryor GA. Gamma versus DHS nailing for extracapsular femoral fractures. Meta-analysis of ten randomized trials, *Int Orthop*. 1996; 20:163-8.
16. Radford PJ, Needoff M, Webb JK. A prospective randomized comparison of the dynamic hip screw and the Gamma locking nail. *J Bone Joint Surg*. 1993; 75-B:789-93.
17. Bhandari M, Schemitsch E, Jönsson A, Zlowodzki M, Haidukewych, GJ. Gamma nails revisited: gamma nails versus compression hip screws in the management of intertrochanteric fractures of the hip: a meta-analysis. *Journal of orthopaedic trauma*. 2009; 23(6):460-4.
18. Kempf I, Grosse A, Taglang G, Favreul E. Gamma nail in the treatment of closed trochanteric fractures. Results and indications of 121 cases. *Orthop Traumatol Surg Res*. 2014; 100(1):75-83.
19. Hesse B, Gächter A. Complications following the treatment of trochanteric fractures with the gamma nail. *Archives of orthopaedic and trauma surgery*. 2004; 124(10):692-8.
20. Gadegone WM, Salphale YS. Proximal femoral nail: an analysis of 100 cases of proximal femoral fractures with an average follow up of 1 year. *Int Orthop*. 2007; 31:403-8.
21. Strauss EJ, Kummer FJ, Koval KJ, Egol KA. The "Z-effect" phenomenon defined: a laboratory study. *J Orthop Res*. 2007; 25:1568-73.
22. Wamper KE, Sierevelt IN, Poolman RW, Bhandari M, Haverkamp D. The Harris hip score: Do ceiling effects limit its usefulness in orthopedics?: A systematic review. *Acta Orthopaedica*. 2010; 81(6):703-7.
23. Russell GV, Kregor PJ, Jarrett CA, Zlowodzki M. Complicated femoral shaft fractures. *Orthopedic Clinics*. 2002; 33(1):127-42.
24. Warwick DJ, Crichlow TPKR, Langkamer VG, Jackson M. The dynamic condylar screw in the management of subtrochanteric fracture of the femur. *Injury*. 1995; 26:241-4.
25. Siebenrock KA, Muller U, Ganz R. Indirect reduction with a condylar blade plate for osteosynthesis of subtrochanteric femoral fractures. *Injury*. 1998; 29(Suppl. 3):7-15.
26. Teitge RA. Subtrochanteric fracture of the femur. *J Bone Joint Surg*. 1976;58-A:282.
27. Pankovich AM, Trabishy IE. Ender nailing of intertrochanteric and sub trochantric fractures of the femur. *J Bone Joint Surg*. 1980;62-A:635-45.
28. Docquier PL, Manche E, Autrique JC, Geulette B. Complications associated with gamma nailing: a review of 439 cases. *Acta Orthopaedica Belgica*. 2002; 68(3):251-7.
29. Borens O, Wettstein M, Kombot C, Chevalley F, Mouhsine E, Garofalo R. Long gamma nail in the treatment of subtrochanteric fractures. *Arch Orthop Trauma Surg*. 2004; 124:443-7.
30. Ramakrishnan M, Prasad SS, Parkinson RW, Kaye JC. Management of subtrochanteric femoral fractures and metastases using long proximal femoral nail. *Injury*. 2004; 35:184-90.
31. Sehat K, Baker RP, Pattison G, Price R, Harries WJ, Chesser TJS. The use of the long gamma nail in proximal femoral fractures. *Injury*. 2005; 36(11):1350-4.
32. Middleton RG, McNab IS, Hashemi-Nejad A, Noordeen MH. Multiple guide wire technique for removal of a short distal fragment of a fractured intramedullary nail. *Injury* 1993; 24:357-8.
33. Aktselis I, Kokoroghiannis C, Fragkomichalos E, et al. Prospective randomised controlled trial of an intramedullary nail versus a sliding hip screw for intertrochanteric fractures of the femur. *Int Orthop*. 2014; 38(1):155-61.
34. Zhang L, Liu D, Wu ZD, He S, Huang ZY, Wang YJ. Biomechanical analysis of locking Gamma nail in treatment of unstable intertrochanteric fractures. *Orthop J China*. 2010; 18:1028-9.
35. Zhang L, Shen J, Chen S, et al. Treatment of unstable intertrochanteric femoral fractures with locking gamma nail (LGN): A retrospective cohort study. *International Journal of Surgery*. 2016; 26:12-17.
36. Min WK, Kim SY, Kim TK, et al. Proximal femoral nail for the treatment of reverse obliquity intertrochanteric fractures compared with gamma nail. *Journal of Trauma and Acute Care Surgery*. 2007; 63(5):1054-60.