

CASE REPORT / ПРИКАЗ БОЛЕСНИКА

Unusual anatomy of permanent maxillary and mandibular molars – case reports

Aleksandra Mišić, Suzana Živanović, Mirjana Radović, Miloš Papić, Milica Popović

University of Kragujevac, Faculty of Medical Sciences, Department of Dentistry, Kragujevac, Serbia

**SUMMARY**

Introduction The anatomy and morphology of the roots and root canal systems of multi-rooted teeth, especially the molars, shows numerous variations. Preoperative radiography, in particular cone-beam computed tomography (CBCT), has exceptional significance in detecting anatomical variations and unusual root canal morphologies, which are extremely important to be familiar with in order to undertake successful endodontic therapy and minimize procedural errors.

Outline of cases This report presents cases of incidental diagnosis of an unusual root anatomy and root canal morphology of permanent molars in two patients. Diagnosis in the first case was made using orthopantomography and confirmed after extraction therapy. The second case revealed unusual root anatomy and root canal morphology of the permanent molar after preoperative CBCT imaging.

Conclusion Anatomical and morphological variations of roots and root canal systems can occur in any tooth. Clinicians should expect these variations, which should be thoroughly investigated when considering dental treatment.

Keywords: single-rooted molars; unusual anatomy; dental radiography

INTRODUCTION

It is known that there are numerous variations in the root and root canal anatomy and morphology of multi-rooted teeth, especially molars [1]. Knowing possible anatomical and morphological variations is extremely important for successful endodontic therapy, but also for the extraction of such teeth [2]. Permanent maxillary molars are commonly described as a group of teeth with three roots, two buccal and one palatal, while permanent mandibular molars have usually two roots, mesial and distal [3, 4]. With regard to the number of root canals, in each of the three roots of the maxillary molar there is generally one canal, but it is common to have two canals in the bucco-mesial root when there are four canals in total [5]. Mandibular molars usually have three canals, two of which are located in the mesial root, but often two canals can also be found in the distal root [6, 7].

Anatomical and morphological variations and rare abnormalities of roots and root canal systems had been shown in previous studies [1, 2, 3]. The literature shows that maxillary molars can present from the simplest to the extensively complicated root and root canal anatomy and morphology [8–14]. Not much difference was found for mandibular molars [6, 15–19]. The key for successful endodontic therapy is in proper locating, chemo-mechanical cleansing and obturation of all canals, so in addition to knowing the complicated canal morphology, it is necessary to be familiar with the simple canal morphology in order to reduce the possibility of procedural errors.

Dental radiography is of the great importance for diagnosis, administration of therapy, and post-operative monitoring. Using preoperative radiography, it is possible to estimate the number and morphology of the roots and the root canal systems [13]. Introduction of cone-beam computed tomography (CBCT) facilitated the finding of anatomical and morphological variations in everyday dental practice [19].

Despite the numerous studies of the anatomy and morphology of maxillary and mandibular molars, there is a small number of those which describe the presence of single-rooted molars.

CASE REPORTS

Cases reported in this study were acquired after signing the written consent by the patients. The study was approved by the Ethics Committee of the Faculty of Medical Sciences, University of Kragujevac, Serbia (No: 01-15837), and was conducted in compliance with the Helsinki Declaration and Guidelines for Good Clinical Practice.

Patient 1

The 51-year-old female patient reported for a dental appointment at the Department of Dentistry, Faculty of Medical Sciences, University of Kragujevac, Serbia, due to prosthetic rehabilitation. The medical history of the patient was not significant for dental diagnosis and therapy.

During the clinical examination, it was noticed that the following teeth were missing: 15,

Received • Примљено:
March, 5, 2019

Revised • Ревизија:
April 1, 2019

Accepted • Прихваћено:
April 8, 2019

Online first: June 18, 2019

Correspondence to:

Milica POPOVIĆ
University of Kragujevac
Faculty of Medical Sciences
Department of Dentistry
Svetozara Markovića 69
Kragujevac 34000, Serbia
milicapopovic75@gmail.com

26, 36, 35, 46, and 47. The presence of a gangrenous root of tooth 17 was determined, as well as numerous caries lesions. Oral hygiene was inadequate. Preoperative orthopantomographic examination revealed that all the present teeth were single-rooted, including both maxillary and mandibular molars (Figure 1). The patient was referred for further dental care.

The terminal stage of periodontal disease was diagnosed for the following teeth: 16, 14, 11, 25, 27, 37, and 31. These teeth, as well as tooth 17, were indicated for extraction. After the extraction, the teeth were photographed, and it was confirmed that the extracted molars were single-rooted (Figure 2). Further conservative and prosthetic rehabilitation of the patient followed.

Patient 2

A 49-year-old female patient reported for prosthetic rehabilitation of the mandibular right segment. The patient denied any previous diseases regarding her medical history. The clinical examination revealed the absence of teeth 45, 46, and 47, numerous caries lesions, and inadequate oral hygiene. In order to consider possible implant rehabilitation, the patient was referred to the CBCT preoperative imaging.

The CBCT image revealed that the left maxillary first molar had unusual root and root canal anatomy: one root and one root canal at the transversal, sagittal, and axial cross-sections (Figure 3). The canal was ovally shaped in its entire length and had a larger bucco-lingual than a mesio-distal diameter.

Prior to implant rehabilitation, the patient was referred to further dental care, which included periodontal, restorative, endodontic, and surgical treatment.

DISCUSSION

Anatomical variations such as fusion, germination, or anomalies in the number of roots can often be diagnosed on the basis of preoperative dental radiography. Although the incidence of root variation is scarce, their presence should not be underestimated, especially if root variations are present in most of the teeth of one patient [20]. Morphological dental anomalies can be localized on a single tooth, on a group of teeth, or in the entire dentition and they are considered to be associated with the disorders of morpho-differentiation or could be attributed to the failure in invagination of Hertwig's epithelial sheath [16].

Variations in the number of roots of the permanent maxillary first molar are described in the literature, mostly regarding the complicated anatomy. The literature shows that single-rooted permanent maxillary first molars, as described in our case report, are a rare finding [20, 21, 22]. Concerning variance, single-rooted maxillary second molars were more often described, in 0.5–5% of cases, which is not negligible [8, 13, 23].

Out of all permanent molars, mandibular second molars show the most variations in the root anatomy and mor-

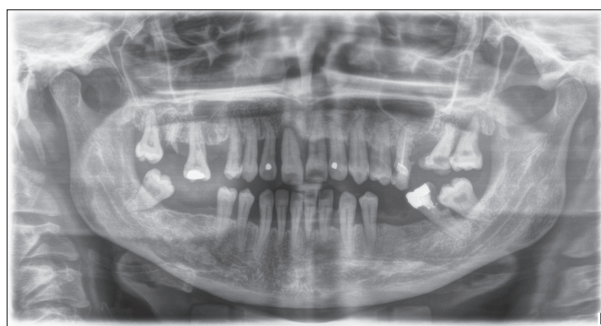


Figure 1. Orthopantomographic image of Patient 1

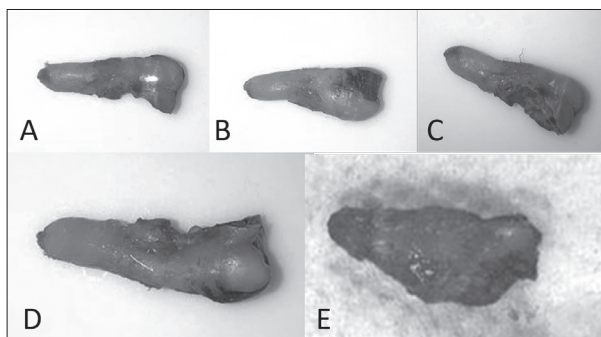


Figure 2. Extracted teeth of Patient 1; A, B, C, D: left permanent mandibular second molar; E: right permanent maxillary second molar

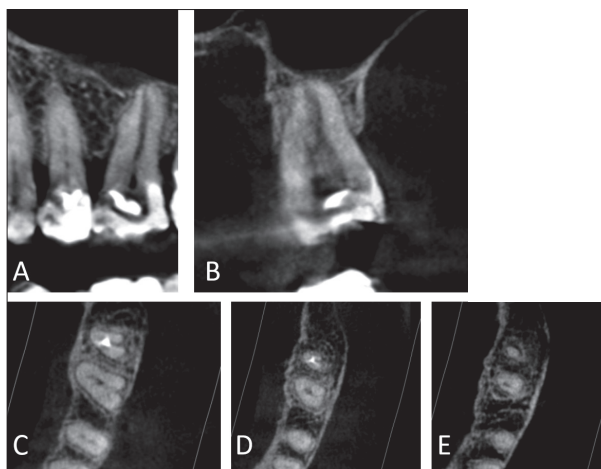


Figure 3. Cone-beam computed tomography images of left permanent maxillary first molar on transversal cross-section (A), sagittal cross-section (B), and axial cross-sections on the coronal (C), medial (D), and apical level (E)

phology. The presence of single-rooted mandibular second molars was found in 1.3–5.8% [8, 24].

Anatomy and morphology of third molars were also previously investigated, with many morphological variations described. In our first case, orthopantomographic image suggested that the patient had all four third molars with simple anatomy, i.e. single root. This could not be confirmed due to the lack of indications for CBCT imaging or extraction of these teeth. Nevertheless, simple anatomy should be expected, as previous studies showed that the same anatomical variations are often present in most of the teeth of the same group [24].

Previously described cases showed that single-rooted anatomy is often presented with bilateral, contralateral, or ipsilateral symmetry [8, 13, 24]. In our first case, regarding the present teeth, we showed the bilateral and contralateral symmetry in third molars, and ipsilateral symmetry in second molars (teeth 27 and 37).

Unlike the symmetrical appearance of simple anatomy, our second case presented a morphological variation in a single tooth. This result emphasizes the importance of preoperative evaluation of root canal morphology of every

individual tooth, as it can facilitate canal identification, prevent the unnecessary removal of a healthy tooth structure, and reduce the incidence of procedural errors.

Anatomical and morphological variations of roots and root canal systems can occur in any tooth. Clinicians should expect these variations when considering dental treatment. Extensive preoperative radiography or utilization of CBCT should be considered during the treatment planning.

Conflict of interest: None declared.

REFERENCES

- Di Nardo D, Gambarini G, Costantini R, Testarelli L, Piasecki L, Al-Sudani D. 3D clinical evaluation of unusual anatomy of a maxillary second molar: a case report. *Biomed J Sci & Tech Res*. 2018; 2:1–4.
- Fogel HM, Cunha RS. Maxillary first molars with 2 distobuccal canals: a case series. *J Endod*. 2017; 43(11):1925–8.
- Nabavizadeh M, Abbaszadegan A, Mirhadi H, Ghahramani Y. Root canal treatment of a maxillary second molar with two palatal canals: a case report. *J Dent (Shiraz)*. 2015; 16(4):371–3.
- Kim Y, Roh BD, Shin Y, Kim BS, Choi YL, Ha A. Morphological Characteristics and classification of mandibular first molars having 2 distal roots or canals: 3-dimensional biometric analysis using cone-beam computed tomography in a Korean population. *J Endod*. 2018; 44(1):46–50.
- De Souza N, Shetty K, Kolipaka RP, Chalakal P. The use of spiral CT in the detection and management of a permanent maxillary first molar with single root and single canal: A rare occurrence. *J Clin Exp Dent*. 2017; 9(9):1172–5.
- Koul M, Shahi M, Abdullah A, Upadhyay V. A rare case of three single rooted permanent second molars: A diagnosis with cone beam computed tomography (CBCT). *J Oral Biol Craniofac Res*. 2017; 7(2):137–40.
- Pawar AM, Pawar M, Kfir A, Singh S, Salve P, Thakur B, et al. Root canal morphology and variations in mandibular second molar teeth of an Indian population: an in vivo cone-beam computed tomography analysis. *Clin Oral Investig*. 2017; 21(9):2801–9.
- Fava LR, Weinfeld I, Fabri FP, Pais CR. Four second molars with single roots and single canals in the same patient. *Int Endod J*. 2000; 33(2):138–42.
- Gu Y, Wang W, Ni L. Four-rooted permanent maxillary first and second molars in a northwestern Chinese population. *Arch Oral Biol*. 2015; 60(6):811–7.
- Parirokh M, Razifar M, Manocherifir H, V Abbott P, Hatami N, Kashi N, et al. Treatment of a maxillary second molar with one buccal and two palatal roots confirmed with cone-beam computed tomography. *Iran Endod J*. 2017; 12(3):371–5.
- Lin YH, Lin HN, Chen CC, Chen MS. Evaluation of the root and canal systems of maxillary molars in Taiwanese patients: A cone beam computed tomography study. *Biomed J*. 2017; 40(4):232–8.
- Ajeti N, Vula V, Apostolska S, Pustina T, Kelmendi T, Emini L, et al. Maxillary second molar with single root and single canal – case report. *Open J Stomatol*. 2015; 5(3):47–52.
- Tang F, Zhang X, Tang X, Wang R, Xu Y, Zou D, et al. The unusual anatomy of the maxillary and mandibular molars diagnosed by cone-beam computed tomography. *Int J Clin Exp Med*. 2017; 10(1):1393–8.
- Nayak G, Singh KK, Shekhar R. Endodontic management of a maxillary first molar with three roots and seven root canals with the aid of cone-beam computed tomography. *Restor Dent Endod*. 2015; 40(3):241–8.
- Munavalli A, Kambale S, Ramesh S, Ajgaonkar N. Mandibular first molar with single root and single root canal. *J Conserv Dent*. 2015; 18(4):346–8.
- Jeddy N, Radhika T, Nithya S, Krithika C, Prabakar R. Single rooted permanent premolars and molars - a rare clinical presentation confirmed using cone beam computed tomography. *J Clin Diagn Res*. 2015; 9(8):ZD15–7.
- Ragunathan R, Ebenezer AV, Mohan AG, Anand S. Unusual canal configuration in maxillary and mandibular second molars. *J Pharm Bioallied Sci*. 2016; 8(Suppl 1):189–91.
- Shemesh A, Levin A, Katzenell V, Ben Itzhak J, Levinson O, Zini A, et al. Prevalence of 3- and 4-rooted first and second mandibular molars in the Israeli population. *J Endod*. 2015; 41(3):338–42.
- Shinde MM, Kamat SB, Chopade RV. Bilateral three rooted mandibular premolars and four rooted mandibular first and second molar: a rare anatomical variant. *J Clin Diagn Res*. 2016; 10(10):ZD05–ZD06.
- Shetty N, Singh V, Rijal S. Single rooted mandibular second molars with single canals: rare occurrence. *Endodontology*. 2009; 21(1):53–7.
- Tian XM, Yang XW, Qian L, Wei B, Gong Y. Analysis of the root and canal morphologies in maxillary first and second molars in a Chinese population using cone-beam computed tomography. *J Endod*. 2016; 42(5):696–701.
- Desai N, Jadhav GR, Raghavendra SS, Mittal P, Patil G. Endodontic management of maxillary first molar with type I canal configuration – a rare case report. *J Clin Diagn Res*. 2015; 9(4):ZD16–7.
- Ratanajirasut R, Panichuttra A, Panmekiate S. A cone-beam computed tomographic study of root and canal morphology of maxillary first and second permanent molars in a Thai population. *J Endod*. 2018; 44(1):56–61.
- Ioannidis K, Lambrianidis T, Beltes P, Besi E, Malliari M. Endodontic management and cone-beam computed tomography evaluation of seven maxillary and mandibular molars with single roots and single canals in a patient. *J Endod*. 2011; 37(1):103–9.

Својеврсна анатомија сталних горњовиличних и доњовиличних кутњака – приказ болесника

Александра Мишић, Сузана Живановић, Мирјана Радовић, Милош Папић, Милица Поповић
Универзитет у Крагујевцу, Факултет медицинских наука, Катедра за стоматологију, Крагујевац, Србија

САЖЕТАК

Увод Анатомија и морфологија корена и система канала корена вишекорених зуба, нарочито кутњака, показују бројне варијације. Преоперативна радиографија, посебно компјутеризована томографија конусног зрака, има изузетан значај у откривању анатомских варијација и својеврсне морфологије канала корена, чије је познавање изузетно важно за успешну ендодонтску терапију и смањење процедуралних грешака на најмањи број.

Приказ случајева Ова студија показује два случајна налаза својеврсне анатомије корена и морфологије канала корена сталних кутњака два пацијента. У случају првог пацијента

дијагноза је постављена коришћењем ортопантомографије и потврђена је после вађења зуба. У другом приказаном случају својеврсна анатомија корена и морфологија канала корена сталног кутњака показане су преоперативним снимком методом компјутеризоване томографије конусног зрака.

Закључак Анатомске и морфолошке варијације корена и система канала корена могу се уочити на свим зубима. Стоматолози би требало да очекују ове варијације, а треба их и детаљно истражити приликом постављања плана терапије.

Кључне речи: једнокорени кутњаци; својеврсна анатомија; дентална радиографија