



The impact of breast augmentation on the skin temperature of the breast

Uticaj augmentacione mamoplastike na temperaturu kože dojke

Branislav Piščević*, Zorica Brdareski^{†‡}, Nenad Stepić^{**‡}, Boban Djordjević^{**‡},
Dejan Vulović[§], Marko Jovanović^{||}, Dejan Vulović[§]

Military Medical Academy, *Clinic for Plastic Surgery and Burns, [†]Clinic for Physical Medicine and Rehabilitation, Belgrade, Serbia; Clinical Center "Kragujevac", ^{||}Center for Plastic Surgery, Kragujevac, Serbia; University of Kragujevac, [§]Faculty of Medical Sciences, Kragujevac, Serbia; University of Defence, [‡]Faculty of Medicine of the Military Medical Academy, Belgrade, Serbia

Abstract

Background/Aim. Complications of breast augmentation, as one of the most common cosmetic surgery, may be different. Besides usual early, local postoperative complications, the most common late complication is capsular contracture. As a specific complication of skin functions after this operation only disturbance of sensibility is described. Since the skin has other functions as well, and because there are no literature data available, the aim of this research was measuring the skin temperature before and after surgery. **Methods.** A prospective interventional study was done in 49 adult women. Bilateral augmentative mammoplasty was performed for breast hypoplasia or on the personal request of a patient with atrophic breasts. Measuring the temperature of the breast skin was done in two points, before the operation, and seven days and three months after surgery. The temperature measurement was done by the infrared thermometer (Pyrometer TROTEC BP21). Statistically significant difference was determined using the *t*-test for related samples. Differences were considered statistically significant if *p* was less than 0.05. Eta squared coefficient was used to determine the important size and according to the Cohen criteria everything over 10:14 signified a major impact. The data

were analyzed by the IBP SPSS Statistics v20. **Results.** In a majority of patients the breasts were hypoplastic (69.39%). The most commonly used implants were 275–500 mL volume (46.94%), and the least common implants were over 500 mL (16.33%). In a little less than 2/3 of the patients submammary incision was used (61.22%). In a majority of patients (67.35%) the prosthesis were placed subglandularly. The average value of the temperature before the operation at the point 1 was 34.49°C, seven days after surgery 34.81°C, and three months after surgery 34.10°C; and at the point 2: 34.60 °C, 34.91°C and 34.19°C in the same time intervals. In relation to the size of the breasts before operation and the size of the implant manufacturer, the localization of the incision and placement of the localization of the prosthesis, no statistically significant differences in the temperature of the skin of the breast before and after surgery was observed. **Conclusion.** Our results on the change of skin temperature after the breast augmentation could be significant preoperative information for the patients.

Key words:
breast implantation; reconstructive surgical procedures; skin temperature; treatment outcome.

Apstrakt

Uvod/Cilj. Komplikacije augmentacije grudi, kao jedne od najčešćih estetskih operacija, su moguće i različite. Osim uobičajenih ranih, lokalnih postoperativnih komplikacija, najčešća kasna komplikacija je kapsularna kontraktura. Kao specifična komplikacija poremećaja funkcije kože posle ove operacije opisan je samo poremećaj senzibiliteta. S obzirom na to da koža ima i druge funkcije, kao i zbog toga što ne postoje podaci u literaturi, cilj istraživanja bio je merenje temperature kože dojke pre i posle operacije. **Metode.**

Urađena je prospektivna intervencijska studija kod 49 punoletnih žena koje nisu rađale. Bilateralna augmentaciona mamoplastika je rađena zbog hipoplazije dojki ili na lični zahtev pacijenta sa eutrofičnim dojkama. Merenje temperature kože dojke je rađeno u dve tačke, pre operacije, sedam dana posle operacije i tri meseca posle operacije. Merenje temperature je učinjeno infracrvenim termometrom (Pyrometer BP21 TROTEC). Statistička značajnost razlike je određena korišćenjem *t*-testa za vezane uzorke. Razlike su smatrane statistički značajnim ukoliko je $p < 0,05$. Koeficijent eta kvadrat određivao je veličinu uticaja i prema kriterijumu

Cohena, sve preko 0,14 označavalo je veliki uticaj. Dobijeni su analizirani programom IBM SPSS Statistics v20. **Rezultati.** Kod većine ispitanica dojke su bile hipoplastične (69,39%). Najčešće su korišćeni implantati zapremine 275–500 mL (46,94%), a najređe implantati zapremine preko 500 mL (16,33%). Kod nešto manje od 2/3 pacijenata primenjen je submamarni rez (61,22%). Kod većine pacijenata (67,35%), proteza je plasirana subglandularno. Prosečna vrednost temperature pre operacije u tački 1 bila je 34,49°C, sedam dana nakon operacije 34,81°C, a tri meseca nakon operacije 34,10°C, a u tački 2: 34,60°C, 34,91°C i 34,19°C u

istim vremenskim intervalima. U odnosu na veličinu dojki pre operacije, veličinu i proizvođača implantata, lokalizaciju incizije i lokalizaciju plasiranja proteze, nisu nađene statistički značajne razlike u temperaturi kože dojke pre i posle operacije. **Zaključak.** Naši rezultati o promeni temperature kože dojke posle augmentacije mogli bi da imaju značaj u preoperativnom informisanju pacijenta.

Ključne reči:

dojka, implantati; hirurgija, rekonstruktivna, procedure; koža, temperatura; lečenje, ishod.

Introduction

Breast augmentation is one of the most frequent aesthetic surgeries and in some countries it is the leading one¹. For example, there are more than 300,000 mammoplasties in the USA, every year. Different surgical approaches and different implants are used^{2–6}. For the most plastic surgeons, this is the routine surgery, but as any placement of a foreign material into the body, it must be taken seriously.

Complications of mammoplasty are possible and different in type and incidence^{7–14}. They are more or less frequent, minor or significant, nonspecific or specific, local or systemic, early or late. Some of the mammoplasty complications are specific to this type of operation, the capsular contracture being the most common, which was studied in detail⁹. According to literature data, the possible specific complication of mammoplasty augmentation is a sensory disturbance^{10–13}.

There are no available data on the skin temperature after mammoplasty augmentation. A woman with the great desire to resize and reshape the breast, very often is not interested in possible complications, and sometimes, not completely informed by a surgeon. Therefore, the aim of this paper was to research breast skin temperature after augmentation using silicon prosthesis, assuming that a change occurs on the breast skin after the operation, which could be important in providing information to the patient before surgery.

Methods

In the prospective intervention study, breast skin temperature was taken on 49 Caucasian women before and after augmentation using silicon prosthesis. The operations were

performed at the Clinic for Plastic Surgery and Burns of the Military Medical Academy in Belgrade, over the period from January 1, 2012 until January 1, 2016, with the approval of the Ethics Committee of the Military Medical Academy.

The inclusion criteria for participation in the study were: women of age up to 60 years that did not give birth, bilateral mammoplasty augmentation due to hypoplasia of the breasts or at personal request of the examiners with eutrophic breasts. Furthermore, an inclusion criterion was also a signed consent to participate in the study, after the patient was first acquainted in detail by the researcher with the purpose and significance of the research. An eutrophic breast was considered a concave shaped breast, vertically stretching from 3rd or 4th rib to the 6th or 7th rib, and horizontally, from the parasternal line to the medial axillary line, with a base forming an angle of approximately 100° (Figure 1). The excluding criteria in the study were certain changes in the local status of the breast [congenital anomalies of the breast except hypoplasia, higher grade of breast ptosis (Grade 3 and 4 according to Becker), mastectomy, secondary augmentation mammoplasty, scar]; unilateral mammoplasty augmentation; ovulation and menstruation; severe forms of chronic disease (diabetes melitus, cardiovascular, respiratory, nephrological, hepatological, neurological, dermatological, autoimmune); psychiatric examinees; autoimmune nervous system disorders; use of certain drugs (estrogens, gestagens or their antagonists, sympathomimetics, adrenergic blockers, cholinergics, antimuscarinic drugs); early postoperative complications (higher degree of edema in one or both breasts, hematoma, seroma, dehiscence, necrosis, infection, implant protrusion), followed by incomplete medical documentation, and inability of adequate control testing until the end of research.

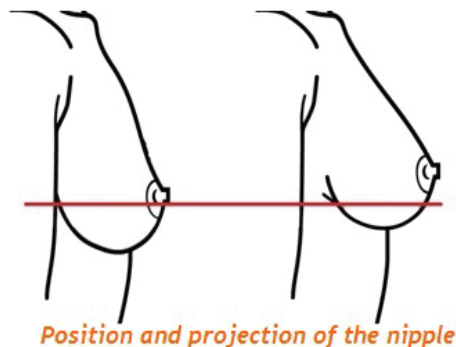
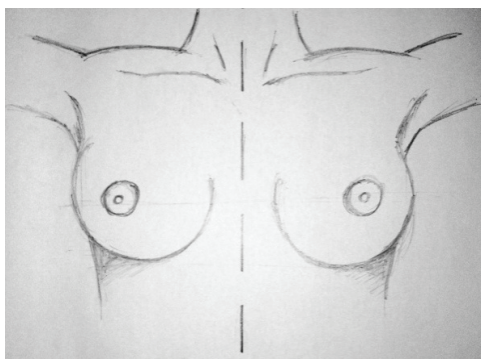


Fig. 1 – Morphology and topography of eutrophic breast.

On admission to the Clinic, the participants had the following medical documentation: specialist medical report, the breast ultrasound examination findings, mammography, hematogram, glycemy, urea and creatinine values, international normalised ratio (INR) and activated partial thromboplastin time (APTT), laboratory urine findings, X-ray of the lungs, electrocardiogram, internist's findings and breast photo. All the operations were performed under general endotracheal anesthesia. Submammary or periareolar incision was applied. Textured silicone implants of different shape, by different manufacturers were used and placed in front of (subglandular) or behind the large chest muscle (subpectoral). The implant size depended on the degree of hypoplasia, size of eutrophic breast and patient's wish. The breast temperature was taken at three-time periods: before the operation (up to 24 h), seven days and three months after the operation. The tests were performed at the Clinic for Physical Medicine and Rehabilitation of the Military Medical Academy in Belgrade. The breast temperature measurement was performed by specialists in physical medicine and rehabilitation. While doing so, during the postoperative measurement, they did not have insight into the results of preoperative measurement of the same patient. The same conditions were provided during the test: room temperature about 21°C, relative air humidity 40%–55% and relaxed lying position of the patient. The breast skin temperature was taken by the infrared thermometer (Pyrometer BP21 TROTEC) in two points (Figure 2). The first point was the areola area, directly medially from the mamilla, and the second point was in the middle of the horizontal line that connects the center of the frontal part of the sternum and mamilla (Figure 1, drawing and photos).

Statistical processing of the data was performed applying the IBM SPSS Statistics v20 program. The results were presented descriptively, using the table and graph. The continuous variables are shown as mean values and standard deviations, and categorical variables as percentile share of cer-

tain categories. Statistical significance of temperature difference between two moments in time was determined by using the *t*-test for paired samples. The differences were considered statistically significant if $p < 0.05$. The eta squared coefficient determined the impact value and according to the Cohen criteria, everything above 0.14 indicated a large impact.

Results

The age in a 49-patient sample was in the range of 18–60 years (average 29.41 years). In most of the subjects the breasts were hypoplastic (69.39%), and in 15 subjects eutrophic (30.61%). Implants volume of 275–500 mL (46.94%) were most commonly used, in 18 (36.73%) patients while implants up to 275 mL, and implants volume of over 500 mL were rarely used (16.33%). In less than 2/3 of the participants, submammary incision was applied (61.22%), and less commonly the periareolar incision (38.78%). In most of the participants (67.35%), the placement of the prosthesis was subglandular, and in 16 (32.66%) submuscularly participants (Table 1).

Table 1

Patient's data and information about the operation

Variable	Patients, n (%)
Size of the breast	
hypoplastic	34 (69.39)
eutrophic	15 (30.61)
Size of the implant	
to 275 cc	18 (36.73)
from 276 ccm to 500 cc	23 (46.93)
over 500 cc	8 (16.32)
Type of the incision	
submammary	30 (61.22)
periareolar	19 (38.78)
Placement of the implant	
subglandularly	33 (67.35)
submuscularly	16 (32.65)

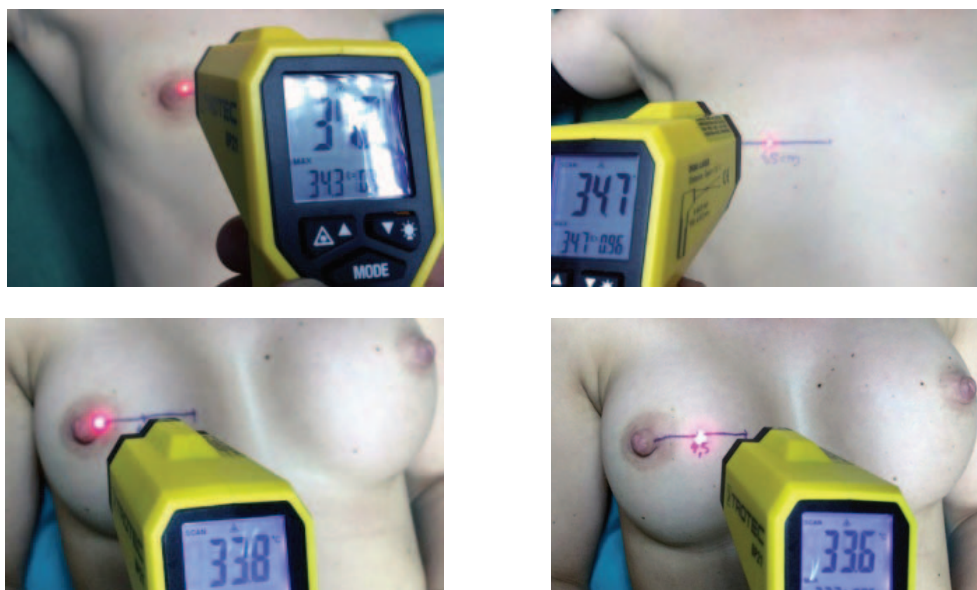

Fig. 2 – Breast skin temperature measurement by infrared thermometer at two points. Up: preoperation; down: postoperation in the same patient.

Table 2

Average values of the differences in the breast skin temperature after breast augmentation in relation to the value before operation

Time after operation	Average differences (Δ) in the breast skin temperature ($^{\circ}\text{C}$)	
	Point 1	Point 2
7 days	$\Delta = 0.32$ ($t = 16.248$; $df = 48$; $p = 0.000$; $\eta^2 = 0.85$)	$\Delta = 0.31$ ($t = 22.947$; $df = 48$; $p = 0.000$; $\eta^2 = 0.92$)
3 months	$\Delta = 0.39$ ($t = 31.738$; $df = 48$; $p = 0.000$; $\eta^2 = 0.95$)	$\Delta = 0.41$ ($t = 34.687$; $df = 48$; $p = 0.000$; $\eta^2 = 0.96$)

Point 1 – the areola area, directly medially from the mamilla;

Point 2 – middle of the horizontal line that connects the center of the frontal part of the sternum and mamilla.

The average temperature value before the operation at the point 1 was 34.49°C , seven days after the operation 34.81°C , and three months after the operation 34.10°C . The average temperature value before the operation at the point 2 was 34.60°C , seven days after the operation 34.91°C , and three months after the operation 34.19°C . No statistically significant differences were determined in the breast skin temperature before and after the operation in relation to the breast size before the operation, the implant size and manufacturer, incision and prosthesis placement localization. On the other hand, by applying the t -test for paired samples, we reached a conclusion that there was a statistically significant difference between the breast skin temperature at the point 1 before and seven days after the operation; this difference on average was 0.32°C ($t = -16.25$, $df = 48$, $p = 0.000$) (Table 2). The average temperature value, seven days after the operation at the point 1 was 34.81°C , and three months after the operation 34.10°C . Applying the t -test for paired samples we concluded that there was a statistically significant difference between the skin temperature seven days and three months after the operation ($\Delta = 0.72^{\circ}\text{C}$ $t = 47.33$, $df = 48$, $p = 0.000$). The t -test for paired samples also showed a statistically significant difference between the preoperative temperature and temperature after three months. This difference was 0.39°C ($t = 31.74$, $df = 48$, $p = 0.000$). The eta squared coefficient determined the impact value and according to the Cohen criteria everything above 0.14 indicates a large impact. Considering that our values were significantly higher for all three previous conclusions, it means that there was a great difference between the breast skin temperature at the different intervals of time after operation in relation to the value before operation (Table 2).

Using the t -test for paired samples, it was found that there was a statistically significant difference between the breast skin temperature at the point 2 before the operation and three months after; the average difference was 0.41°C ($t = 34.69$, $df = 48$, $p = 0.000$). According to the eta squared coefficient, the obtained values were significantly higher for all three previous conclusions; therefore, the difference between the temperatures was great (Table 2).

Discussion

Human skin temperature is one of the four vital parameters. Localized, designated measurement of skin temperature of a specific body region is rarely used in medical practice.

The examples of this are vascular, endocrine, rheumatic and skin diseases¹⁵⁻¹⁷. Measurement of skin temperature in surgery is used in the postoperative monitoring with the use of arterial, free tissue flaps, mostly free-microvascular¹⁸⁻²¹ as well as after tissue expansion²². The measurement of breast skin temperature was taken in analysis of the periods after physical strain and in nursing mothers²²⁻²⁴.

On research of references pertaining to mammoplasty, particularly the analysis of possible early and later postoperative complications, we did not find the data that directly indicate a change in the breast skin temperature after this operation. The other authors mostly analyzed the hematoma, seroma, dehiscence, infection, hypertrophic scar and Mondor's disease (superficial thrombophlebitis), as well as possible early complications, asymmetry, capsular contracture, mamilla and areola sensitivity disorder, prosthesis deflation or rupture, appearance of autoimmune diseases and anaplastic large cell lymphoma (ALCL) as possible later complications⁷⁻¹⁴. ALCL is a rare type of non-Hodgkin's lymphoma, the appearance of which after breast augmentation was published for the first time in January 2011 according to the FDA report, and some 40 cases have been described in the world to date¹⁴. The relation between prosthesis implantation and the appearance of breast malignancy was not proven.

Until today, there is no reachable data about the temperature changes of the breast skin after augmentation mammoplasty. We can try to explain our results. Our measurements indicated that there was a statistically significant difference between the temperature before and seven days after the operation, whereas this difference on average was 0.31°C ($p = 0.000$). Also, we recorded a statistically significant difference between the temperature seven days and three months after the operation ($p = 0.000$). A statistically significant difference was noted between the preoperative temperature and temperature after three months.

Augmentation mammoplasty is some kind of tissue injuries. Tissue injury can be induced by: allergic reactions, autoimmunity, infection or mechanical damage often results in the disruption of normal tissue architecture, initiating a healing response²⁵. Tissue healing process after the injury includes two more very important processes- inflammation and healing.

Tissue integrity is disrupted and inflammation is normal answer. Also, inflammation additionally disturbs the tissue.

All these facts, which include very strong immunity reaction, contribute to the cellular damage and the tissue destruction. Local inflammation implies synthesis of different proinflammatory cytokines: interleukin (IL)-1, IL-6, TNF- α , chemokines, etc.²⁶. Cytokines and chemokines by their gradients recruit the inflammatory cells on the place of tissue injuries²⁷. Neutrophils, eosinophils, lymphocytes and macrophages are observed at sites of acute injury with cell debris and areas of necrosis cleared by phagocytes²⁸. Vascular changes are detected like increased permeability with increased influx of the inflammatory cells at the site of injury. These cells have the role to clean the inflammation place and to make the base for the healing process. Inflammatory cells secrete the chemokines which induce the profibrotic cells to settle the injury place²⁹. Fibroblasts with profibrotic conduction of cytokines activate the process of the healing. At the end of this process, the fibrin-rich scaffold formation, wound contraction, closure and re-epithelialization can be observed³⁰. Augmentation mammoplasty, as some kind of the tissue injury, activates this very compound process. Ojo-Amaize et al.³¹ recorded the elevated concentrations of proinflammatory cytokines IL-1b and IL-1 receptor antagonist in plasma of women with silicone breast implants³². Also, some data indicated that physiatric procedures (electromagnetic pulse field) decreased pain and IL-1b level after the

augmentation mammoplasty³². Including all these facts, we can explain the temperature changes of the skin after augmentation mammoplasty. Increased temperature seven days after the surgery, noticed in our results, can be explained by the inflammation process. Inflammation is the answer to the local tissue injury (surgery, foreign body-silicone implants). As the process is continued by activating the healing cascade, we propose the explanation for the decreased skin temperature three months after the surgery. The healing process, including the fibrotic tissue production for modeling the tissue after the inflammation with decreased local blood flow at the site of the inflammation, is the possible answer for this phenomenon.

Conclusion

According to the existing literature and results of our research, we concluded that the implantation of silicon prosthesis can affect the change in breast skin temperature in the postoperative period. Skin temperature changes can be explained by the inflammation and healing process, as the consequence of the augmentation mammoplasty. The obtained data can have a significant impact on the patient's decision concerning this operation. In addition to this, this paper can also be an incentive to test other functions of the breast skin in mammoplasty augmentation.

R E F E R E N C E S

1. *American Society of Plastic Surgeons*. National Clearinghouse of Plastic Surgery Procedural Statistics. 2013 Plastic Surgery Statistics Report. American Society of Plastic Surgeons; 2014.
2. *Codner MA, Mejia JD, Locke MB, Mahoney A, Thiels C, Nabai FR, et al.* A 15-year experience with primary breast augmentation. *Plast Reconstr Surg* 2011; 127(3): 1300–10.
3. *Swanson E.* Prospective outcome study of 225 cases of breast augmentation. *Plast Reconstr Surg* 2013; 131(5): 1158–66.
4. *Hidalgo DA, Sinno S.* Current Trends and Controversies in Breast Augmentation. *Plast Reconstr Surg* 2016; 137(4): 1142–50.
5. *Namoum JD, Largent J, Kaplan HM, Oefelein MG, Brown MH.* Primary breast augmentation clinical trial outcomes stratified by surgical incision, anatomical placement and implant device type. *J Plast Reconstr Aesthet Surg* 2013; 66(9): 1165–72.
6. *Adams WP, Small KH.* The Process of Breast Augmentation with Special Focus on Patient Education, Patient Selection and Implant Selection. *Clin Plast Surg* 2015; 42(4): 413–26.
7. *Vitug A, Newman L.* Complications in Breast Suregry. *Surg Clin N Am* 2007; 87(4): 431–51.
8. *Shi H, Cao C, Li X, Chen L, Li S.* A retrospective study of primary breast augmentation: Recovery period, complications and patient satisfaction. *Int J Clin Exp Med* 2015; 8(10): 18737–43.
9. *Headon H, Kasem A, Mokbel K.* Capsular Contracture after Breast Augmentation: An Update for Clinical Practice. *Arch Plast Surg* 2015; 42(5): 532–43.
10. *Okwueze MI, Spear ME, Znyghuizen AM, Braiin SA, Ajmal N, Nanney LB, et al.* Effect of augmentation mammoplasty on breast sensation. *Plast Reconstr Surg* 2006; 117(1): 73–83; discussion 84–5.
11. *Mofid M, Klatsky SA, Singh NK, Nababedian MY.* Nipple-areola complex sensitivity after primary breast augmentation: A comparison of periareolar and inframammary incision approaches. *Plast Reconstr Surg* 2006; 117(6): 1694–8.
12. *Araco A, Araco F, Sorge R, Gravante G.* Sensitivity of the nipple-areola complex and areolar pain following aesthetic breast augmentation in a retrospective series of 1200 patients: Peri-areolar versus submammary incision. *Plast Reconstr Surg* 2011; 128(4): 984–9.
13. *Land HG, Turkle J, Jewell ML, Murphy DK.* Low Risk of Skin and Nipple Sensitivity and Lactation Issues After Primary Breast Augmentation with Form-Stable Silicone Implants: Follow-Up in 4927 Subjects. *Aesthet Surg J* 2016; 36(6): 672–80.
14. *Xu J, Wei S.* Breast implant-associated anaplastic large cell lymphoma: Review of a distinct clinicopathologic entity. *Arch Pathol Lab Med* 2014; 138(6): 842–6.
15. *Staffa E, Bernard V, Kubiček L, Vlachovskej R, Vlk D, Mornstein V, et al.* Using Noncontact Infrared Thermography for Long-term Monitoring of Foot Temperatures in a Patient with Diabetes Mellitus. *Ostomy Wound Manage* 2016; 62(4): 54–61.
16. *Greenwald M, Ball J, Guerretaz K, Paulus H.* Using dermal Temperature to identify rheumatoid arthritis examiners with radiologic progressive disease in less than one minute. *Arthritis Care Res* 2016; 68(8): 1201–5.
17. *Engebretsen KA, Jobansen JD, Kezic S, Linneberg A, Thyssen JP.* The effect of environmental humidity and temperature on skin barrier function and dermatitis. *J Eur Acad Dermatol Venereol* 2016; 30(2): 223–49.
18. *Jones NF.* Postoperative monitoring of microsurgical free tissue transfers for head and neck reconstruction. *Microsurgery* 1988; 9(2): 159–64.
19. *Furnas H, Rosen JM.* Monitoring in microvascular surgery. *Ann Plast Surg* 1991; 26(3): 265–72.
20. *Kozarski J, Pantelić Lj, Novaković M, Pavlica M, Panajotović Lj.* Temperature of the skin in microvascular flaps. *Vojnosanit Pregl* 1999; 56(5): 483–9. (Serbian)
21. *Kraemer R, Lorenzen J, Knobloch K, Papst S, Kabbani M, Koennecker S, et al.* Free flap microcirculatory monitoring correlates to

- free flap temperature assessment. *J Plast Reconstr Aesthet Surg* 2011; 64(10): 1353–8.
22. *Gazzola R, Cavallini M, Parodi PC, Benanti E, Vaienti L.* Radiometric infrared temperature detection in skin expansion. *Plast Reconstr Surg* 2012; 130(5): 762e–4e.
23. *Kimura C, Matsuoka M.* Changes in breast skin temperature during the course of breastfeeding. *J Hum Lact* 2007; 23(1): 60–9.
24. *Ayres B, White J, Hedger W, Scurr J.* Female upper body and breast skin temperature and thermal comfort following exercise. *Ergonomics* 2013; 56(7): 1194–202.
25. *Wynn TA.* Common and unique mechanisms regulate fibrosis in various fibroproliferative diseases. *J Clin Invest* 2007; 117(3): 524–9.
26. *Gauldie J.* Pro: inflammatory mechanisms are a minor component of the pathogenesis of idiopathic pulmonary fibrosis. *Am J Resp Crit Care Med* 2002; 165(9): 1205–6.
27. *Erjefalt JS, Sundler F, Persson CG.* Eosinophils, neutrophils, and venular gaps in the airway mucosa at epithelial removal: Restitution. *Am J Resp Crit Care Med* 1996; 153(5): 1666–74.
28. *Bringardner BD, Baran CP, Eubank TD, Marsh CB.* The role of inflammation in the pathogenesis of idiopathic pulmonary fibrosis. *Antioxid Redox Signal* 2008; 10(2): 287–301.
29. *Agostini C, Gurrieri C.* Chemokine/cytokine cocktail in idiopathic pulmonary fibrosis. *Proc Am Thorac Soc* 2006; 3(4): 357–63.
30. *Ivano M, Plieth D, Danoff TM, Xue C, Okada H, Neilson EG.* Evidence that fibroblasts derive from epithelium during tissue fibrosis. *J Clin Invest* 2002; 110(3): 341–50.
31. *Ojo-Amaize EA, Lawless OJ, Peter JB.* Elevated concentrations of interleukin-1 beta and interleukin-1 receptor antagonist in plasma of women with silicone breast implants. *Clin Diagn Lab Immunol* 1996; 3(3): 257–9.
32. *Robde CH, Taylor EM, Alonso A, Ascherman JA, Hardy KL, Pilla AA.* Pulsed Electromagnetic Fields Reduce Postoperative Interleukin-1 β , Pain, and Inflammation: A Double-Blind, Placebo-Controlled Study in TRAM Flap Breast Reconstruction Patients. *Plast Reconstr Surg* 2015; 135(5): 808–17.

Received on April 10, 2017.

Revised on July 18, 2017.

Accepted on August 17, 2017.

Online First September, 2017.