CASE REPORT
(CC BY-SA)

UDC: 616.89-008.441.3-06:616.831
https://doi.org/10.2298/VSP160523099M

Unusual case of Marchiafava-Bignami disease presenting as axial hypotonia

Neobičan slučaj Marchiafava-Bignami bolesti koja se manifestovala kao aksijalna hipotonija

Svetlana D. Miletić Drakulić*†, Jasna Jevdjić*‡, Dejan Aleksić*†, Gordana Tončev*†

University of Kragujevac, *Faculty of Medical Sciences, Kragujevac, Serbia; Clinical Center Kragujevac, †Clinic for Neurology, ‡Department of Surgery, Kragujevac, Serbia

Abstract

Introduction. Marchiafava-Bignami disease is a rare disorder mostly associated with chronic heavy alcohol consumption that results in progressive demyelination and necrosis of the corpus callosum. **Case report.** We reported a 35-year-old woman with a history of alcohol consumption and malnutrition. Neurological examination revealed axial hypotonia, dysarthric speech and lack of motor coordination. The brain multislice computed tomography imaging demonstrated hypodense lesion of the corpus callosum. On the basis of her history, clinical features and imaging studies, the diagnosis of an acute form of Marchiava-Bignami disease was made. Definite diagnosis was confirmed at autopsy. **Conclusion.** Marchiafava-Bignami disease is of a medical emergency and early recognition and early aggressive treatment are critical for a good clinical outcome. To our knowledge, this is the first case of Marchiafava-Bignami disease presented with axial hypotonia.

Key words:
alcoholism; corpus callosum; diagnosis; marchiafava-bignami disease; tomography, x-ray computed.

Apstrakt

Uvod: Marchiafava-Bignami bolest je veoma retka i najčešće je udružena sa hroničnom konzumacijom alkohola koja dovodi do progresive demijelinizacije i nekroze korpusa kalozuma. **Prikaz bolesnika.** Prikazana je žena stara 35 godina sa istorijom konzumiranja alkohola i pothranjenosti. Neurološkim pregledom nađena je aksijalna hipotonija, dizartričan govor i gubitak motorne koordinacije. Primenom multislajsne kompjuterizovane tomografije mozga otkrivena je hipodenzna lezija korpus kalozuma. Na osnovu anamneze, kliničkog nalaza i neuroradiološke eksploracije postavljena je dijagnoza akutne forme Marchiava-Bignami bolesti. Definitivna dijagnoza je potvrđena autopsijom. **Zaključak.** Marchiafava-Bignami bolesti je urgentno medicinsko stanje i njeno rano prepoznavanje i rano agresivno lečenje su ključni za povoljan ishod. Prema našem znanju, ovo je prvi slučaj Marchiava-Bignami oboljenja koje se kod bolesnika prezentovalo kao aksijalna hipotonija.

Ključne reči:
alkoholizam; corpus callosum; dijagnoza; marchiafava-bignami bolest; tomografija, kompjuterizovana, rendgenska.

Introduction

Marchiafava-Bignami disease (MBD) is a rare disorder mostly associated with chronic heavy alcohol consumption. MBD is characterized by the primary demyelination and necrosis of the corpus callosum [1]. The computerized tomography (CT) and magnetic resonance imaging (MRI) are helpful in diagnosis in the early stages of the disease [2].

Case report

We reported a 35-year-old woman with a history of drinking red wine and very poor nutritional status. One month before the admission, the patient suddenly developed gait ataxia and slurred speech. The patient was hospitalized because she experienced acute onset vomiting and mental confusion. Physical examination showed asthenia. Neurological examination revealed dysarthric speech, lack of motor coordination and pronounced

Correspondence to: Svetlana D. Miletić Drakulić, Clinical Center Kragujevac, Clinic for Neurology, Zmaj Jovina 30, 34 000 Kragujevac, Serbia. E-mail: mileticdrakulic@gmail.com

axial hypotonia. Hypotonia was presented primarily of neck musculature with the impossibility of keeping the head and achieving a vertical position with her head kept falling off the back. The results of routine blood tests and cerebrospinal fluid examinations were all within the normal limits. Electroencephalography (EEG) showed diffuse slow waves of 6–8 Hz without epileptiform discharge. The brain CT, which was performed only in transverse plane immediately at admission, showed no significant abnormalities.

Three days later, her level of consciousness rapidly deteriorated and she became comatose [Glasgow Coma Scale (GCS) score was 3] with respiratory failure that required mechanical ventilation. The follow-up brain multislice CT (MSCT) imaging performed one month after the onset of symptoms demonstrated hypodense lesion of the corpus callosum involving genu, body and splenium, in sagittal plane (Figure 1). The diagnosis of an acute form of MBD was made. The patient was treated with a high-dose of thiamine (vitamin B_1), 100 mg per day. A high dose of intravenous corticosteroids was also administered. Three days after the onset of the therapy the patient showed improvement in her consciousness and become sopor, but 11 days after the admission to hospital, the patient got pneumonia and died. A clinical diagnosis was confirmed by postmortem pathologic findings. The main pathologic change was the degeneration of the corpus callosum with demyelination and fragmentation of some axons. Demyelination was accompanied by the focal collections of macrophages and present proliferation astrocytes (Figure 2). General autopsy observation included fibrinopurulent pneumonia and lung abscess on the left side.

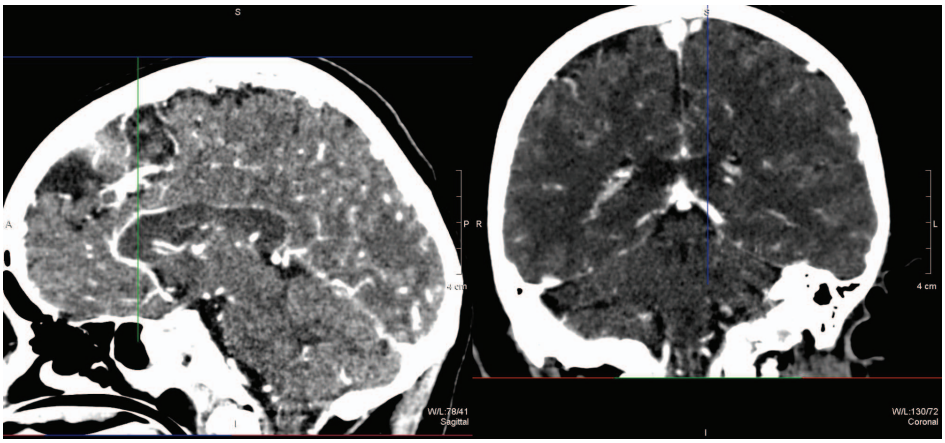

Fig. 1 – Hypodense of the corpus callosum involving genu, body and splenum.

A) B)

C) D)

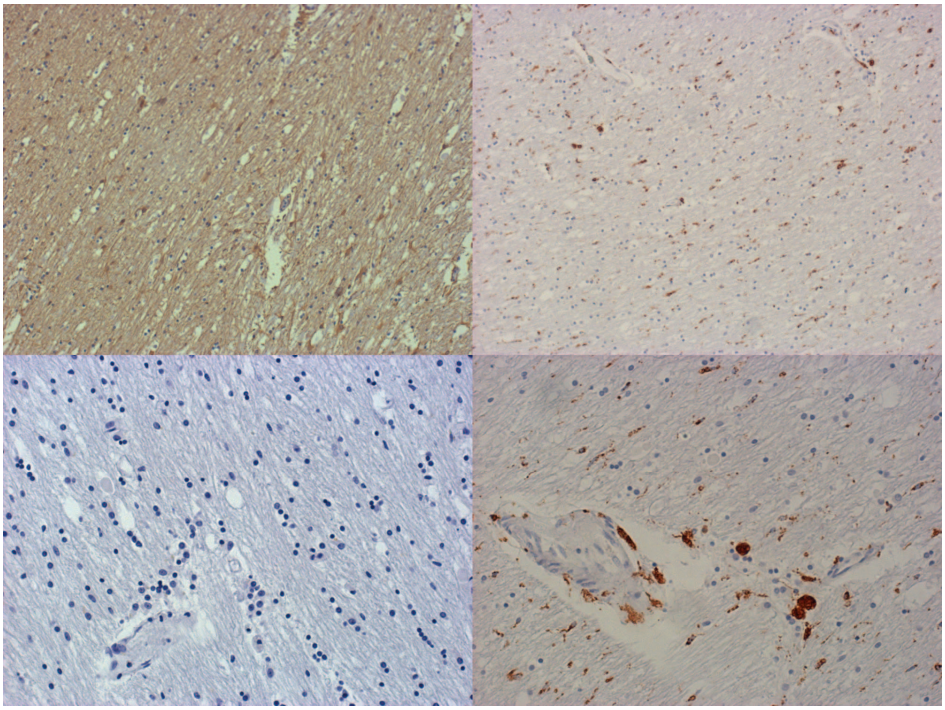

Fig. 2 – Immunohistochemical application for antibodies to neurofilament (NF), macrophage (CD 68) and astrocytes (EFP): A) Demyelination with relative sparing of the axons (100×); B) Humerous lipid-laden macrophages (100×); C) Amyloid corpuscles with macrophage mobilization (100×); D) Blood vessels proliferation and hyalinization of their walls (200×).

Discussion

MBD is a rare disorder mostly associated with chronic alcoholism. Although several cases of MBD were associated with non-alcoholic patients, most instances of MBD have occurred as a result of malnutrition. Our patient had a history of malnutrition and consummation of red wine for an unknown period. It is generally accepted that the disease is due to the deficiency of the vitamin B_1, thiamine [3, 4].

The syndrome is in most instances seen in middle-aged to elderly men drinkers [5]. Our patient was a young women with the acute form of MBD.

In the acute stage, the patient often has non-specific neurologic changes such as dysarthria, seizures, confusion, coma, generalized muscular hypertonia and clinic diagnosis of MBD can be difficult [6, 7]. All authors discussing MBD emphasized the difficulty of making the clinical diagnosis during life because the disease is rare and its manifestations are non-specific [8]. The course of the disease in our patient was acute and presented with unusual finding such as axial hypotonia.

MRI and CT are more useful for early diagnosis and detailed analysis of the distribution of lesions [2]. Our patient presented the characteristic follow-up brain MSCT imaging, performed one month after the onset of the symptoms, and then the disease was recognized.

The most important is the early recognition and detection of MBD. In the era before CT scanning and MRI, MBD was confirmed almost exclusively at autopsy. Our patient had an acute form of MBD that had a rapid course resulting in the fatal outcome. No standardized treatment protocols were established in MBD. The early aggressive treatment is often associated with marked clinical improvement. Clinical improvement was documented when using a high dose of corticosteroids and thiamine [9].

Conclusion

MBD is of a medical emergency and the early recognition and early aggressive treatment are critical for a good clinical outcome. To our knowledge, this is the first case of MBD presented with axial hypotonia.

R E F E R E N C E S

1. *Carrilho PE, Santos MB, Piasecki L, Jorge AC.* Marchiafava-Bignami disease: A rare entity with a poor outcome. Rev Bras Ter Intensiva 2013; 25(1): 68–72. (English, Portuguese)
2. *Hillbom M, Saloheimo P, Fujioka S, Wszolek ZK, Juvela S, Leone MA.* Diagnosis and management of Marchiafava-Bignami disease: a review of CT/MRI confirmed cases. J Neurol Neurosurg Psychiatr 2014; 85(2): 168–73.
3. *Garcia-Santibanez R.* Marchiafava-Bignami disease presenting as acute dysarthria and ataxia. Alcohol Alcohol 2015; 50(2): 256–7.
4. *Kumar KS, Challam RJ, Singh WJ.* Marchiafava - Bignami Disease: A Case Report. JCDR 2014; 8(8): RD01–RD02.
5. *Murthy KP.* Magnetic resonance imaging in Marchiafava-Bignami syndrome: a cornerstone in diagnosis and prognosis. Case Rep Radiol. 2014; 2014: 609708.
6. *Wagh SJ, Dabhi AS, Thorat PB, Vasava JF, Modia JP, Shah MJ.* Marchiafava-Bignami disease: a rare presentation of chronic alcoholism. J Indian Acad Clin Med 2012; 13(4): 59–61.
7. *Tung CS, Wu SL, Tsou JC, Hsu SP, Kuo HC, Tsui HW.* Marchiafava-Bignami disease with widespread lesions and complete recovery. AJNR Am J Neuroradiol 2010; 31(8): 1506–7.
8. *Koeppen AH, Barron KD.* Marchiafava-Bignami disease. Neurology 1978; 28(3): 290–4.
9. *Dujmovic I, Nikolic I, Gavric-Kezic M, Dackovic J, Mesaros S, Drulovic J.* Teaching NeuroImages: reversible widespread brain MRI lesions in Marchiafava-Bignami disease. Neurology 2015; 84(11): e81–2.

Received on May 23, 2016.
Revised on June 21, 2017.
Accepted on July 11, 2017.
Online First September, 2017.