

ORIGINAL ARTICLE / ОРИГИНАЛНИ РАД

The influence of intravitreally applied triamcinolone acetonide on vitreal hemorrhage resorption and visual acuity in patients with proliferative diabetic retinopathy

Nenad Petrović^{1,2}, Dušan Todorović¹, Sunčica Srećković^{1,2}, Tatjana Šarenac-Vulović^{1,2}, Mirjana Janičijević-Petrović^{1,2}, Svetlana Paunović², Katarina Janičijević³, Svetlana Jovanović^{1,2}

¹University of Kragujevac, Faculty of Medical Sciences, Department of Ophthalmology, Kragujevac, Serbia;

²Kragujevac Clinical Centre, Ophthalmology Clinic, Kragujevac, Serbia;

³University of Kragujevac, Faculty of Medical Sciences, Department of Social Medicine, Kragujevac, Serbia



SUMMARY

Introduction/Objective Vitreal hemorrhage is one of the possible complications of diabetic retinopathy, followed by intensive decrease of visual acuity. Corticosteroids are commonly used in treatment of different retinal diseases, due to their anti-inflammatory and anti-angiogenic effect. Triamcinolone acetonide applied intravitreally remains in the eye for several months, releases its crystals, and decreases the density of vitreal hemorrhage.

The main goal of this study is to evaluate the efficacy of 20 mg intravitreal triamcinolone acetonide for the management of long-lasting vitreal hemorrhage, occurred as a complication of proliferative diabetic retinopathy in non-vitreotomized eyes.

Methods In a prospective study performed between January 1, 2015 and January 1, 2016, 24 patients with vitreal hemorrhage who received intravitreal triamcinolone acetonide were compared to 21 patients from the control group. The control group consisted of patients with proliferative diabetic retinopathy and similar degree of vitreal hemorrhage. All the patients underwent an ophthalmological examination at the beginning of the study, seven days, one, three, six, nine, and 12 months after intravitreal administration of 20 mg of triamcinolone acetonide. In addition to vitreal hemorrhage and visual acuity, intraocular pressure and cataract development were also analyzed.

Results Statistically significant difference in the density of vitreal hemorrhage and visual acuity was recorded during the first and the third month after administering triamcinolone. Twenty-nine percent of the patients had a temporary rise in intraocular pressure after intravitreal triamcinolone application, and 4.1% of the patients finished the study with a developed cataract.

Conclusion Intravitreally applied triamcinolone acetonide has a moderate and temporary influence on the velocity of vitreal hemorrhage reabsorption, probably by the mechanism of sedimentation of triamcinolone's crystals with blood elements. It can be a useful treatment option when vitrectomy is not possible.

Keywords: triamcinolone acetonide; vitreal hemorrhage; intravitreal injection; intraocular pressure

INTRODUCTION

Vitreal hemorrhage (VH) represents a significant complication of proliferative diabetic retinopathy which causes serious decrease of visual acuity [1]. There are many factors that distinguish VH from other hemorrhages: long-term survival of intact red blood cells, instant clot formation, slow fibrin lysis, inactivated early polymorphonuclear cellular response. It is known that VH has clearance of only 1% per day [2]. The accepted method for treatment of vitreous hemorrhage is pars plana vitrectomy [1].

Due to their anti-inflammatory and anti-angiogenic influences, corticosteroids are commonly used in treatment of different retinal disorders. As it is reported by many studies, triamcinolone acetonide applied intravitreally (IVTA) has shown an effect in the treatment of macular edema or proliferative diabetic retinopathy and proliferative vitreoretinopathy [3,

4, 5]. Serving as an adjuvant therapy, IVTA acts like a depot, releasing crystals into the vitreal cavity [5]. The effect of triamcinolone acetonide is the reduction of intra- and postoperative inflammation, vascular permeability and re-proliferation [6]. Triamcinolone acetonide can also be effective for rapid clearing of recurrent post-vitrectomy diabetic VH [6].

The study was conducted with the aim to evaluate the efficacy of 20 mg IVTA in the adjuvant treating of long-lasting VH, in patients with proliferative diabetic retinopathy in non-vitreotomized eyes. We measured the density of VH and recorded the influence that IVTA had on the visual acuity, cataract development, and the increase of intraocular pressure (IOP).

METHODS

The prospective, comparative study included two groups of patients. The first group (IVTA

Received • Примљено:

August 5, 2017

Revised • Ревизија:

May 25, 2017

Accepted • Прихваћено:

June 15, 2017

Online first: June 20, 2017

Correspondence to:

Dušan TODORVIĆ
Department of Ophthalmology
Faculty of Medical Sciences
University of Kragujevac
69 Svetozara Markovića Street
Kragujevac 34000
drdusantodorovic@yahoo.com

group) contained 24 patients with long-lasting VH of various density which occurred as a complication of proliferative diabetic retinopathy. They were recruited for intravitreal application of triamcinolone acetonide. The second group had 21 participants with proliferative diabetic retinopathy and with a similar degree of VH (control group). Sex and age were matched between the groups. The study was carried out between January 1, 2015 and January 1, 2016 at the Ophthalmology Clinic of the Kragujevac Clinical Centre, Serbia. With the approval of the institutional ethics committee and according to the tenets of the Declaration of Helsinki, all enrolled patients gave their written consent at the beginning of the investigation. All the patients from the first group were acquainted that this was an off-label use of triamcinolone acetonide and signed an informed consent.

The patients had passed a complete ophthalmological examination: visual acuity, intraocular pressure measurement, slit lamp, fundus examination, and ocular ultrasonography. These examinations were performed before the IVTA application, on visits after seven days, one month, three months, six, nine, and 12 months.

The degree of intravitreal hemorrhage was scaled according to the diabetic retinopathy vitrectomy study grading system (Table 1) [7]. In this study, we examined patients who received IVTA, by comparing the IVTA effect on VH resorption and visual acuity with the control group. The IOP rise and cataract development were also follow-up parameters as possible complications after ocular steroid administration [8].

Table 1. Diabetic retinopathy vitrectomy study grading system

Grade 0	No vitreous hemorrhage
Grade I	Mild vitreous hemorrhage with visible fundus details
Grade II	Moderate vitreous hemorrhage with no visible fundus details but with an orange fundus reflex
Grade III	Severe vitreous hemorrhage with no retinal details and no orange fundus reflex

Exclusion criteria for the patients were preexisting glaucoma, uveitis, myopia, ocular trauma, earlier intraocular surgery, cataract, and retinal detachment confirmed by ocular ultrasonography or fundoscopic examination. Patients with previous exposure to the topical, intraocular, or systemic steroids were also excluded. If any patients had developed some other complication of diabetic retinopathy during the period of the study, such as diabetic macular edema, they would have been excluded as well.

The intravitreal injection of 20 mg triamcinolone acetonide was given to all the patients in the operation theatre under sterile conditions. As we mentioned earlier, patients agreed to receive an off-label triamcinolone acetonide and signed an informed consent. Multiple sedimentation was performed to obtain a wanted dose of 20 mg of triamcinolone acetonide. The crystalline cortisone was adopted after aspirating a 1 mm bottle which contained about 40 mg of triamcinolone acetonide (Kenalog®, Bristol-Myers Squibb, New York City, NY, USA) into syringe of 1 mm. After leaving the syringe in the vertical position for

20 minutes, the first sedimentation was done. The upper, unsedimented part, was gently ejected through the syringe. Sedimented part, about 0.2 ml, was then mixed with Ringer's solution until the syringe was filled again. After five minutes in vertical position, unsedimented part, about 0.8 ml, was again eliminated from the syringe. This procedure was repeated once more. After this triple sedimentation, there was about 0.2 ml left in the syringe, with about 20 mg triamcinolone acetonide.

Periocular and ocular area were sterilized using 5% and 10% povidone iodine. Triamcinolone acetonide was injected into the central parts of the vitreal cavity. Under the topical anesthesia, using a 27 gauge needle, 3.5 mm from the limbus, triamcinolone acetonide was implemented. When the procedure was done, the patients remained in the upright position for the next two hours. Topical ciprofloxacin (Floxal®, DR. Gerhard Mann, Chem.-Pharm. Fabrik GmbH, Berlin, Germany) was prescribed five times per day, for the next seven days.

Statistical methods

IBM SPSS Statistics, Version 22.0 (IBM Corp., Armonk, NY, USA) was used for all calculations in the study. We used Friedman's test in testing the evolution of VH through the period of 12 months. For comparison of the variables, such as the IOP, visual acuity, or cataract development, Student's t-test was used. A value of $p < 0.05$ was accepted as statistically significant.

RESULTS

Examined patients from the first group had a mean age of 56.24 ± 5.5 years, while that of the control group members was 54.15 ± 4.8 years. No statistical significance was found among the patients' age ($p = 0.43$). In both groups female to male ratio was approximately equal.

Every patient passed a complete ophthalmological examination on every visit during the follow-up period (Figures 1, 2, and 3). According to the density of VH, examined patients were divided into four grades and statistically analyzed. Visual acuity was measured for every grade separately. Mean visual acuity in grade 0 was 0.9 ± 0.1 , in grade I it was 0.6 ± 0.17 . Grades II and III were characterized by an intensive decrease of visual acuity, 0.3 ± 0.15 and 0.03 ± 0.01 , respectively.

At the beginning of the research, in the IVTA group there were 0 patients with grade 0, seven with grade I, 10 with grade II, and seven patients with grade III of VH. The control group also had 0 patients with the grade 0, but six patients with grade I, nine patients with grade II, and six patients with the grade III. No statistical significance ($p = 0.99$) was found between the groups. At that time, none of the patients had the IOP over 21 mmHg or any signs of cataract development. Mean visual acuity in the first group was 0.30 ± 0.05 , while in the second group it was 0.31 ± 0.03 , without any statistically significant difference between the groups ($p = 0.68$).

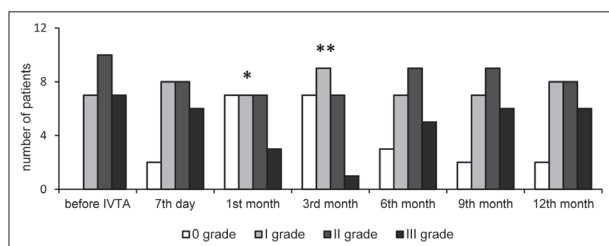


Figure 1. Grading the patients who received triamcinolone acetonide applied intravitreally (IVTA) during a period of one year

*p < 0.05
**p < 0.001

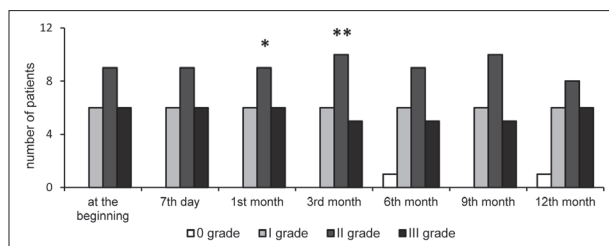


Figure 2. Grading the patients from the control group during a period of one year

*p < 0.05
**p < 0.001

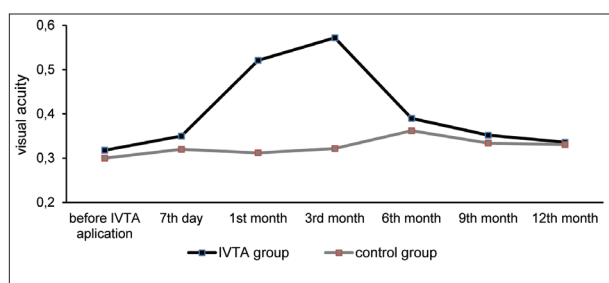


Figure 3. Comparison of visual acuity in patients who received triamcinolone acetonide and the patients from the control group

IVTA – triamcinolone acetonide applied intravitreally

Seven days after the IVTA application, no statistically significant differences were recorded in the density of VH ($p = 0.54$) and the visual acuity ($p = 0.08$).

At the third measurement, one month after the IVTA procedure, we detected a statistically significant difference for the first time. Twenty-one patients divided equally among the first three grades and only one patient with severe VH were detected in the IVTA group. Compared with the control group, where the patients were still in the same schedule as they were at the beginning of the study (grade 0 – zero, grade I – six, grade II – nine, grade III – six) statistical significance was noticed ($p = 0.04$). This was followed by an improvement of visual acuity to 0.51 ± 0.08 in the first group, while it remained the same in the second group, 0.34 ± 0.04 . Again, we recorded statistically significant difference, $p = 0.02$.

The statistically significant difference among the groups was captured three months after triamcinolone acetonide application, $p < 0.05$; $p < 0.001$. Both VH and visual acuity were much better in those who received triamcinolone ac-

etonide then in patients from the control group ($p = 0.01$; $p = 0.001$).

The last three measurements, six, nine, and 12 months after the administration of IVTA, passed without statistically significant differences ($p > 0.05$). VH and visual acuity were quite similar in both groups (Figures 1 and 3).

During this one-year study, the IOP measurements and detailed ophthalmological examinations were constantly performed. Three and six months after receiving triamcinolone acetonide, seven patients (29.1%) had a temporary IOP rise of over 5 mmHg in relation to the IOP values they had before the triamcinolone acetonide injection. They were efficiently treated by appropriate antiglaucomatous medications – dorzolamide/timolol eye drops (Cosopt®, Merck Sharp & Dohme, Kenilworth, NJ, USA) two times a day. One patient from the first group (4.1%) ended the study with the diagnosis of cataract. No endophthalmitis was recorded among those who underwent intravitreal application of triamcinolone acetonide.

DISCUSSION

The collagen fibrils and hyaluronic acid, contained inside the vitreal gel, are responsible for the integrity of the vitreal matrix. Fibrils are arranged as a fine network, with the glycosaminoglycans filling the gaps between them. When hemorrhage in the vitreal cavity occurs, the polymorphonuclear neutrophils and macrophages get activated to phagocytize erythrocytes [9]. Intact erythrocytes leave the eye through the trabecular meshwork. Related to the slow vitreal lyses of fibrin, because of low tissue fibrinolytic activity, elimination of the vitreal fibrin is also very slow [10]. Despite the fact that erythrocytes leave the eye through the trabecular meshwork, intact blood cells can be histologically detected in vitreal cavity many months after the incident. These erythrocytes provoke realizing of the macrophages' lysosomal enzymes, which decompose them by the process of the hemolysis. The velocity of VH reabsorption is approximately 1% per day [2]. The quantity of VH as well as its occurrence frequency and the level of communication of the anterior and posterior segment of the eye determine the clearance rate [11]. Vitrectomy has an important role in the process of the VH clearing. Based on the reachable data, cleared vitreal cavity, after vitrectomy, expedites reabsorption of the remaining erythrocytes [12].

Corticosteroids can be useful for the treatment of retinal vascular and inflammation disorders by inhibition of different genes expression responsible for the synthesis of different mediators of inflammation and angiogenesis [13]. Intravitreally applied triamcinolone acetonide due to its low water solubility and its sustained crystal releasing, has prolonged action duration [12].

The real mechanism of triamcinolone acetonide intravitreally applied on hemorrhage reabsorption is still not clear. Triamcinolone acetonide crystals deposit along the retinal vasculature, making them look like frosted angiitis [14]. These phenomena have certain effect on the VH

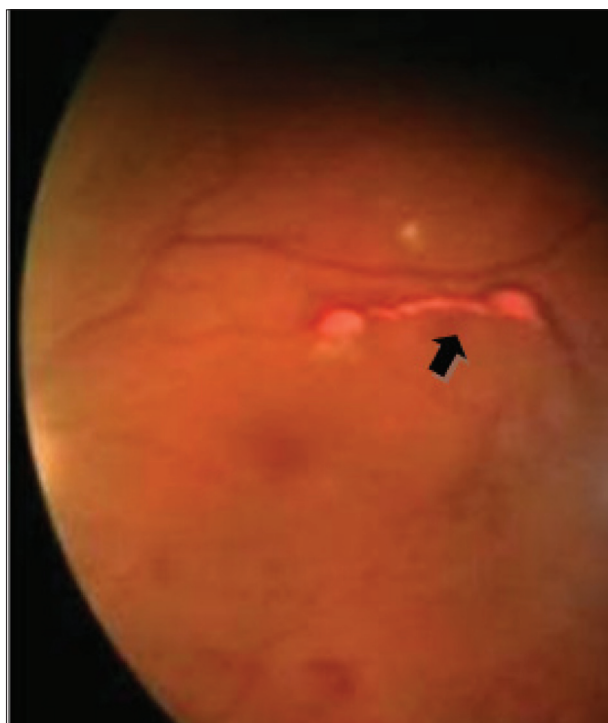


Figure 1. Crystals of triamcinolone acetonide spotted one month after the intravitreal application of 20 mg of triamcinolone acetonide

reabsorption. Despite the fact that posterior vitreous detachment can often be detected in these eyes, remnants of it persist along the retinal vasculature elements, and prolonged its action on the vascular elements [5]. By the mechanism of sedimentation of triamcinolone crystals with retinal blood elements and vascular stabilization, triamcinolone acetonide has its role in the cleaning of VH in patients with proliferative diabetic retinopathy [15]. Using detailed ophthalmoscopic examination, we managed to identify these crystals, stationed along the retinal vasculatures, one month after the application of intravitreal triamcinolone acetonide (Figure 4). According to our results,

the crystals remained in the vitreal cavity for three months, which is in correlation with the improvement of the density of VH, and consequently with better visual acuity. After this period, the crystals of triamcinolone acetonide were not noticed in the vitreal cavity, and the results were quite similar to the control group. Temporary rise of the IOP, which was recorded in some patients three to six months after triamcinolone acetonide injection, indicated that triamcinolone was still present in the eye, even it wasn't identified during the ophthalmological examination. That IOP rise was efficiently treated by locally applied medical therapy – antiglaucomatous eye drops, without unwanted influence on the optic nerve, which was confirmed at the next control examination, three months later. Some studies reported much longer duration after the application of 20 mg of triamcinolone intravitreally [16, 17]. Non-existence of the unique opinion among the scientists, of the mechanism and duration of IVTA provides new possibilities for future investigations.

CONCLUSION

Intravitreal application of the triamcinolone acetonide has a temporary and limited effect in the treatment of VH, followed by the transitory improvement of the visual acuity. Triamcinolone acetonide can serve as the alternative therapy for the diabetic patients with massive VH, in those cases where vitrectomy is not recommended. Existence of ocular comorbidities or contraindications for general anesthesia, such as abnormally high blood pressure, cardiopulmonary insufficiency, extreme obesity, senility, gives space for the use of intravitreal triamcinolone acetonide. By this treatment we improve the patients' quality of life for a while. Also, the intravitreal application can be repeated after a few months. Following the rules of sepsis and antisepsis, as well as the guide for secondary glaucoma treatment, complications of this intervention can be reduced.

REFERENCES

1. Spraul CW, Grossniklaus HE. Vitreous hemorrhage. *Surv Ophthalmol.* 1997; 42(1):32–9.
2. Aiello LP, Brucker AJ, Chang S, Cunningham Jr ET, D Amico DJ, Flynn Jr HW, et al. Evolving guidelines for intravitreal injections. *Retina.* 2004; 24:53–19.
3. Kriechbaum K, Prager S, Mylonas G, Scholda C, Rainer G, Funk M, et al. Intravitreal bevacizumab (Avastin) versus triamcinolone (Volon A) for treatment of diabetic macular edema: one-year results. *Eye (Lond).* 2014; 28(1):9–15.
4. Jonas JB, Hayler JK, Panda-Jonas S. Intravitreal injection of crystalline cortisone as adjunctive treatment of proliferative vitreoretinopathy. *Br J Ophthalmol.* 2000; 84(9):1064–7.
5. Spaide RF, Sorenson J, Maranan L. Photodynamic therapy with verteporfin combined with intravitreal injection of triamcinolone acetonide for choroidal neovascularization. *Ophthalmology.* 2005; 112(2):301–4.
6. Lee SY, Yoon YH, Lee HG, Chung H, Kim JG. Intravitreal triamcinolone acetonide in eyes with recurrent postvitrectomy diabetic vitreous hemorrhage. *Am J Ophthalmol.* 2006; 142(3):501–3.
7. Diabetic Retinopathy Vitrectomy Study (DRVS). Two-year course of visual acuity in severe proliferative diabetic retinopathy with conventional management. Report No 1. *Ophthalmology.* 1985; 92(4):492–502.
8. Nath Razeghinejad MR, Katz LJ. Steroid-induced iatrogenic glaucoma. *Ophthalmic Res.* 2012; 47(2):66–80.
9. Swann DA. On the integrity of vitreous structure, in Freeman HM, Hirose T, Schepens CL (eds): *Vitreous Surgery and Advances in Fundus Diagnosis and Treatment.* New York: Appleton-Century Crofts; 1977. p. 3
10. Cuevas P, Outeiriño LA, Azanza C, Angulo J, Giménez-Gallego G. Dramatic resolution of vitreous hemorrhage after an intravitreal injection of dobesilate. *Mil Med Res.* 2015; 2:23.
11. Agarwal D, Gelman R, Prospero Ponce C, Stevenson W, Christoforidis JB. The vitreomacular interface in diabetic retinopathy. *J Ophthalmol.* 2015; 2015:392983.
12. Steel DH, Connor A, Habib MS, Owen R. Entry site treatment to prevent late recurrent postoperative vitreous cavity haemorrhage after vitrectomy for proliferative diabetic retinopathy. *Br J Ophthalmol.* 2010; 94(9):1219–25.
13. Jonas JB, Kreissig I, Degenring RF. Neovascular glaucoma treated by intravitreal triamcinolone acetonide. *Acta Ophthalmol Scand.* 2003; 81(5):540–1.
14. Silva PS, Singh RJ, Bakri SJ, Lising RS, Santiago DE, Harvey S. Vitreous concentration of triamcinolone acetonide after a

- single transseptal depot injection. *Ocular Immunology and Inflammation*. 2009; 17(3):216–20.
15. Vedantham V, Kolluru C, Ramasamy K. Persistent depot of triamcinolone acetonide after a single intravitreal injection. *Indian J Ophthalmol*. 2005; 53(1):65–6.
 16. Wei Y, Wang HZ, Chen FH, Wang RS, Yang XG. Triamcinolone intravitreal injection and intraocular pressure in macular edema associated with retinal vein occlusion. *Eye Sci*. 2012; 27(4):182–7.
 17. Jonas JB. Intraocular availability of triamcinolone acetonide after intravitreal injection. *Am J Ophthalmol*. 2004; 137(3):560–2.

Утицај интравитреално апликованог триамцинолон-ацетонида на ресорпцију витреалне хеморагије и видну оштрину код болесника са пролиферативном дијабетесном ретинопатијом

Ненад Петровић^{1,2}, Душан Тодоровић¹, Сунчица Срећковић^{1,2}, Татјана Шаренац-Вуловић^{1,2}, Мирјана Јанићијевић-Петровић^{1,2}, Светлана Пауновић², Катарина Јанићијевић³, Светлана Јовановић^{1,2}

¹Универзитет у Крагујевцу, Факултет медицинских наука, Катедра за офталмологију, Крагујевац, Србија;

²Клинички центар Крагујевац, Клиника за офталмологију, Крагујевац, Србија;

³Универзитет у Крагујевцу, Факултет медицинских наука, Катедра за социјалну медицину, Србија

САЖЕТАК

Увод/Циљ Витреална хеморагија (ВХ) једна је од могућих компликација дијабетесне ретинопатије, која је праћена интензивним падом видне оштрине. Кортикостероиди се учестало користе у лечењу различитих ретиналних обољења, захваљујући свом антиинфламаторном и антиангиогенетском ефекту. Триамцинолон-ацетонид апликован интравитреално задржава се у оку неколико месеци, отпушта своје кристале и смањује густину ВХ.

Циљ ове студије је да процени ефикасност 20 милиграма интравитреално апликованог триамцинолон-ацетонида у третману дуготрајне ВХ као компликације пролиферативне дијабетесне ретинопатије (ПДР) код невитрекомисаних очију.

Метод У проспективној студији, у 2015. години, упоређена су 24 болесника са ВХ и интравитреално апликованим триамцинолон-ацетонидом са 21 болесником из контролне групе (болесници са ПДР и сличним степеном ВХ). Сви болес-

ници су имали комплетан офталмолошки преглед на почетку студије, 7 дана, 1, 3, 6, 9 и 12 месеци после интравитреалне апликације 20 милиграма триамцинолон-ацетонида. Поред ВХ и видне оштрине, анализирани су и интраокуларни притисак и развој катаракте.

Резултати Статистички значајна разлика у густини ВХ и видној оштрини забележена је 1. и 3. месеца после употребе триамцинолона. Код 29% болесника забележен је привремен скок интраокуларног притиска после интравитреалне примене триамцинолона, а 4,1% болесника завршило је студију са развијеном катарактом.

Закључак Интравитреално апликован триамцинолон-ацетонид има умерен и привремен ефекат на брзину ре-апсорпције ВХ. То може представљати корисну терапијску могућност када витректомија није могућа.

Кључне речи: триамцинолон-ацетонид; витреална хеморагија; интравитреална инјекција; интраокуларни притисак