

CASE REPORT / ПРИКАЗ БОЛЕСНИКА

Approach to the wide QRS-complex tachycardia

Miloje Tomašević^{1,2}, Srđan Aleksandrić¹, Jelena Rakočević^{3,4}, Vladimir Miloradović^{2,5}, Miodrag Srećković^{2,5}

¹Clinical Center of Serbia, Division of Cardiology, Belgrade, Serbia;

²University of Kragujevac, Faculty of Medical Sciences, Kragujevac, Serbia;

³Institute of Histology and Embryology, Belgrade, Serbia;

⁴University of Belgrade, Faculty of Medicine, Belgrade, Serbia;

⁵Kragujevac Clinical center, Department of Internal Medicine, Kragujevac, Serbia



SUMMARY

Introduction Patients presenting with tachycardia most often complain of palpitation and dizziness, but can also report episodes of chest pain due to increased myocardial oxygen demand.

The aim of this case article was to emphasize the importance of differential diagnosis between different types of supraventricular (SVT) or ventricular tachycardia (VT) according to ECG findings, and highlight the treatment algorithm for wide QRS-complex tachycardia.

Case Outline We present a 34-years old female patient which was admitted to our hospital due to palpitations and chest pain that occurred at rest about two hours before hospital admission. Cardiac auscultation showed the presence of irregular heartbeats with tachycardia, whereas arterial blood pressure was 100/60 mmHg. Initial ECG recording demonstrated wide complex tachycardia (WCT) with irregular heart rate of approximately 180 beats per minute with right bundle branch block-like morphology of QRS complexes. After administration of intravenous amiodarone, patient was converted to sinus rhythm, with short PR interval (< 120 ms) and narrow QRS complexes (< 120 ms) with visible delta waves, indicating the presence of Wolff–Parkinson–White syndrome type A as the underlying cause of atrial fibrillation with right bundle branch block-like morphology of QRS complexes.

Conclusion The ability to differentiate between VT and SVT with a wide QRS complex due to aberrant intraventricular conduction or preexcitation is critical because the treatment of each is different, and inadequate therapy may potentially have lethal consequences.

Keywords: wide complex tachycardia; ventricular tachycardia; supraventricular tachycardia conducted with aberrancy; Wolff–Parkinson–White syndrome; antidromic atrioventricular reentry tachycardia; atrial fibrillation

INTRODUCTION

Patients presenting with tachycardia most often complain of palpitation and dizziness, but can also present with episodes of chest pain due to rapid heart rate inducing increased myocardial oxygen demand. The most important step in the diagnosis of tachycardia is to delineate narrow from wide complex tachycardia (WCT). Narrow complex tachycardia is tachycardia with QRS complexes < 120 ms which means that the depolarization of ventricles occurs normally through His-Purkinje network with electrical impulses that arise from above atrioventricular (AV) junction sinoatrial node, right or left atrium), and pass forward through the AV node [1]. This pattern of supraventricular tachycardia (SVT) is further divided into atrial or atrioventricular, regular or irregular (Table 1). WCT is tachycardia with wide QRS complexes (> 120 ms) which means that the depolarization of ventricles occurs via the myocardium rather than conductive system of the heart [1]. It reflects ventricular tachycardia (VT) or SVT with aberrant ventricular conduction meaning that supraventricular electrical impulses do not pass through the AV node and His-Purkinje network

toward ventricles [2, 3]. The latter may be due to: (1) aberrant intraventricular conduction caused by a bundle branch block (BBB) that may be fixed or rate-dependent, or (2) antero-grade conduction over an accessory AV pathway caused by Wolff–Parkinson–White (WPW) syndrome, which is much less common [2, 3]. ECG findings of SVT with aberrant ventricular conduction are similar with VT, therefore, it is called pseudo-ventricular tachycardia.

WPW syndrome represents a congenital condition where accessory AV pathway (known

Table 1. Classification of supraventricular tachycardias by site of origin and regularity

	Regular	Irregular
Atrial	<ul style="list-style-type: none"> • Sinus tachycardia • Atrial tachycardia • Atrial flutter • Sinus nodal reentrant tachycardia (SNRT) 	<ul style="list-style-type: none"> • Atrial fibrillation (AF) • Atrial flutter with variable block • Multifocal atrial tachycardia (MAT)
Atrioventricular (AV)	<ul style="list-style-type: none"> • Av re-entry tachycardia (AVRT) • AV nodal re-entry tachycardia (AVNRT) • Paroxysmal junctional reentry tachycardia 	

Received • Примљено:

January 8, 2018

Revised • Ревизија:

March 7, 2018

Accepted • Прихваћено:

March 9, 2018

Online first: March 13, 2018

Correspondence to:

Srđan ALEKSANDRIĆ
Division of Cardiology
University Clinical Center of Serbia
11000 Belgrade, Serbia
srdjanaleksandric@yahoo.com

as the bundle of Kent) leads to ventricular preexcitation and frequent occurrence of paroxysmal SVT and possible VT [4, 5]. The estimated overall incidence of WPW syndrome is between 0.1–0.3% in otherwise healthy persons [6–9], while clinical presentation can be quite variable: from asymptomatic cases accidentally discovered after a routine ECG, to sudden cardiac arrest as a first presentation of WPW syndrome [5, 10]. Here, we present a case of a young adult female patient admitted to our hospital due to chest pain and palpitations, with wide QRS-complex tachycardia that was caused by underlying WPW syndrome.

CASE REPORT

A 34-year-old woman was admitted to our hospital complaining of chest pain which started approximately two hours before the admission at rest and without obvious precipitating events. Pain was located in the middle of the chest without radiation, and was accompanied by palpitations. Patient had no prior history of cardiovascular disease, but she reported family history of cardiovascular disease and hypercholesterolemia. On examination the patient was conscious, fully oriented, eupneic, acyanotic, with external jugular veins appeared to be non-distended. Arterial blood pressure was 100/60 mmHg, cardiac auscultation demonstrated tachycardia with irregular heartbeats, silent heart sounds without heart murmurs. Pulmonary auscultation showed normal pulmonary sound. Before hospital admission, emergency medical service administered 300 mg aspirin orally. Initially recorded 12-lead ECG showed following changes which indicated that the patient had WCT with irregular heart rate of approximately 180 beats per minute and right bundle branch block (RBBB)-like morphology of QRS complexes (Figure 1).

The patient was treated with intravenous amiodarone (300 mg intravenous amiodarone as bolus injections, followed by intravenous infusion of 300 mg amiodarone in 200 mL of 5% glucose solution), accompanied by 5000 IU of unfractionated heparin intravenously. ECG was recorded again (Figure 2), showing the presence of WPW syndrome (short PR interval and delta waves as a slurred upstroke in the QRS complex). Control arterial blood pressure was 120/80 mmHg.

DISCUSSION

The main issue in the presented case was whether this was a VT or SVT with aberrant ventricular conduction (pseudo-ventricular tachycardia). Therefore, we used the Brugada criteria algorithm which has sensitivity of 98.7% and specificity of 96.5% in distinguishing VT from SVT conducted with aberrancy, that included 4 sequential questions: (1) *Is there an absence of RS complexes in all precordial leads?* (2) *Is R to S interval > 100 ms in one precordial lead?* (3) *Is there AV dissociation?* (4) *Is there morphology criteria for VT present in precordial leads V1/V2 and V6?*

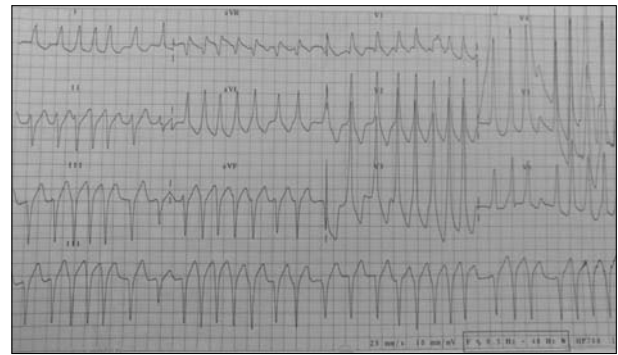


Figure 1. Initial electrocardiogram showing wide QRS-complex tachycardia with RBBB-like morphology of QRS complexes. There are two major features: (1) wide QRS complexes (> 120 ms) with RBBB-like morphology, and (2) irregular ventricular rate, recognized by unequal R-R intervals on ECG. Note that the QRS complex morphology was not typical for RBBB (explanation is in the text). Although there is qR configuration in lead V1, notched downslope to R wave in the same lead is absent, and R/S ratio in lead V6 is > 1, which exclude VT according to Brugada criteria for differentiating between SVT with aberrancy and VT. However, it is unclear whether it is SVT with aberrant intraventricular conduction or SVT with anterograde conduction over an accessory AV pathway in WPW syndrome (pre-excited SVT);

RBBB – right bundle branch block; VT – ventricular tachycardia; SVT – supra-ventricular tachycardia

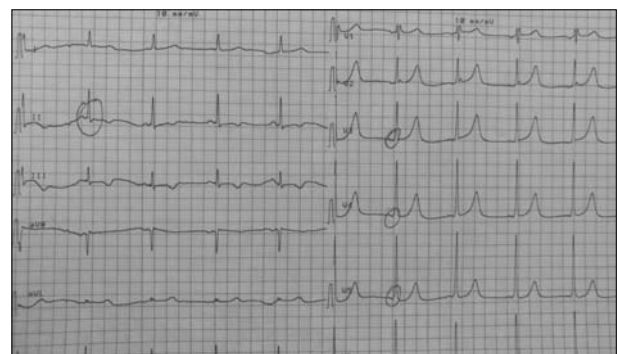

Figure 2. Electrocardiogram findings after amiodarone administration show characteristic signs of WPW syndrome: sinus rhythm with regular ventricular rate of 60 bpm, short PR interval (< 120 ms), widened QRS complexes (100 ms) with RSR' configuration in lead V1, ST depression and negative T wave in leads D2, D3, aVF, delta wave as a slurred upstroke in the initial portion of QRS complex, prolonged QTc interval (Bazzet's formula) = 471 ms

[11] Registering one of these ECG features is highly suggestive of VT.

In our patient qR configuration was present in at least one precordial lead (V1), while S waves were not observed in any of precordial leads, and therefore we could not measure RS interval. Also, we could not find P wave in any lead in this case. Irregular heart rate at approximately 180 bpm suggests that there was no AV block gradus 3, but we could not exclude AV dissociation with interference for certain. One of the major ECG features in our patient was a wide spectrum of QRS complexes (> 120 ms) with RBBB-like morphology. However, QRS complex morphology was not typical for RBBB, although there was wide QRS complex present with high amplitude of the R wave, and ST segment depression and T wave inversion in right precordial leads (V1–V2), but lacking deep S waves in the left precordial leads (D1, aVL, V5, V6). Although there

was a qR configuration in lead V1, notched downslope to R wave in the same lead was absent, and R/S ratio in lead V6 was > 1 . Additionally, there were no Brugada signs for VT in RBBB pattern such as monophasic R or biphasic qR complex in lead V1, RSR' pattern ("bunny-ear") in lead V1 with the R peak being higher in amplitude than the R' peak, and rS complex in lead V6. Therefore, according to Brugada criteria we excluded VT with high certainty. Additionally, irregular ventricular rate and a newer criterion to differentiate VT from SVT in WCTs – R wave peak time in lead D2 is < 50 ms [12], also suggest that VT probability was not present.

Differential diagnoses in this case also include SVT with irregular ventricular rate such as atrial fibrillation (AF) or multifocal atrial tachycardia (MAT), both associated with RBBB. AF is characterized by the rapid and irregular contractions (trembling) of the atria at rates of 350 to 600 bpm. This "reentry" arrhythmia originates from the random and unpredictable activation of numerous reentry circuits, often localized in the left atrial myocardium near the pulmonary vein confluence. However, since AV node cannot conduct all present atrial electrical impulses to ventricles, it results in slower ventricular response rate with normal QRS complex morphology [13]. Similar to AF, MAT also represents a form of reentry arrhythmia, with irregular ventricular rate > 100 bpm and narrow QRS complexes on ECG recordings. The main difference represents P-wave morphology; patients with MAT always have P-waves on ECG preceding every QRS complex [13, 14]. Also, P-waves in MAT are always present in leads D2, D3, and aVF, but with different morphology, since this arrhythmia is caused by a random activation of multiple different atrial foci [13, 14]. On the other hand, patients with AF usually show the absence of P-waves, or numerous, irregular, small waves, so-called "f" waves [14]. Our ECG findings suggest the presence of AF. However, it is unclear whether AF is associated with fixed or rate-dependent RBBB or whether it is due to anterograde conduction over an accessory AV pathway in WPW syndrome reflecting pre-excited SVT.

The most common cause of WCT is VT which accounts for up to 80% of the cases, therefore the general approach in WCT of unknown etiology is to consider it as VT until proven otherwise [2, 3, 15]. The initial approach to the management of WCT depends primarily on the patient's clinical and hemodynamic status [3, 15]. Unstable patients should be promptly treated with synchronized cardioversion (100–200 J of monophasic current, or 50–100 J of biphasic current) including prior sedation [3, 15]. Advanced cardiac life support algorithms should dictate the therapeutic approach if the patient becomes pulseless and VT degenerates into ventricular fibrillation [3, 15, 16].

In our case, the patient was treated with intravenous amiodarone, which is the drug of choice in the cases of WCT of unknown etiology in hemodynamically stable patients, because it can terminate both VT and SVT [15, 16]. Simultaneously, unfractionated heparin was administered to prevent cerebral thromboembolism, since it is known that those who have AF are five times more likely to suffer from stroke, regardless of the type of AF [17].

Antiarrhythmic agents that block conduction through the AV node such as calcium-channel blockers, beta-blockers, adenosine and digoxin should be avoided in the pharmacological management of WCT of unknown etiology, especially irregular WCT. This arrhythmia can be associated with WPW syndrome, where the administration of these AV nodal blocking agents facilitate conduction via accessory AV pathway, which is especially dangerous if AF and WPW syndrome coexist [15, 16]. In addition, these agents shorten the effective refractory period of accessory AV pathway and thus may cause deterioration into ventricular fibrillation (VF), as a ventricular response to fast or chaotic atrial rates [15]. This may lead to severe hypotension, hemodynamic collapse and cardiac arrest, and therefore, AV nodal blocking agents are contraindicated in arrhythmias associated with WPW syndrome [3, 15].

Instead of amiodarone, procinamide and propafenone can be administered intravenously as the initial treatment of hemodynamically stable patients with WCT. If administration of antiarrhythmic agents class I or III prove to be unsuccessful, synchronized cardioversion should be performed with prior sedation.

The underlying mechanism for WCT with irregular ventricular beat and RBBB-like morphology of QRS complexes in our case was WPW syndrome. In this pre-excitation syndrome ventricles are activated earlier due to congenital accessory AV pathway (bundle of Kent) that directly connects atria and ventricles. Therefore, electrical impulses are transmitted through this accessory bundle, bypassing the AV node where normal delay of electrical impulses derived from atria occurs, causing premature ventricular contractions. Classical ECG finding includes short PR interval (< 120 ms) and delta wave at the beginning of QRS complex, seen as a slow rise in the initial upstroke of the QRS complex. Electrical impulses and subsequent ventricular activation are not spread through normal His-Purkinje conduction system, but directly through the myocardium, which is presented on ECG as widened QRS complex (> 100 ms). ECG features also include ST segment depression and negative T-wave, which can sometimes be misinterpreted as myocardial ischemia. Corrected QT interval (QTc), which is usually calculated using Basset's formula, is pathologically prolonged (> 450 ms in men, > 470 ms in women) [18]. There are two basic types of WPW syndrome: type A and type B. WPW pattern type A is more common, where the bundle of Kent directly connects left atrium with left ventricle. That is why the posterobasal part of left ventricle is the first to be activated, with higher R wave amplitude in leads V1 and V2, where QRS complex resembles RBBB-like morphology. Delta wave is positive in these leads, as well as in the other precordial leads where the R/S ratio is > 1 [19]. WPW syndrome type B is less frequent, where bundle of Kent directly connects right atrium with right ventricle. In these cases, posterobasal part of the right ventricle is the first one activated, leading to higher S wave amplitude in V1 and V2, with QRS having LBBB-like appearance. Delta wave is negative in these leads, while showing positivity in other precordial leads where the R/S ratio is > 1 [20]. According to our patient's ECG recordings,

we assume that this was the case of WPW syndrome type A. R wave showed higher amplitude in leads V1 and V2 (especially in V2), resembling incomplete RBBB-like morphology of QRS complexes due to normal width (< 120 ms) without higher amplitude of S wave in left precordial leads (D1, aVL, V5, V6). ECG showed positive delta waves in all precordial leads.

Clinical significance of WPW syndrome is in a frequent occurrence of paroxysmal SVT, atrial flutter and AF. These arrhythmias develop due to reentry circuits at the atrial and ventricular level which include the bundle of Kent. That is why this type of SVT is called atrioventricular reentry tachycardia (AVRT). Depending on the direction of electrical impulses, there are two types of AVRT: orthodromic and antidromic AVRT. Patients with orthodromic AVRT exhibit narrow QRS complexes (< 120 ms) with no visible delta waves. P waves are usually hidden within QRS complexes, but when visible, they show retrograde morphology (negative P waves in inferior and precordial leads). Orthodromic AVRT originates when electrical impulses are conducted normally, anterograde from atria through the AV node and other parts of conductive system to ventricles, but return from ventricle to atrium retrograde via the bundle of Kent. Contrary, patients with antidromic AVRT have wide QRS complexes (> 120 ms) and visible delta waves. This type of AVRT develops when electrical impulses are conducted anterograde from atria to ventricles through the bundle of Kent, with retrograde conduction from ventricles to atria via AV node. Antidromic AVRT is sometimes hardly distinguished from VT [21].

Taking into account all of the above, we concluded that our patients had WPW syndrome type A which was complicated with AF due to antidromic conduction of supraventricular electrical impulses via left-sided accessory bundle of Kent that in this case connects left atrium with left ventricle. It means that supraventricular impulses were

conducted anterograde from atria to ventricles through this accessory pathway, with retrograde conduction from ventricles to atria via AV node, forming reentry circuit. After sinus rhythm was restored, our patient required further diagnostic evaluation to detect possible causes of WPW syndrome, such as hypertrophic cardiomyopathy, mitral valve prolapse, or Ebstein anomaly. Although in more than 90% of cases, WPW syndrome occurs in patients with structurally normal heart, the long-term treatment for WPW syndrome is radiofrequency ablation of the bundle of Kent [22].

CONCLUSION

The initial ECG evaluation of every tachyarrhythmia should begin by addressing the question of whether the QRS complex is narrow (< 120 ms) or wide (> 120 ms). Usually, a narrow QRS complex indicates SVT, while any WCT of unknown etiology should be managed as if it is VT, until proven otherwise, keeping in mind the sentence "First, do no harm." Except for VT, the other causes of WCT are SVT with aberrant intraventricular conduction caused by a fixed or rate-dependent BBB, and SVT with anterograde conduction over an accessory AV pathway caused by WPW syndrome. The ability to differentiate between VT and SVT with a wide QRS complex due to aberrant intraventricular conduction or preexcitation is critical because the treatment of each is different, and wrong therapy may potentially have lethal consequences. The antiarrhythmic agents class IA, IC, and especially class III, are drugs of choice for the treatment of WCT of unknown etiology in hemodynamically stable patients, while AV nodal blocking agents should be avoided in these arrhythmias, especially in those associated with WPW syndrome.

REFERENCES

- Mann DL, Zipes DP, Libby P, Bonow RO. Braunwald's Heart Disease: A Textbook of Cardiovascular Medicine. 10th ed. Philadelphia: Elsevier/Saunders; 2014.
- Vereckei A. Current Algorithms for the Diagnosis of wide QRS Complex Tachycardias. *Curr Cardiol Rev.* 2014; 10(3):262–76.
- Goldberger ZD, Rho RW, Page RL. Approach to the diagnosis and initial management of the stable adult patient with a wide complex tachycardia. *Am J Cardiol.* 2008; 101(10):1456–66.
- Dreifus LS, Haiat R, Watanabe Y, Arriaga J, Reitman N. Ventricular fibrillation. A possible mechanism of sudden death in patients and Wolff-Parkinson-White syndrome. *Circulation.* 1971; 43(4):520–7.
- Olen MM, Baysa SJ, Rossi A, Kanter RJ, Fishberger SB. Wolff-Parkinson-White syndrome: a stepwise deterioration to sudden death. *Circulation.* 2016; 133(1):105–6.
- Newman BJ, Donoso E, Friedberg CK. Arrhythmias in the Wolff-Parkinson-White syndrome. *Prog Cardiovasc Dis.* 1966; 9:147–65.
- Berkman NL, Lamb LE. The Wolff-Parkinson-White electrocardiogram. A follow-up study of five to twenty-eight years. *N Engl J Med.* 1968; 278(9):492–4.
- Munger TM, Packer DL, Hammill SC, Feldman BJ, Bailey KR, Ballard DJ, et al. A population study of the natural history of Wolff-Parkinson-White syndrome in Olmsted County, Minnesota, 1953–1989. *Circulation.* 1993; 87(3):866–73.
- De Bacquer D, De Backer G, Kornitzer M. Prevalences of ECG findings in large population based samples of men and women. *Heart.* 2000; 84(6):625–33.
- Benson DW, Cohen MI. Wolff-Parkinson-White syndrome: lessons learnt and lessons remaining. *Cardiol Young.* 2017; 27(S1):S62–7.
- Brugada P, Brugada J, Mont L, Smeets J, Andries EW. A new approach to the differential diagnosis of a regular tachycardia with a wide QRS complex. *Circulation.* 1991; 83(5):1649–59.
- Pava LF, Perafán P, Badiel M, Arango JJ, Mont L, Morillo CA, et al. R-wave peak time at DII: a new criterion for differentiating between wide complex QRS tachycardias. *Heart Rhythm.* 2010; 7(7):922–6.
- Iwasaki Y, Nishida K, Kato T, Nattel S. Atrial fibrillation pathophysiology: implications for management. *Circulation.* 2011; 124(20):2264–74.
- Leonelli F, Bagliani G, Boriani G, Padeletti L. Arrhythmias Originating in the Atria. *Card Electrophysiol Clin.* 2017; 9(3):383–409.
- Garmel GS. Wide Complex Tachycardias: Understanding this Complex Condition. *West J Emerg Med.* 2008; 9(2):97–103.
- Neumar RW, Shuster M, Callaway CW, Gent LM, Atkins DL, Bhanji F, et al. Part 1: Executive Summary: 2015 American Heart Association Guidelines Update for Cardiopulmonary Resuscitation and Emergency Cardiovascular Care. *Circulation.* 2015; 132(18 Suppl 2):S315–67.

17. Son MK, Lim NK, Kim HW, Park HY. Risk of ischemic stroke after atrial fibrillation diagnosis: A national sample cohort. PLOS ONE. 2017; 12(6):e0179687.
18. Bhatia A, Sra J, Akhtar M. Preexcitation Syndromes. Curr Probl Cardiol. 2016; 41(3):99–137.
19. Fontaine G, Frank R, Coutte R, Vedel J-P null, Grosogoeat Y. Antidromic reciprocal rhythm in a type A Wolff-Parkinson-White syndrome. Ann Cardiol Angeiol (Paris). 1975; 24(1):59–66.
20. Lim CH, Toh CC, Chia BL. Ventricular fibrillation in type B Wolff-Parkinson-White syndrome. Aust N Z J Med. 1974; 4:515–7.
21. Almendral J, Castellanos E, Ortiz M. Update: Arrhythmias (V). Paroxysmal supraventricular tachycardias and preexcitation syndromes. Rev Esp Cardiol (Engl Ed). 2012; 65(5):456–69.
22. Page RL, Joglar JA, Caldwell MA, Calkins H, Conti JB, Deal BJ, et al. 2015 ACC/AHA/HRS Guideline for the Management of Adult Patients With Supraventricular Tachycardia: A Report of the American College of Cardiology/American Heart Association Task Force on Clinical Practice Guidelines and the Heart Rhythm Society. J Am Coll Cardiol. 2016; 67(13):e27–115.

Приступ тахикардији широких QRS комплекса

Милоје Томашевић^{1,2}, Срђан Александрић¹, Јелена Ракочевић^{3,4}, Владимир Милорадовић^{2,5}, Миодраг Срећковић^{2,5}

¹Клинички центар Србије, Клиника за кардиологију, Београд, Србија;

²Универзитет у Крагујевцу, Факултет медицинских наука, Крагујевац, Србија;

³Институт за хистологију и ембриологију, Београд, Србија;

⁴Универзитет у Београду, Медицински факултет, Београд, Србија;

⁵Клинички центар Крагујевац, Клиника за кардиологију, Крагујевац, Србија

САЖЕТАК

Увод Болесници са тахикардијом најчешће се жале на палпитације и вртоглавицу, али могу имати и епизоде болова у грудима због повећане потражње миокарда за кисеоником. Циљ овог рада је био да нагласи важност диференцијалне дијагнозе између различитих типова суправентрикуларне (СВТ) и/или вентрикуларне тахикардије (ВТ) према налазима ЕКГ-а и истиче алгоритам лечења тахикардије широких QRS комплекса.

Приказ болесника Приказујемо болесницу стару 34 године са палпитацијама и боловима у грудима, који су почели док се одмарала, око два сата пре пријема у болницу. Аускултаторни налаз на срцу указао је на присуство неправилних откуцаја са тахикардијом, док је артеријски крвни притисак био 100/60 mmHg. Иницијални ЕКГ је регистровао тахикардију широких комплекса, ирегуларног ритма, срчане фреквенције око 180 откуцаја у минути и QRS комплекс

са морфологијом блока десне гране. После интравенозне примене амиодарона, ритам је конвертован у синусни са кратким PR интервалом (< 120 ms), уским QRS комплексима (< 120 ms) и са видљивим делта таласима, што указује на синдром *Wolff-Parkinson-White* тип А као основни узрок атријалне фибрилације, са морфологијом QRS комплекса налик блоку десне гране.

Закључак Способност диференцирања између ВТ и СВТ са широким QRS комплексом због аберантне интравентрикуларне проводљивости или преекцитације је критична, јер је начин лечења различит, а неадекватна терапија може имати смртоносне последице.

Кључне речи: тахикардија широких QRS комплекса; вентрикуларна тахикардија; суправентрикуларна тахикардија са аберантним спровођењем; синдром *Wolff-Parkinson-White*; антидромна атриовентрикуларна *reentry* тахикардија; атријална фибрилација