



## Bisphosphonate related osteonecrosis of the maxilla – A case report

### Bisfosfonatima uzrokovana osteonekroza gornje vilice

Aleksandar Kiralj\*<sup>†</sup>, Slobodan Lončarević\*<sup>§</sup>, Ivana Mijatov\*<sup>†</sup>

Clinical Center of Vojvodina, \*Clinic for Maxillofacial and Oral Surgery, Novi Sad, Serbia; Univeristy of Novi Sad, <sup>†</sup>Faculty of Medicine, Novi Sad, Serbia; Military Medical Academy, <sup>‡</sup>Clinic for Maxillofacial, Oral Surgery and Implantology, Belgrade, Serbia; University of Kragujevac, <sup>§</sup>Faculty of Medical Sciences, Kragujevac, Serbia

#### Abstract

**Introduction.** Bisphosphonates are a group of medications which have an important role in the treatment of some bone diseases. Bisphosphonate-related osteonecrosis of the jaw (BRONJ) is a side effect of intravenous bisphosphonate therapy. The mechanism of action by which they may cause osteonecrosis is questionable. BRONJ is defined by the American Association of Oral and Maxillofacial Surgeons (AAOMS) and classified into four stages (0-3). Treatment of BRONJ depends on the stage of disease and includes conservative treatment (stage 0 and 1) and surgical treatment (surgical debridement in stage 2 and sequestrectomy in stage 3). **Case report.** We presented a patient who had breast cancer, with stage 3 of bisphosphonate-related osteonecrosis of the upper jaw after zoledronic acid therapy for diffuse metastasis of the vertebrae. Before the treatment with zoledronic acid the patient was treated by a dentist. The osteonecrosis of the upper jaw started a year and a half after the start of zoledronic acid therapy and after tooth 24 extraction. She was treated by an oral surgeon at the beginning according to the protocol of AAOMS. The patient was sent to a maxillofacial surgeon due to the disease progression, and after computed tomography (CT) examination resection of the upper jaw was done. **Conclusion.** BRONJ is a condition with the specific clinical presentation, and it can be very serious for the patient, therefore it is necessary to emphasize the importance of screening. The doctors in different specialties (oncologist, dentist, oral surgeon and maxillofacial surgeon) must cooperate and control the patients under treatment with bisphosphonates before the therapy starts, as well as during and after it, in order to prevent, recognize on time and treat properly this complication.

#### Key words:

bisphosphonate-associated osteonecrosis of the jaws; diagnosis; drug therapy; oral surgical procedures; treatment outcome.

#### Apstrakt

**Uvod.** Bisfosfonati spadaju u grupu lekova koja ima značajno mesto u lečenju nekih bolesti kostiju. Bisfosfonatima uzrokovana osteonekroza vilica (BRONJ) je retka komplikacija intravenske bisfosfonatne terapije. Mehanizam kojim bisfosfonati uzrokuju osteonekrozu još uvek nije u potpunosti razjašnjen. BRONJ je definisan od strane Američkog udruženja maksilofacijalnih i oralnih hirurga (AAOMC) i klasifikovan u četiri stadijuma (0-3). Tretman zavisi od stadijuma bolesti i podrazumeva konzervativni tretman (u stadijumima 0 i 1), hirurški debridman (u stadijumu 2) i sekvestrektomiju (u stadijumu 3). **Prikaz bolesnika.** U radu je prikazana bolesnica kojoj je operisan karcinom dojke, u fazi 3 BRONJ-a gornje vilice nakon terapije zolendroičnom kiselinom zbog difuznih metastaza na kičmenim pršljenovima. Pre početka terapije bisfosfonatima bolesnica je bila podvrgnuta stomatološkom tretmanu. Osteonekroza gornje vilice počela je godinu i po dana nakon početka terapije bisfosfonatima, a nakon ekstrakcije zuba 24. Bolesnica je na početku bila lečena od strane oralnog hirurga prema protokolu AAOMS. Zbog dalje progresije bolesti bolesnica je upućena maksilofacijalnom hirurgu. Nakon sprovedene dijagnostike kompjuterizovanom tomografijom, isplanirana je resekcija gornje vilice. **Zaključak.** BRONJ je stanje sa specifičnom kliničkom slikom, koje može imati ozbiljne posledice za bolesnike zbog čega se mora istaći značaj *screening*-a. Lekari različitih specijalnosti (onkolog, stomatolog, oralni i maksilofacijalni hirurg) moraju sarađivati i kontrolisati bolesnike koji su na terapiji bisfosfonatima, kako pre, tako tokom i nakon terapije, u cilju sprečavanja, blagovremenog prepoznavanja i pravilnog lečenja ove komplikacije.

#### Ključne reči:

osteonekroza vilica, uzrokovana bisfosfonatima; dijagnoza; lečenje lekovima; hirurgija, oralna, procedure; lečenje, ishod.

## Introduction

Bisphosphonates are a group of antiresorptive medications that act specifically on osteoclasts. They have an important role in maintaining bone density and strength in some bone diseases (osteoporosis, Paget's disease, multiple myeloma, bone metastasis of a malignant tumor). Bisphosphonate-related osteonecrosis of the jaw (BRONJ) presents avascular osteonecrosis of the jaw. It was first time described in 2003 by Marx<sup>1</sup> who reported series of 36 cases of BRONJ in patients with malignant tumors and later in 2004 Ruggiero et al.<sup>2</sup> described series of 63 cases in which most of the patients were cancer patients. Case studies and reviews have been reported since, and treatment guidelines have been published.

The mechanism of action by which bisphosphonates may cause osteonecrosis of the jaw is questionable: it can include bisphosphonate-related apoptosis of osteoclasts, antiangiogenic effect and toxic effect. It is considered that the bone remodeling is depressed, which is the cause of poor healing of post-extraction wounds<sup>3</sup>. Some authors consider that other cancer therapies medications (steroids, chemotherapeutic agents) can influence the development of BRONJ. The global incidence of BRONJ is 0.94%<sup>3,4</sup>.

The American Association of Oral and Maxillofacial Surgeons (AAOMS) defined BRONJ and it is considered that the patient has BRONJ if following characteristics are present<sup>5</sup>: current or previous treatment with antiresorptive or antiangiogenic agents; exposed bone or bone that can be probed through an intraoral or extraoral fistula in maxillofacial region that persists more than 8 weeks; no history of radiation therapy to the jaws or obvious metastatic disease to the jaws.

The categorization of BRONJ into 4 stages (0-III) was accepted in 2009<sup>5</sup>: Stage 0 – (none-exposed bone). In this stage, patients have no clinical evidence of necrotic bone but have symptoms like: odontalgia nonodontogenic origin, pain in the body of the mandible or in maxillary sinus, and disturbance of neurosensory function. Clinical findings include: loosening of teeth not caused by chronic periodontal disease and periapical fistula not associated with pulpal necrosis. Radiologically alveolar bone loss or resorption, regions of osteosclerosis and thickening of the periodontal ligament can be present; Stage 1 – Patients in this stage have exposed or necrotic bone or fistula, but they are asymptomatic and there

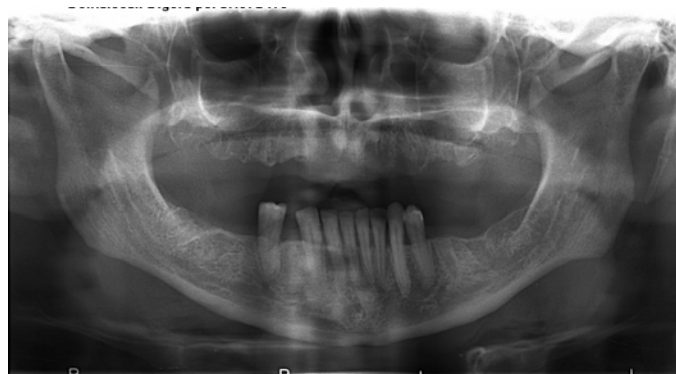is no evidence of infection; Stage 2 – Patients in this stage have the exposed or necrotic bone or fistula with the evidence of infection; Stage 3 – This stage includes patients with the exposed and necrotic bone, with extending of bone exposition beyond the region of the alveolar bone, with the existence of pathologic fracture, extra-oral fistula, oroantral or oronasal communication and osteolysis.

Surgical treatment is recommended only for the stage III.

In this case report, we presented a case of BRONJ advances of the upper jaw. There is no standard therapy in such advanced cases which require a partial osteotomy of the jaw, like in our case.

## Case report

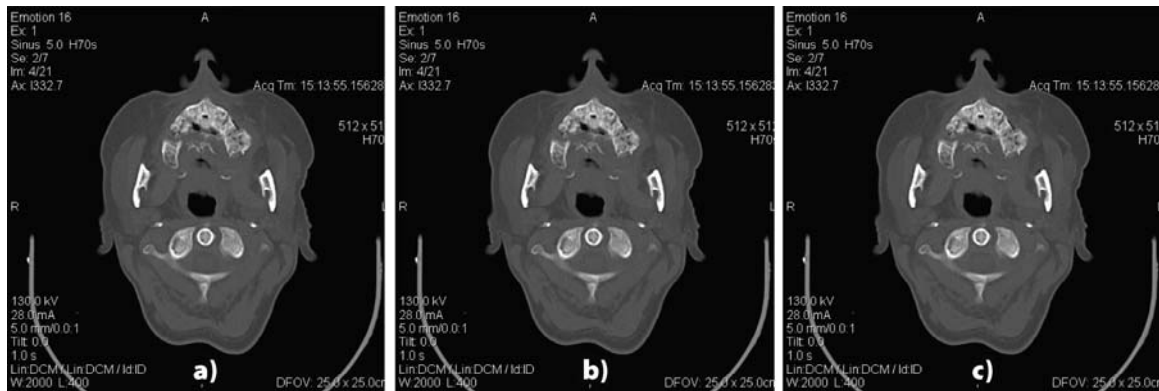A 56-year-old female underwent total mastectomy on the left for the breast cancer (ductal carcinoma) in June 2005. After the surgery, she received a chemotherapy according to the breast cancer therapy protocol: fluorouracil, epirubicin and cyclophosphamide given 3-weekly for 6 cycles. She was operated in September 2007 due to local recurrence. Since 2005 she was treated with hormonotherapy: tamoxifen until November 2007 and anastrozole until November 2007 further. She also underwent laparoscopic ovariectomy in November 2007. Diffuse metastases of the vertebrae in the thoracic and lumbar part were diagnosed after ovariectomy in November 2007. At the same time, she started intravenous zoledronic acid (Zometa<sup>®</sup>; Novartis) 4 mg every 28 days. Before the start of zoledronic acid treatment the patient had been treated by the dentist and for repairing all carious teeth. The patient was regularly checked by an oncologist and physiatrist, the bone scintigraphy and bone densitometry (DEXA) test were done and they indicated stable findings on the bones. In March 2009 the patient felt pain in the region of upper left first premolar; an oncologist did not advise dental treatment, after 6 months the tooth was extracted because of severe pain. After the tooth extraction necrosis of bone around the alveoli in the region of extracted tooth appeared. An oral surgeon made orthopantomography (OPT) (Figure 1) and there were alveolar bone loss and regions of osteosclerosis in the radiographic findings. BRONJ was diagnosed based on clinical and radiographic findings. The patient was treated by the oral surgeon according to the protocol of the



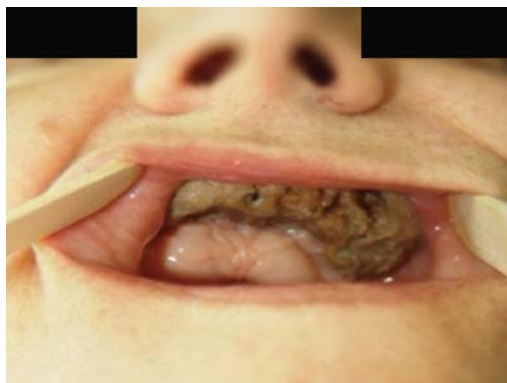**Fig. 1 – Orthopantomography (OPT) shows alveolar bone loss and regions of osteosclerosis.**

American Association of Oral and Maxillofacial Surgeon: at the beginning in stage 1 and 2 she was treated with antibacterial mouth rinse and antibiotics and later in 2011 with surgical debridement. Because of the spreading of the process to the other jaw, the patient decided to stop therapy with zoledronic acid in 2012. She was sent to a maxillofacial surgeon in June 2015. Clinical finding showed that the patient had the exposed necrotic bone in the region of alveolar ridge of both sides of the upper jaw and hard palate, and also regions of osteolysis. The patient had extremely bad breath which resulted in social disorder and the occurrence of depression. The computed tomography (CT) was done and radiological findings showed disturbed architecture of the bone structure in

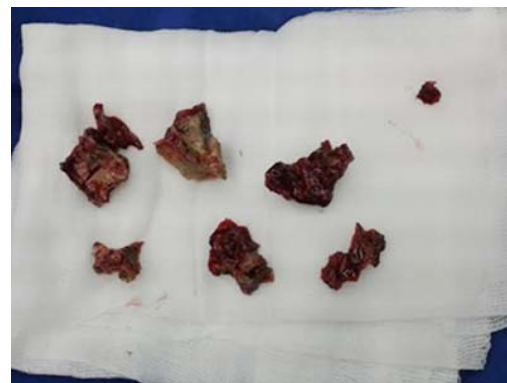
terms of demineralization, discontinuity of the corticocalix with numerous sequestrations in the region of both maxillary alveolar process and palatine bone, the changed mucous membrane of both maxillary sinuses, nasal hall and ethmoidal cell to the left (Figure 2). The stage 3 of BRONJ was diagnosed (Figure 3). According to the Naranjo Adverse Drug Reaction Probability Scale<sup>6</sup> this condition was estimated as a definitive adverse drug reaction (score 9). The patient was operated in October 2015. The sequestrectomy was done, which included resection of the both alveolar ridge of maxilla and part of the hard palate (Figures 4 and 5), and reconstruction with an obturator (Figure 6). Because of local status, the primary reconstruction with micro vascular flap was not plan-



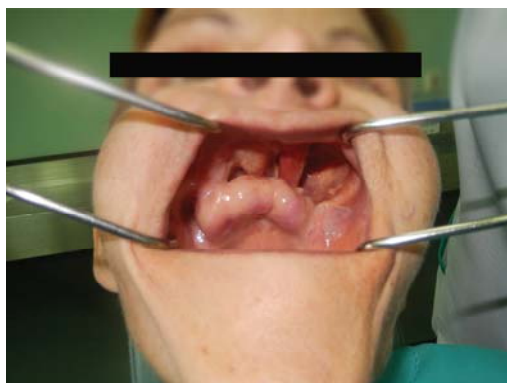**Fig. 2 a-c – Computed tomography (CT) of the midface shows demineralization, discontinuity of the corticocalix with numerous sequestrations in the region of both maxillary alveolar process and palatine bone.**



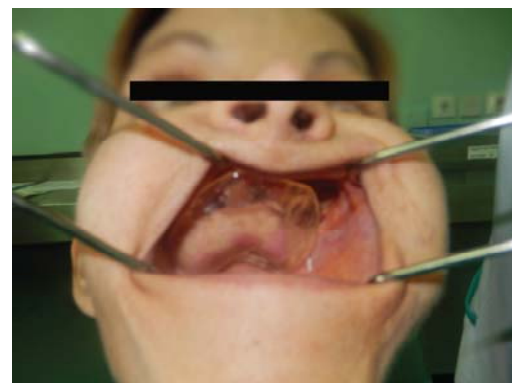**Fig. 3 – Clinical finding.**



**Fig. 4 – Resected parts of the upper jaw.**



**Fig. 5 – Postoperative defect of upper jaw.**



**Fig. 6 – Postoperative defect with obturator.**

ned. The operation was without complications, and the postoperative course was regular. Histopathological findings confirmed the existence of a bone necrosis and bacterial colonies, as well as a mixed inflammatory infiltrate. Definitive prosthodontic rehabilitation was delayed until the complete healing of the wound due to the instability of dental prostheses, according to the opinion of a prosthetic. The patient was extremely satisfied because bad breath after surgery disappeared.

## Discussion

Bisphosphonates are antiresorptive drugs which can be used intravenous (zoledronate and ibandronate) for the treatment of bone metastasis in breast cancer, prostate cancer or lung cancer, and for the treatment of lytic lesions in multiple myeloma and orally in the treatment of osteoporosis, osteopenia, Paget's disease and osteogenesis imperfecta<sup>3,7</sup>. The pathogenesis of bisphosphonate-related osteonecrosis is not completely clarified and there are different theories for example, that the unique BRONJ localisation entirely to the jaws is connected with modified bone remodeling or oversuppression of the bone resorption; inhibition of angiogenesis; constant microtrauma in the mouth; suppression of the immunity; deficiency of the vitamin D; inflammation or infection<sup>2,7</sup>.

Bisphosphonates inhibit osteoclast differentiation and increase apoptosis which leads to the decrease of bone resorption and remodeling. The predisposition of the jaws for BRONJ can be explained with an increased remodeling rate compared to the other bones in the body. Inflammation and infection is an important component of BRONJ. Many different studies identified bacteria in combination with fungi and viruses on the exposed bone of the jaw. The leading hypothesis in the pathophysiology of BRONJ is inhibition of angiogenesis because it leads to avascular necrosis of the bone. Studies in cancer patients treated with zoledronic acid support this theory [these patients had decreased vascular circulating endothelial growth factor (VCGF)]. Osteoclasts are primary target cells for the bisphosphonates (they bind to the hydroxyapatite in bone), but soft tissue toxicity was noted, too. Bisphosphonates are renally excreted, and their concentration in extraosseal tissue is minimal<sup>8</sup>.

BRONJ has the low frequency of occurrence (the risk among cancer patients treated with zoledronate is 1%, and among osteoporosis patients 0.21%). Duration of antiresorptive therapy is an important risk factor of BRONJ and the incidence is higher in patients who had been longer treated with bisphosphonates. The patients with osteoporosis have 100 times smaller risk for developing BRONJ than the cancer patients<sup>9</sup>.

The major risk factor for developing of BRONJ is surgery in maxillofacial region and tooth extraction, which is in 52–61% of patient precipitating event. The risk of BRONJ developing in patients on antiresorptive therapy and those with dental implant placement or endodontic procedure is not reported. Pre-existence of periodontal disease is an important risk factor of BRONJ<sup>5,8,10</sup>.

BRONJ is more likely to develop in the mandible (73%) than in maxilla (22.5%). It can be found in both jaws (4.5%) but that is very rarely<sup>10</sup>. In our case, we presented BRONJ of maxilla which is not so often. The female popula-

tion has a higher prevalence of BRONJ but it is connected with diseases that are treated with bisphosphonates (breast cancer, osteoporosis). Corticosteroids and antiangiogenic agents are associated with an increased risk of BRONJ<sup>11,12</sup>.

This condition requires a multi-disciplinary approach. Early dental screening and appropriate dental therapy before the initiation of bisphosphonate therapy decreased risk of BRONJ. Screening should include the oral examination and radiographics to identify acute infections or places where infection can be developed in order to prevent deterioration when the therapy starts<sup>4</sup>. A patient must be educated about dental care and must be informed that the risk of BRONJ is much lower if dental preventive measures are implemented before the antiresorptive therapies start. Since 2009, we have a staging system for BRONJ which includes four stages<sup>5</sup>. In this paper, the patient with BRONJ in stage 3 was presented, with a wide area of osteonecrosis in the alveolar bone of maxilla on the both side, hard palate and sinus floor, osteolysis, the presence of infection and unpleasant breath.

The treatment plan depends on the stage of the disease<sup>5,13–16</sup>. Patients in stage 0 require conservative treatment and treatment of local factors (caries and periodontal disease). Antibiotics and analgetics can be used if it is indicated. Those patients require frequent controls as to follow the further course of the disease. Patients in stage 1 are medically treated with antimicrobial rinses (chlorhexidine). The patients in stage 2 are treated with antimicrobial rinses in combination with antibiotics (quinolones, metronidazole, clindamycin, doxycycline and erythromycin) because of the risk of bacterial colonization of the exposed bone. Operative therapy can be done in order to reduce the volume of necrotic bone and it can be an addition to the antibiotic therapy. The patients in stage 3 require the combination of antibiotic and surgical therapy which includes debridement and even resection of the bone and reconstruction with a reconstruction plate or obturator. A bisphosphonate-related osteonecrosis can develop in the other bones when transplanted in the oral region<sup>16</sup>, that is the reason why bone reconstruction in the patient with stage 3 of BRONJ can be risky and why reconstruction with the reconstructive plate and obturator is safer.

## Conclusion

BRONJ is a condition with specific clinical picture and presentation. Although it is associated with taking antiresorptive drugs it has relatively obscure pathogenesis. The consequences of these complications can be very serious for the patient, therefore it is necessary to emphasize the importance of screening for the risk of developing of BRONJ. Radical surgical treatment should be performed in cases when medical therapy is no longer capable to stop the development of this complication. Radical resection is necessary in these cases, reconstruction may include free vascular bone grafts which pose a higher risk, and reconstruction with reconstructive plates and obturators which is safer in case of BRONJ. The emphasis, however, must be placed on prevention and on a multidisciplinary approach to the patient under treatment with bisphosphonates. Oncologist, dentist, oral surgeon and the maxillofacial surgeon must cooperate and control the patient who is under treatment with bisphosphonates before therapy start, as well as during and after it.

## R E F E R E N C E S

1. Marx RE. Pamidronate (Aredia) and zoledronate (Zometa) induced avascular necrosis of the jaws: A growing epidemic. *J Oral Maxillofac Surg* 2003; 61(9): 1115–7.
2. Ruggiero SL, Mehrotra B, Rosenberg TJ. Osteonecrosis of the jaws associated with the use of bisphosphonates: A review of 63 cases. *J Oral Maxillofac Surg* 2004; 62(5): 527–34.
3. Bagan J, Scully C, Sabater V, Jimenez Y. Osteonecrosis of the jaws in patients treated with intravenous bisphosphonates (BRONJ): a concise update. *Oral Oncol* 2009; 45(7): 551–4.
4. Reid IR, Cornish J. Epidemiology and pathogenesis of osteonecrosis of the jaw. *Nat Rev Rheumatol* 2011; 8(2): 90–6.
5. Ruggiero SL, Dodson TB, Assael LA, Landesberg R, Marx RE, Mehrotra B. American Association of Oral and Maxillofacial Surgeons. American Association of Oral and Maxillofacial Surgeons position paper on bisphosphonate-related osteonecrosis of the jaws--2009 update. *J Oral Maxillofac Surg* 2009; 67(5 Suppl): 2–12.
6. Naranjo CA, Busto U, Sellers EM, Sandor P, Ruiz I, Roberts EA, et al. A method for estimating the probability of adverse drug reactions. *Clin Pharmacol Ther* 1981; 30(2): 239–45.
7. Wutzl A, Pobl S, Sulzbacher I, Seemann R, Lauer G, Ewers R, et al. Factors influencing surgical treatment of bisphosphonate-related osteonecrosis of the jaws. *Head Neck* 2012; 34(2): 194–200.
8. Agrillo A, Filiaci F, Ramieri V, Riccardi E, Quarato D, Rinna C, et al. Bisphosphonate-related osteonecrosis of the jaw(BRONJ): 5 year experience in the treatment of 131 cases with ozone therapy. *Eur Rev Med Pharmacol Sci* 2012; 16(12): 1741–7.
9. Bucur A, Nita T, Dinca O, Vladan C, Bucur MD. A case series of osteoporosis patients affected by bisphosphonate-related osteonecrosis of the jaws. *Acta Endocrinol (Buc)* 2011; 7(4): 483–90.
10. Tardast A, Sjöman R, Loes S, Abtahi J. Bisphosphonate associated osteomyelitis of the jaw in patients with bony exposure: Prevention, a new way of thinking. *J Appl Oral Sci* 2015; 23(3): 310–14.
11. Borgiolo A, Viviani C, Duvina M, Brancato L, Spinelli G, Brandi ML, et al. Bisphosphonates-related osteonecrosis of the jaw: clinical and physiopathological consideration. *Therap Clin Risk Manag* 2009; 5: 217–27.
12. Loncarevic S, Brajkovic D, Vukomanovic-Djurđević B, Kanjevac T, Vasovic M. Bilateral numb chin syndrome as a symptom of breast cancer metastasis in the mandible: A case report and discussion on the usefulness of cone-beam computed tomography to assess bone involvement in oral cancer. *Oral Radiology* 2015: 1–7.
13. Carlson ER, Basile JD. The role of surgical resection in the management of bisphosphonate-related osteonecrosis of the jaws. *J Oral Maxillofac Surg* 2009; 67(5 Suppl): 85–95.
14. Mücke T, Haarmann S, Wolff K, Hölzle F. Bisphosphonate related osteonecrosis of the jaws treated by surgical resection and immediate osseous microvascular reconstruction. *J Craniomaxillofac Surg* 2009; 37(5): 291–7.
15. Filleul O, Crompton E, Saussez S. Bisphosphonate-induced osteonecrosis of the jaw: a review of 2400 patient cases. *J Cancer Res Clin Oncol* 2010; 136(8): 1117–2416.
16. Pautke C, Otto S, Reu S, Kolke A, Ebreñfeld M, Stürzenbaum S, et al. Bisphosphonate related osteonecrosis of the jaw: manifestation in a microvascular iliac bone flap. *Oral Oncol* 2011; 47(5): 425–9.

Received on December 28, 2015.

Revised on February 29, 2016.

Revised on April 15, 2016.

Accepted on May 13, 2016.

Online First July, 2016.