

Angiogenic and lymphangiogenic profiles in histological variants of papillary thyroid carcinoma

Vesna Skuletic^{1,2}, Gordana D. Radosavljevic¹, Jelena Pantic¹,
Bojana Simovic Markovic¹, Ivan Jovanovic¹, Nikola Jankovic³, Dusica Petrovic⁴,
Andra Jevtovic¹, Radan Dzodic^{5,6}, Nebojsa Arsenijevic¹

1 Center for Molecular Medicine and Stem Cell Research, Faculty of Medical Sciences, University of Kragujevac, Kragujevac, Serbia

2 Institute of Pathology and Forensic Medicine, Military Medical Academy, Belgrade, Serbia

3 Department of Medical Informatics and Statistics, Faculty of Medical Sciences, University of Kragujevac, Kragujevac, Serbia

4 Department of Pathology, Clinical Center Kragujevac, Serbia

5 School of Medicine, University of Belgrade, Belgrade, Serbia

6 Department of Surgical Oncology, Institute of Oncology and Radiology of Serbia, Belgrade, Serbia

KEY WORDS

angiogenesis,
lymphangiogenesis,
papillary thyroid
carcinoma

ABSTRACT

INTRODUCTION Papillary thyroid carcinoma (PTC) is a well-differentiated tumor that occurs in several histological variants whose biological behaviors remain unclear. Angiogenesis and lymphangiogenesis are critical processes that enable tumor progression.

OBJECTIVES The aim of this study was to evaluate the angiogenic and lymphangiogenic phenotypes of PTC, considering the differences between histological variants.

PATIENTS AND METHODS Angiogenic and lymphangiogenic profiles were analyzed by determining microvascular density (MVD) and lymphatic vessel density (LVD) in 73 cases of PTC, using immunohistochemistry. To assess the biological markers involved in blood and lymph vessel formation, the expression of vascular endothelial growth factor (VEGF), cyclooxygenase 2 (COX-2), and p27^{kip1} (p27) was determined.

RESULTS MVD was significantly higher in patients with high-risk PTC and in those with local extrathyroidal and vascular invasion. Positive VEGF expression was strongly associated with high MVD and age-related tumor enlargement. The presence of lymph vessel invasion was associated with the expression of either VEGF or COX-2. The analysis of angiogenesis and lymphangiogenesis in different histological variants of PTC revealed elevated LVD rather than MVD in the follicular variant of PTC (FV-PTC). Lower MVD was observed in FV-PTC relative to the classic variant of PTC (CV-PTC). The frequency of VEGF-positive tumors was higher in CV-PTC than in FV-PTC. A significant association between COX-2 and p27 expression was observed in FV-PTC but not in CV-PTC.

CONCLUSIONS These results suggest that VEGF, COX-2, and p27 may be important biological markers that determine the angiogenic and lymphangiogenic potentials of PTC, particularly between the follicular and classic variants.

INTRODUCTION The most common type of thyroid malignancy is papillary thyroid carcinoma (PTC). PTC has a favorable prognostic outcome and usually occurs in several histological variants.^{1,2} The molecular profiles that determine the potential aggressive behaviors of different histological variants, particularly the follicular and classical variants, are not fully understood.

Angiogenesis and lymphangiogenesis are fundamental processes for tumor progression and represent important characteristics of the tumor microenvironment.³ While angiogenesis promotes tumor growth and metastasis,⁴ lymphangiogenesis provides an alternative route for cancer cell dissemination to the lymph nodes.⁵ The frequently used method for quantifying angiogenesis and

Correspondence to:

Gordana D. Radosavljevic, MD,
PhD, Faculty of Medical Sciences,
University of Kragujevac, Svetozara
Markovica 69, 34000 Kragujevac,
Serbia, phone: +38134306800,
e-mail: perun.gr@gmail.com

Received: January 29, 2017.

Revision accepted: April 19, 2017.

Published online: April 20, 2017.

Conflict of interest: none declared.

Pol Arch Intern Med. 2017;

127 (6): 429-437

doi:10.20452/pamw.3999

Copyright by Medycyna Praktyczna,

Kraków 2017

lymphangiogenesis is determination of the microvascular density (MVD) and lymphatic vessel density (LVD). MVD and LVD indicate an increased risk for tumor progression and predict disease outcome.^{6,7}

The crucial event in the uncontrolled formation of new blood and lymphatic vessels in the tumor is a disturbance in the balance between stimulators and inhibitors of these processes.⁸⁻¹⁰ Members of the vascular endothelial growth factor (VEGF) family are key stimulators that exert multiple effects on both angiogenesis and lymphangiogenesis.^{3,11} VEGF, also known as VEGF-A, is a critical regulator of tumor angiogenesis and acts as a stimulator of proliferation, migration, and endothelial cell survival.¹² Lymphangiogenesis is mainly driven by VEGF-C.¹³

A molecule that may be involved in VEGF transcription is cyclooxygenase 2 (COX-2), thus suggesting a possible interaction between COX-2 and VEGF that promotes carcinogenesis.¹⁴ Moreover, evidence suggests that the level of COX-2 correlates with increased MVD in tumors.¹⁵ Additionally, previous studies have indicated that COX-2 may be involved in the upregulation of VEGF-C.¹⁶

It is well documented that VEGF is an endothelial cell-specific mitogen, but the effects of COX-2 on cell proliferation are not completely clear. In fact, COX-2 and its subsequently derived prostaglandins may modulate the cell cycle by altering the activities of cyclin-dependent kinase (CDK) inhibitors.¹⁷ p27^{kip1} (p27) is a CDK inhibitor that regulates the transition from the G1 to the S phase of the cell cycle.^{18,19} Previous studies have shown that p27 expression has both diagnostic and prognostic significance in various human cancers, including endocrine tumors.^{20,21}

In general, PTC is a well-differentiated tumor with a high survival rate. However, when tumor progression occurs, patient survival is significantly affected. Additionally, despite the high incidence and increasing knowledge of PTC, the clinical behavior and disease outcome of its histological variants remain controversial. The main goal of this study was to evaluate the impact of the expression of biological markers such as VEGF, COX-2, and p27 on the angiogenic and lymphangiogenic profiles in PTC and its histological variants.

PATIENTS AND METHODS Patients and tissue samples

This study was conducted at the Center for Molecular Medicine and Stem Cell Research, Faculty of Medical Sciences, University of Kragujevac and the Institute of Pathology and Forensic Medicine, Military Medical Academy, Belgrade, Serbia. Ethical approval was obtained from the relevant ethics committee.

Paraffin-embedded thyroid tissue sections were obtained from 73 patients diagnosed with PTC between 2009 and 2013 and 11 patients with multinodular goiter (MNG) diagnosed between 2016 and 2017, who were treated at the Military Medical Academy, Belgrade, Serbia. Biological material from patients with PTC was obtained during

thyroidectomy or lobectomy with or without regional lymphadenectomy. Each diagnosis was confirmed by a pathologist on hematoxylin and eosin-stained slides, using standard histopathological criteria. The diagnosis was established according to the World Health Organization criteria based on postoperative pathohistological examination.²²

Tumor size was categorized in accordance with the TNM staging system.²³ On the basis of pathohistological examination, tumors were classified into 4 histological variants: classic variant of PTC (CV-PTC), follicular variant of PTC (FV-PTC), tall cell variant, and papillary microcarcinoma.²²

Immunohistochemistry The expression of VEGF, CD31, COX-2, D2-40, and p27 proteins was assessed using immunostaining. Thyroid tissue sections were routinely fixed in 4% buffered formaldehyde, dehydrated through a graded alcohol series, cleared in xylene, and embedded in paraffin. The paraffin-embedded tissue samples were sectioned at 4 to 5 μ m, and the tissue sections were deparaffinized by 2 washes in xylene for 10 minutes and rehydrated in a series of 100%, 96%, 70%, and 50% alcohol solutions. Immunohistochemical staining was performed according to the streptavidin-biotin method. Briefly, sections were incubated with 3% hydrogen peroxide to block endogenous peroxidase activity and then microwaved for 20 minutes in 10-mmol/l sodium citrate (pH 6.0). The sections were incubated with antibodies (all from Abcam, Cambridge, Massachusetts, United States) against VEGF (mAb, 1:200, #ab16883), CD31 (pAb, 1:200, #ab28364), COX-2 (pAb, 1:1000, #ab15191), D2-40 (mAb, 1:200, #ab77854), or p27 (pAb, 1:500, #ab7961) for 60 minutes. Commercially available staining kits (Mouse specific HRP/DAB [ABC] Detection IHC Kit, #ab64259 and Rabbit specific HRP-AEC Detection IHC Kit, #94361; Abcam, United Kingdom) were used for marker detection. Negative controls were subjected to the same procedure with the omission of the primary antibody incubation step. Positive controls consisted of tissue known to contain the protein of interest.

Assessment of protein staining Immunohistochemical staining was evaluated independently by 3 pathologists in a blinded fashion. Pathologists without clinical knowledge of the patients quantified and scored the samples. VEGF, COX-2, and p27 samples were graded using a semiquantitative scoring system based on the percentage of stained cancerous tissue, adjacent tissue, as well as noncancerous tissue (MNG): negative ($\leq 10\%$) or positive ($> 10\%$).²⁴ Patients with poor quality of immunostaining were excluded (VEGF expression, 2 patients; COX-2 expression, 4 patients; and p27 expression, 1 patient).

Quantification of microvascular density and lymphatic vessel density MVD was measured using the pan-endothelial cell marker CD31. The assessment

TABLE 1 Demographic, clinical, and pathological characteristics of patients with papillary thyroid carcinoma

Variable		No. (%) of patients
Age	<50 years	26 (35.6)
	≥50 years	47 (64.4)
Sex	Male	14 (19.2)
	Female	59 (80.8)
Risk group ^a	Low	65 (89.0)
	High	8 (11.0)
Vascular invasion	No	61 (83.6)
	Yes	12 (16.4)
Lymph vessel invasion	No	16 (21.9)
	Yes	57 (78.1)
Local extrathyroidal invasion	No	64 (87.7)
	Yes	9 (12.3)
Histological variant	Classical	16 (21.9)
	Follicular	43 (58.9)
	Tall cell	4 (5.5)
	Microcarcinoma	10 (13.7)
Tumor size (pT) ^b	≤2 cm (pT1)	34 (46.6)
	<50 years	10 (13.7)
	≥50 years	24 (32.9)
	2–4 cm (pT2)	29 (39.7)
	<50 years	15 (20.5)
	≥50 years	14 (19.2)
	>4 cm (pT3)	10 (13.7)
	<50 years	1 (1.4)
≥50 years	9 (12.3)	

a Patients aged ≥50 years with local extrathyroidal invasion were classified into the high-risk group; all other patients were classified into the low-risk group.

b Primary tumor (pT) classification was confirmed in accordance with the TNM staging system.²³

TABLE 2 Association between microvascular density and the expression of vascular endothelial growth factor and cyclooxygenase 2

Parameter	n	MVD		P value
		Low	High	
VEGF	Negative	53	33	0.007 ^a
	Positive	18	5	
COX-2	Negative	33	19	NS
	Positive	36	17	

a Statistical significance was determined using the χ^2 test.

Abbreviations: COX-2, cyclooxygenase 2; MVD, microvascular density; NS, nonsignificant; VEGF, vascular endothelial growth factor

of LVD was performed using the highly specific lymphatic endothelium marker D2-40. Three areas with the highest number of blood and lymphatic vessels (“hot spots”) were selected by light microscopy at 40-fold and 100-fold magnifications. The immunostained blood and lymphatic vessels were then counted in the 3 hot spots at higher magnification (200×). The MVD and LVD for each case were expressed as the mean

value (total number of vessels in 3 hot spot microscopic fields/3).^{25,26} Single endothelial cells, strips, or clusters of endothelial cells that were positive for CD31 and D2-40 were considered individual microvessels. Further, the median MVD of the entire group was used to classify patients into 2 subgroups: with high (> median) or low (≤ median) MVD.²⁷

Statistical analysis The SPSS statistical software package version 23.0 (SPSS Inc., Chicago, Illinois, United States) was used for statistical analysis. The normality quotes of distribution were tested by the Kolmogorov–Smirnov test. The *t* test, the nonparametric Mann–Whitney test, and the χ^2 test were used, as appropriate. The receiver operating characteristic curves were used to determine the sensitivity and specificity. All reported *P* values were 2-sided. A *P* value of less than 0.05 was considered statistically significant, and a *P* value of less than 0.001 was considered as denoting highly significant difference.

RESULTS Association between microvascular density and clinical and pathological characteristics of patients with papillary thyroid carcinoma Angiogenesis (neovascularization) is an essential process for the progression of most solid tumors. This study aimed to analyze the angiogenic phenotype (MVD and expression of proangiogenic factors VEGF and COX-2) in 73 tissue samples of PTC. The clinical and pathological characteristics of patients with PTC included in this study are presented in **TABLE 1**.

Following the study of Sugitani et al,²⁸ patients with PTC were classified into low- or high-risk groups. Patients in our study did not have distant metastases or altered metastatic regional lymph nodes larger than 3 cm. Thus, patients aged 50 years or older with local extrathyroidal invasion were included in the high-risk group, and those under the age of 50 years with or without local extrathyroidal invasion were classified into the low-risk group. The MVD values were significantly higher in the high-risk group (*P* < 0.05; **FIGURE 1A**). Significantly higher MVD values were also observed in patients with local extrathyroidal invasion (*P* < 0.05; **FIGURE 1B**). Additionally, higher MVD values were strongly associated with the presence of vascular invasion (*P* < 0.05; **FIGURE 1C**). The obtained data indicate that MVD may be a valuable marker of vascular invasion (sensitivity, 75%; specificity, 67.2%; cut-off, 3.88; **FIGURE 1D**). Representative images illustrating different patterns of CD31-positive microvessels are shown in **FIGURE 1E**.

Papillary thyroid carcinoma angiogenesis in relation to vascular endothelial growth factor and cyclooxygenase-2 expression To better understand the potential mechanisms of angiogenesis in PTC, we examined the association between MVD and the expression of the proangiogenic factors VEGF and COX-2. The median blood vessel count for

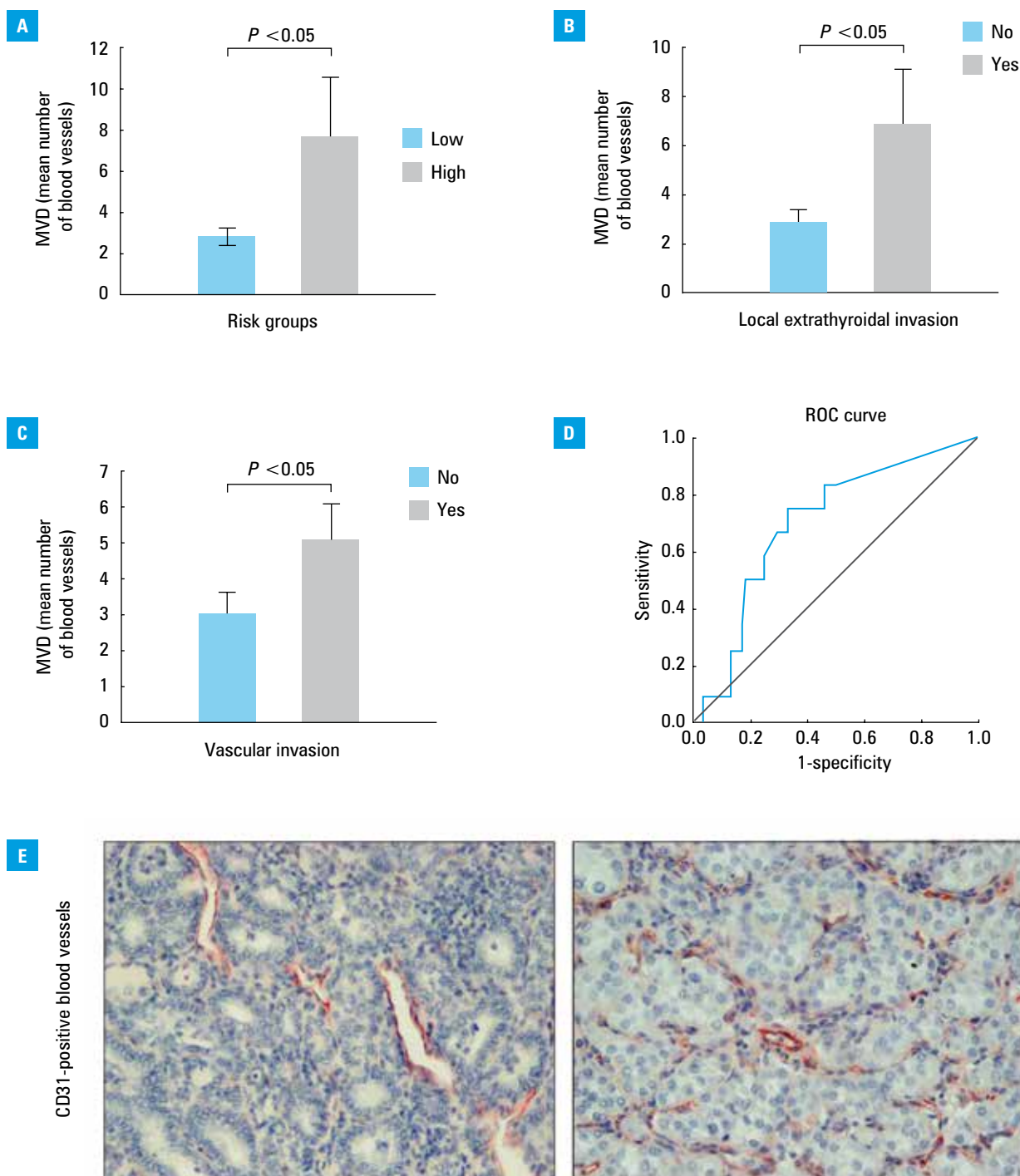


FIGURE 1 Evaluation of microvascular density (MVD) in relation to different clinical and pathological parameters of papillary thyroid carcinoma (PTC); **A** – significantly elevated MVD values in high-risk patients; **B** – significantly elevated MVD values in patients with local extrathyroidal invasion; **C** – increased MVD values are associated with the presence of vascular invasion; **D** – receiver operating characteristic (ROC) curve to determine the accuracy of MVD to predict the degree of vascular invasion (sensitivity, 75%; specificity, 67.2%; cut-off, 3.88). *P* values were assessed by the Mann–Whitney test or an independent samples *t* test. **E** – representative sections of vascularization pattern stained for CD31 (low and high) in PTC (magnification, 200×).

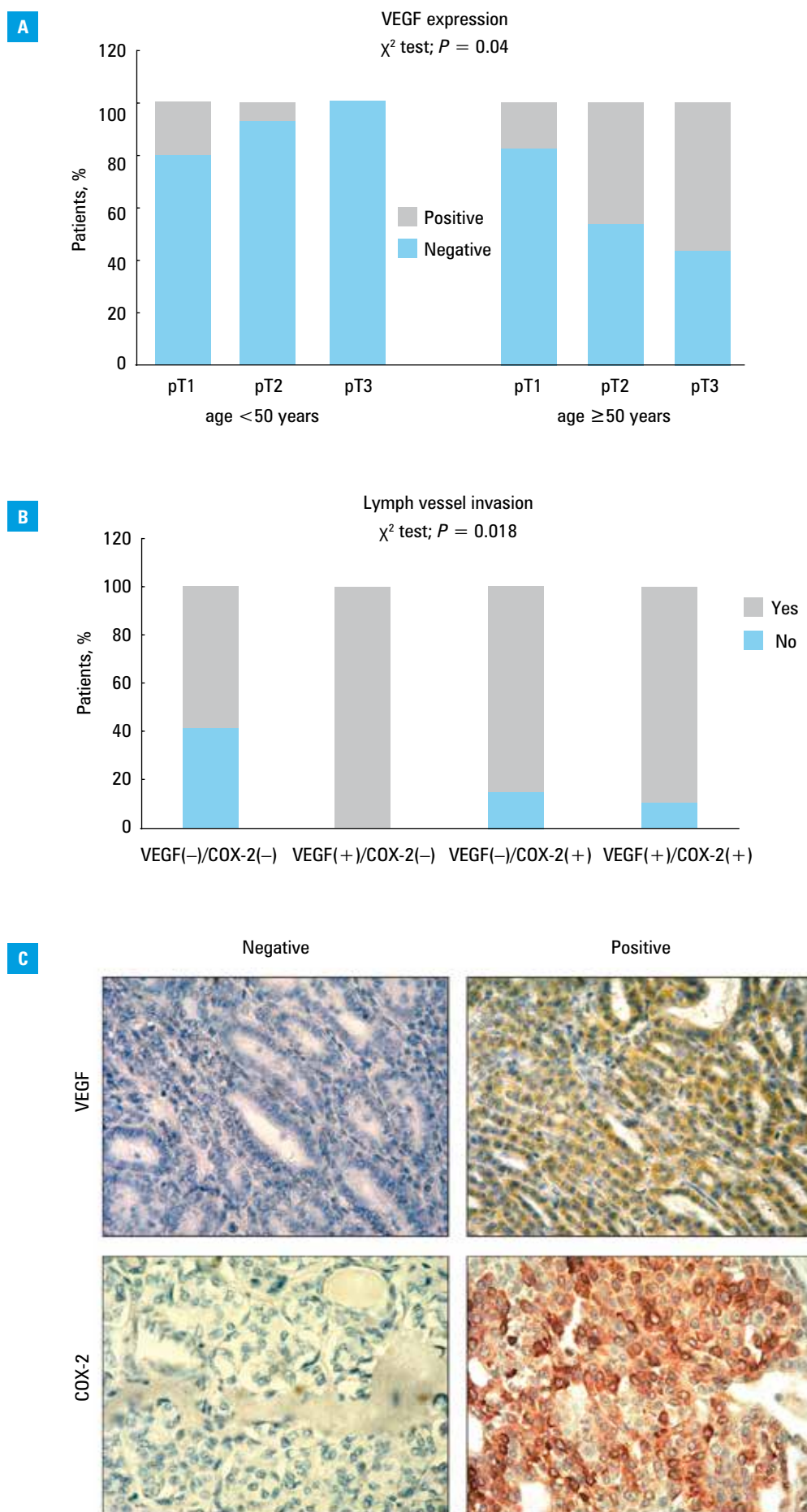
all patients with PTC was 3.00 (per 200× field), with an interquartile range of 0 to 5.58. Accordingly, patients were classified into 2 groups: high MVD (>3.00) or low MVD (≤3.00). As shown in **TABLE 2**, high MVD was strongly correlated with positive VEGF but not COX-2 expression. Additionally, a significantly increased frequency of positive VEGF expression was observed among

patients aged 50 years or older who had larger tumors (pT2 and pT3) (**FIGURE 2A**).

In the present study, COX-2 expression was not related to clinical and pathological characteristics of patients with PTC (data not shown). However, patients with PTC were further categorized into the following groups: VEGF(-)/COX-2(-), VEGF(+)/COX-2(-), VEGF(-)/COX-2(+), and VEGF(+)/COX-2(+), on the basis of positive or

FIGURE 2

Immunohistochemical analysis of vascular endothelial growth factor (VEGF) and cyclooxygenase-2 (COX-2) expression in papillary thyroid carcinoma tissue; **A** – frequency of positive VEGF expression was higher among patients aged 50 years or older who had larger tumors (pT2 and pT3) (χ^2 test; $P = 0.04$); **B** – lymph vessel invasion was associated with VEGF and COX-2 expression (χ^2 test; $P = 0.018$); **C** – representative sections demonstrate VEGF and COX-2 staining in tumor tissue (magnification, 400 \times)



negative marker staining. The expression of either VEGF or COX-2 was associated with an increased percentage of patients with lymph vessel invasion (FIGURE 2B). It seems that VEGF and COX-2 are involved in tumor invasion either together or independently. Representative images illustrating positive and negative VEGF and COX-2 staining are presented in FIGURE 2C. There were no differences in the expression of these 2 markers between cancerous and adjacent non-cancerous tissue (data not shown).

Different patterns of lymphatic and vascular density depending on the histological variant of papillary thyroid carcinoma Another goal of the present study was to determinate the importance of distinguishing different histological variants of PTC according to their angiogenic and lymphangiogenic profiles. Although there was no significant association between LVD and any of the clinical and pathological characteristics of patients with PTC (data not shown), the LVD value (mean [SD], 10.55 [0.86]) was significantly higher than the MVD value (mean [SD], 2.99 [0.48]) in FV-PTC ($P = 0.000$) but not in CV-PTC (FIGURE 3A). All cases of PTC in our study showed predominantly intratumoral MVD, while LVD was mostly noted in peritumoral tissue (data not shown).

Patients with FV-PTC had a lower MVD value in comparison with patients with CV-PTC (mean [SD], 6.11 [1.58], $P = 0.014$) (FIGURE 3A). Further, the percentage of CV-PTC patients with positive VEGF expression (46.67%) was significantly higher compared with those with FV-PTC (14.29%; $P = 0.016$) (FIGURE 3B). Interestingly, there was a significant association between the expression of COX-2 and p27 in FV-PTC ($P = 0.000$) but not in CV-PTC (FIGURE 3C). The present study demonstrated that p27 expression did not differ between cancerous and adjacent noncancerous thyroid tissue. The adjacent noncancerous tissues showed strong p27 nuclear staining, while cancer cells were considered as having mild cytoplasmic expression (data not shown).

Finally, to determine whether there is a difference in the expression of the studied markers (VEGF, COX-2, and p27), as well as differences in MVD and LVD between noncancerous and cancerous thyroid lesions, additional 11 patients with MNG were included in the study. In our samples, MVD was significantly lower in MNG than in PTC tissue. The positive VEGF expression was more common in patients with PTC, while the p27 expression was more frequent in MNG. However, there was no significant difference in the expression of these markers between cancerous and noncancerous tissue (Supplementary material, Figure S1A). However, the expression of COX-2 and of D2-40 as the marker of lymphatic endothelium was not detected in patients with MNG (data not shown). These findings may be due to the limited number of patients with noncancerous thyroid lesions in our cohort.

Furthermore, a comparison of MVD between patients with MNG and those with FV-PTC and CV-PTC revealed significantly lower values in patients with MNG. Additionally, the percentage of patients with MNG with positive VEGF expression (9.1%) was significantly lower compared with those with CV-PTC (46.67%) and FV-PTC (14.29%). There was no significant difference in the p27 expression between noncancerous tissue and both PTC variants (Supplementary material online, Figure S1B).

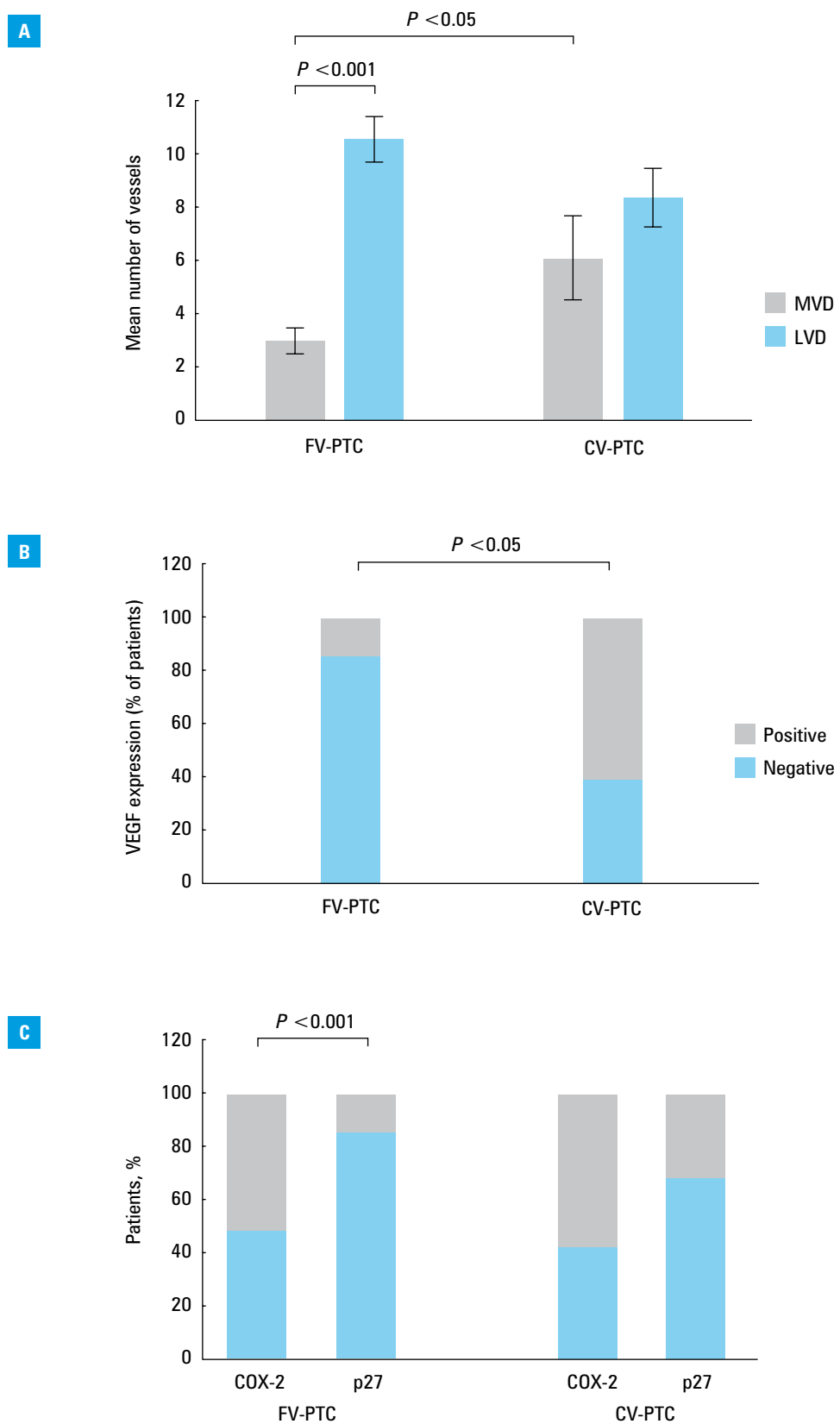
DISCUSSION The progression of thyroid carcinoma is an angiogenesis-dependent process.¹⁴ In line with this finding, the present study showed increased MVD values in patients with PTC with high risk, as well as in those with vascular and local extrathyroidal invasion. Accordingly, MVD may be considered a valuable marker for the determination of vascular invasion. The well-established protumorigenic role of VEGF was reflected in the strong association between its positive expression and both high MVD and larger tumor size, in accordance with the patient's age. These results suggest that VEGF and COX-2 are involved in lymph vessel invasion either together or independently. Interestingly, histological variants of PTC demonstrated significant heterogeneity in their angiogenic and lymphangiogenic profiles. Thus, a significantly higher LVD compared with MVD was observed in FV-PTC but not in CV-PTC. Additionally, MVD was significantly reduced in FV-PTC compared with CV-PTC. Consistent with the reduced MVD, the percentage of patients with FV-PTC with positive VEGF expression was significantly lower compared with those with CV-PTC. Finally, there was a significant association between COX-2 and p27 expressions in FV-PTC but not in CV-PTC.

Vascular and local extrathyroidal invasion is a hallmark of PTC aggressiveness.^{29,30} In our study, higher MVD, as an indicator of the extent of angiogenesis, was strongly associated with the presence of vascular invasion. Histologically determined vascular invasion may be considered a sign of a greater tendency toward haematogenous spread of tumor cells and could result in increased formation of metastases.³¹ The sensitivity (75%) and specificity (67.2%) of MVD regarding vascular invasion suggests that MVD may serve as a valuable marker for the determination of vascular invasion in PTC. Furthermore, higher MVD values were strongly associated with local extrathyroidal invasion and a high risk for local spread of tumor. The increased risk of recurrence and shorter disease-free survival were reported in patients with PTC with greater MVD,³² but these findings have not been confirmed by other studies.^{33,34}

VEGF expression is increased in thyroid cancers, but this potent angiogenic factor is not related to poor prognosis regarding tumor size, multifocality, and/or the presence of lymphatic or distant metastases.³⁵ However, the expression

FIGURE 3

Lymphangiogenic and angiogenic phenotypes in follicular and classic variants of papillary thyroid carcinoma (FV-PTC and CV-PTC, respectively); **A** – a mean number of vessels in FV-PTC and CV-PTC. Statistical significance was tested by the Mann–Whitney test and an independent samples *t* test. **B** – percentage of patients with negative and positive expression of vascular endothelial growth factor (VEGF) among patients with FV-PTC and CV-PTC (χ^2 test; $P = 0.016$); **C** – significant association between the expression of cyclooxygenase 2 and p27 in FV-PTC (χ^2 test; $P < 0.0001$). However, a statistically significant association between these markers was not observed in CV-PTC.



of *VEGF* mRNA and protein has been well documented in PTC. Overexpression of *VEGF* mRNA and protein has been observed in primary tumor tissue with the presence of lymph node metastases, as well as in secondary lesions of PTC.³⁶ Additionally, *VEGF* mRNA expression is increased in smaller tumors, whereas the *VEGF* protein is overexpressed at more advanced tumor stages of PTC.³⁶

Some investigators have reported a significant association between age, sex, and increased expression of *VEGF* and *COX-2* with an advanced stage of PTC.³⁷ In agreement with a previous report,³⁸ the data described herein show that positive *VEGF* expression correlates with high MVD. In our series, an increased frequency of positive *VEGF* expression was associated with tumor enlargement among patients aged 50 years or older,

further indicating the impact of VEGF on tumor growth. The lack of VEGF expression in some samples of PTC in our study can be partially due to the fact that most of the included patients were in pT1 and pT2 stages. However, patients in pT3 stage were mostly VEGF-positive, suggesting that probably hypoxic and acidic environment characteristic for a more advanced pT stage stimulates the overexpression of VEGF.³⁶ However, there were no significant associations between positive COX-2 expression and MVD or clinical and pathological characteristics of patients with PTC. Previous studies have shown that the expression of COX-2 and VEGF may promote angiogenesis of thyroid carcinoma,¹⁴ while the present data suggest that angiogenesis in PTC is mostly VEGF-dependent.

Lymphangiogenesis is critical for the success of tumor cell dissemination.^{39,40} Evidence suggests that the expression of VEGF-C, a potent prolymphangiogenic factor, and LVD is higher in PTC with lymph node metastases than in PTC without lymph node metastases.^{41,42} The present study demonstrated that the expression of either VEGF or COX-2 is associated with the presence of lymph vessel invasion. It appears that VEGF and COX-2 may trigger invasion in PTC either together or independently.

Recent results reported by Woliński et al⁴³ suggested that the measurement of *VEGF-C* mRNA levels is important to distinguish benign and malignant thyroid lesions. They concluded that *VEGF-C* expression on the mRNA level is more useful than *VEGF-A* mRNA expression. In the present study, MVD was significantly lower in MNG compared with PTC. Some studies demonstrated that FV-PTC differs from CV-PTC both in morphological and clinical aspects.^{44,45} The present study provides evidence that FV-PTC has higher LVD compared with MVD. In contrast, there was no difference between LVD and MVD in CV-PTC. Additionally, the MVD values were significantly reduced in FV-PTC, as well as in MNG compared with CV-PTC. A previous report, with 123 samples, also demonstrated that *VEGF* mRNA and protein are overexpressed in CV-PTC compared with FV-PTC.³⁶ The authors also demonstrated a significant overexpression of *VEGF-C* mRNA, but not protein, in FV-PTC relative to CV-PTC. In line with the previous study,³⁶ our results show a similar trend for elevated LVD values in FV-PTC compared with CV-PTC, although this difference was not significant. Thus, it appears that the simultaneous analysis of LVD and MVD may be helpful for the determination of tumor behavior in different histological variants of PTC.

There have been no previous studies analyzing the lymphatic and angiogenic profiles in FV-PTC and CV-PTC in more detail. These data suggest that the patterns of COX-2, VEGF, and p27 expression vary depending on the histological variant of PTC. Our results indicate that COX-2 and p27 expression is inversely associated with FV-PTC but not CV-PTC. In particular, the high frequency of

COX-2 expression accompanied a lower frequency of p27 expression and was associated with higher LVD values in FV-PTC. It can thus be hypothesized that this pattern of COX-2 and p27 expression may affect the proliferation of lymphatic endothelial cells. This hypothesis supports the finding that COX-2 induction or overexpression results in increased production of prostaglandin E2, which further increases cell proliferation via p27 phosphorylation.¹⁷ Moreover, it was reported that the phosphorylation of p27 is responsible for its degradation by the proteasome.⁴⁶ Furthermore, a possible mechanism explaining higher MVD in CV-PTC could be the higher frequency of positive VEGF expression in comparison with FV-PTC, which suggests that VEGF is a key player in PTC angiogenesis, especially in CV-PTC. Unfortunately, in this research, the expression of studied markers was not evaluated in other histological variants of PTC, such as the tall cell variant and microcarcinoma due to the limited number of patients.

In summary, our results suggest that VEGF, COX-2, and p27 may be important biological markers that explain the differences in angiogenic and lymphangiogenic potentials between the follicular and classic variants of PTC. However, further studies with a larger number of patients are needed to elucidate the clinical significance of these intriguing findings.

Supplementary material online Supplementary material is available with the online version of the article at www.pamw.pl.

Acknowledgments This research was supported by the Ministry of Education, Science and Technological Development of Serbia (grants ON 175 071, ON175 069, and ON 175 103) and by the Faculty of Medicine Sciences of the University of Kragujevac, Serbia (grant JP 27/12 and MP 02/14). We would like to thank Milan Milojevic for excellent technical assistance and Snezana Cerovic and Bozidar Kovacevic, pathologists at the Institute of Pathology and Forensic Medicine, Military Medical Academy, for assistance with the pathohistological analysis.

Contribution statement VS, GDR, and JP designed and performed the study and wrote the manuscript. IJ, AJ, and DP performed the study and analyzed the data. NJ and BSM contributed to data acquisition and interpretation. RDz and NA supervised and coordinated the project. All authors contributed to the manuscript.

REFERENCES

- 1 LiVolsi VA, Albores-Saavedra J, Asa SL, et al. Papillary carcinoma. In: DeLellis RA, Lloyd RV, Heitz PU et al, eds. WHO: Pathology and Genetics of Tumors of Endocrine Organs. end 3, Lyon, France: IARC Press; 2004: 57-66.
- 2 Krajewska J, Jarzab B. An internist's approach to cancer diseases based on the model of thyroid cancer treated with tyrosine kinase inhibitors. *Pol Arch Med Wewn.* 2016; 126: 925-928.

- 3 Gomes FG, Nedel F, Alves AM, et al. Tumor angiogenesis and lymphangiogenesis: tumor/endothelial crosstalk and cellular/microenvironmental signaling mechanisms. *Life Sci.* 2013; 92: 101-107.
- 4 Folkman J. Role of angiogenesis in tumor growth and metastasis. *Semin Oncol.* 2002; 29:15-28.
- 5 Alitalo A, Detmar M. Interaction of tumor cells and lymphatic vessels in cancer progression. *Oncogene.* 2012; 31: 4499-4508.
- 6 Rioux-Leclercq N, Epstein JI, Bansard JY, et al. Clinical significance of cell proliferation, microvessel density, and CD44 adhesion molecule expression in renal cell carcinoma. *Hum Pathol.* 2001; 32: 1209-1215.
- 7 Pak KH, Jo A, Choi HJ, et al. The different role of intratumoral and peritumoral lymphangiogenesis in gastric cancer progression and prognosis. *BMC Cancer.* 2015; 15: 498.
- 8 Hanahan D, Folkman J. Patterns and emerging mechanisms of the angiogenic switch during tumorigenesis. *Cell.* 1996; 86: 353-364.
- 9 Carmeliet P, Jain RK. Angiogenesis in cancer and other diseases. *Nature.* 2000; 407: 249-257.
- 10 Zampell JC, Avraham T, Yoder N, et al. Lymphatic function is regulated by a coordinated expression of lymphangiogenic and anti-lymphangiogenic cytokines. *Am J Physiol Cell Physiol.* 2012; 302: 392-404.
- 11 Ferrara N, Gerber HP, Lecouter J. The biology of VEGF and its receptors. *Nat Med.* 2003; 9: 669-676.
- 12 Masoumi Moghaddam S, Amini A, Morris DL, et al. Significance of vascular endothelial growth factor in growth and peritoneal dissemination of ovarian cancer. *Cancer Metastasis Rev.* 2012; 31: 143-162.
- 13 Skobe M, Hawighorst T, Jackson DG, et al. Induction of tumor lymphangiogenesis by VEGF-C promotes breast cancer metastasis. *Nat Med.* 2001; 7: 192-198.
- 14 Ji B, Liu Y, Zhang P, et al. COX-2 expression and tumor angiogenesis in thyroid carcinoma patients among northeast Chinese population-result of a single-center study. *Int J Med Sci.* 2012; 9: 237-242.
- 15 Masunaga R, Kohno H, Dhar DK, et al. Cyclooxygenase-2 expression correlates with tumor neovascularization and prognosis in human colorectal carcinoma patients. *Clin Cancer Res.* 2000; 6: 4064-4068.
- 16 Liu H, Xiao J, Yang Y, et al. COX-2 expression is correlated with VEGF-C, lymphangiogenesis and lymph node metastasis in human cervical cancer. *Microvasc Res.* 2011; 82: 131-140.
- 17 Sobolewski C, Cerella C, Dicato M, et al. The Role of Cyclooxygenase-2 in Cell Proliferation and Cell Death in Human Malignancies. *Int J Cell Biol.* 2010; 2010: 215-158.
- 18 Reed SI, Bailly E, Dulic V, et al. G1 control in mammalian cells. *J Cell Sci Suppl.* 1994; 18: 69-73.
- 19 Sherr CJ, Roberts JM. Inhibitors of mammalian G1 cyclin-dependent kinases. *Genes Dev.* 1995; 9:1149-1163.
- 20 Lloyd RV, Jin L, Qian X, et al. Aberrant p27kip1 expression in endocrine and other tumors. *Am J Pathol.* 1997; 150: 401-407.
- 21 Lloyd RV, Erickson LA, Jin L, et al. p27kip1: a multifunctional cyclin-dependent kinase inhibitor with prognostic significance in human cancers. *Am J Pathol.* 1999; 154: 313-323.
- 22 DeLellis R, Lloyd R, Heitz P, et al. WHO: Pathology and genetics of tumors of endocrine organs, edn 3. Lyon, France: IARC Press 2004.
- 23 Edge SB, Byrd DR, Compton CC, et al. *AJCC Cancer Staging Manual*, 7 ed. New York, NY: Springer-Verlag 2010.
- 24 Radosavljevic G, Lujic B, Jovanovic I, et al. Interleukin-17 may be a valuable serum tumor marker in patients with colorectal carcinoma. *Neoplasma.* 2010; 57: 135-144.
- 25 Du B, Yang ZY, Zhong XY, et al. Metastasis-associated protein 1 induces VEGF-C and facilitates lymphangiogenesis in colorectal cancer. *World J Gastroenterol.* 2011; 17: 1219-1226.
- 26 Avdalyan A, Bobrov I, Klimachev V, et al. Prognostic value of microvessel density in tumor and peritumoral area as evaluated by CD31 protein expression and argyrophilic nucleolar organizer region count in endothelial cells in uterine leiomyosarcoma. *Sarcoma.* 2012; 2012: 594512. doi:10.1155/2012/594512
- 27 Vermeulen PB, Gasparini G, Fox SB, et al. Quantification of angiogenesis in solid human tumours: an international consensus on the methodology and criteria of evaluation. *Eur J Cancer.* 1996; 32A: 2474-2484.
- 28 Sugitani I, Kasai N, Fujimoto Y, et al. A novel classification system for patients with PTC: addition of the new variables of large (3 cm or greater) nodal metastases and reclassification during the follow-up period. *Surgery.* 2004; 135: 139-148.
- 29 Gardner RE, Tuttle RM, Burman KD, et al. Prognostic importance of vascular invasion in papillary thyroid carcinoma. *Arch Otolaryngol Head Neck Surg.* 2000; 126: 309-312.
- 30 Aboelnaga EM, Ahmed RA. Difference between papillary and follicular thyroid carcinoma outcomes: an experience from Egyptian institution. *Cancer Biol Med.* 2015; 12: 53-59.
- 31 Falvo L, Catania A, D'Andrea V, et al. Prognostic importance of histologic vascular invasion in papillary thyroid carcinoma. *Ann Surg.* 2005; 241: 640-646.
- 32 Ishiwata T, Iino Y, Takei H, et al. Tumor angiogenesis as an independent prognostic indicator in human papillary thyroid carcinoma. *Oncol Rep.* 1998; 5: 1343-1348.
- 33 Fontanini G, Vignati S, Pacini F, et al. Microvessel count: an indicator of poor outcome in medullary thyroid carcinoma but not in other types of thyroid carcinoma. *Mod Pathol.* 1996; 9: 636-641.
- 34 Akslen LA, Livolsi VA. Increased angiogenesis in papillary thyroid carcinoma but lack of prognostic importance. *Hum Pathol.* 2000; 31: 439-442.
- 35 de la Torre NG, Buley I, Wass JA, et al. Angiogenesis and lymphangiogenesis in thyroid proliferative lesions: relationship to type and tumour behaviour. *Endocr Relat Cancer.* 2006; 13: 931-944.
- 36 Salajegheh A, Pakneshan S, Rahman A, et al. Co-regulatory potential of vascular endothelial growth factor-A and vascular endothelial growth factor-C in thyroid carcinoma. *Hum Pathol.* 2013; 44: 2204-2212.
- 37 Erdem H, Gundogdu C, Sipal S. Correlation of E-cadherin, VEGF, COX-2 expression to prognostic parameters in papillary thyroid carcinoma. *Exp Mol Pathol.* 2011; 90: 312-317.
- 38 Vieira JM, Santos SC, Espadilha C, et al. Expression of vascular endothelial growth factor (VEGF) and its receptors in thyroid carcinomas of follicular origin: a potential autocrine loop. *Eur J Endocrinol.* 2005; 153: 701-709.
- 39 Pepper MS, Tille JC, Nisato R, et al. Lymphangiogenesis and tumor metastasis. *Cell and Tissue Research.* 2003; 314: 167-177.
- 40 McCarter MD, Clarke JH, Harken AH. Lymphangiogenesis is pivotal to the trials of a successful cancer metastasis. *Surgery.* 2004; 135: 121-124.
- 41 Yu XM, Lo CY, Chan WF, et al. Increased expression of vascular endothelial growth factor C in papillary thyroid carcinoma correlates with cervical lymph node metastases. *Clin Cancer Res.* 2005; 11: 8063-8069.
- 42 Lee SH, Lee SJ, Jin SM, et al. Relationships between lymph node metastasis and expression of CD31, D2-40, and vascular endothelial growth factors A and C in papillary thyroid cancer. *Clin Exp Otorhinolaryngol.* 2012; 5: 150-155.
- 43 Woliński K, Stangierski A, Szczepanek-Parulska E, et al. VEGF-C is a thyroid marker of malignancy superior to VEGF-A in the differential diagnostics of thyroid lesions. *PLoS One.* 2016; 11: e0150124.
- 44 Lang BH, Lo CY, Chan WF, et al. Classical and follicular variant of papillary thyroid carcinoma: a comparative study on clinicopathologic features and long-term outcome. *World J Surg.* 2006; 30: 752-758.
- 45 Yu XM, Schneider DF, Levenson G, et al. Follicular variant of papillary thyroid carcinoma is a unique clinical entity: a population-based study of 10,740 cases. *Thyroid.* 2013; 23: 1263-1268.
- 46 Pagano M, Tam SW, Theodoras AM, et al. Role of the ubiquitin-proteasome pathway in regulating abundance of the cyclin-dependent kinase inhibitor p27. *Science.* 1995; 269: 682-685.