



## Hereditary hemorrhagic telangiectasia with bilateral pulmonary vascular malformations – A case report

Nasledna hemoragijska teleangiektazija sa obostranim plućnim vaskularnim malformacijama

Olivera Lončarević\*, Siniša Rusović<sup>†</sup>, Marko Stojisavljević\*, Jelena Vuković\*, Goran Plavec\*<sup>‡</sup>, Slobodan Aćimović\*, Gordana Cvetković\*, Marina Petrović<sup>§</sup>

\*Clinic for Lung Diseases, <sup>†</sup>Institute for Radiology, Military Medical Academy, Belgrade, Serbia; <sup>‡</sup>Faculty of Medicine of the Military Medical Academy, University of Defence, Belgrade, Serbia; <sup>§</sup>Department of Pulmology, Clinical Centre Kragujevac, Faculty of Medicine Sciences, University of Kragujevac, Kragujevac, Serbia

### Abstract

**Introduction.** Hereditary hemorrhagic telangiectasia (HHT) also known as Osler-Weber-Rendu syndrome is an autosomal dominant disease that occurs due to vascular dysplasia associated with the disorder in the signaling pathway of transforming growth factor  $\beta$  (TGF- $\beta$ ). The clinical consequence is a disorder of blood vessels in multiple organ systems with the existence of telangiectasia which causes dilation of capillaries and veins, are present from birth and are localized on the skin and mucosa of the mouth, respiratory, gastrointestinal and urinary tract. They can make a rupture with consequent serious bleeding that can end up with fatal outcome. Since there is a disruption of blood vessels of more than one organic system, the diagnosis is very complex and requires a multidisciplinary approach. **Case report.** We reported a 40-year-old female patient with a long-time evolution of problems, who was diagnosed and treated at the Clinic for Lung Diseases of the Military Medical Academy in Belgrade, Serbia, because of bilaterally pulmonary arteriovenous malformations associated with HHT. Embolization was performed in two acts, followed with normalization of clinical, radiological and functional findings with the cessation of hemoptysis, effort intolerance with a significant improvement of the quality of life. **Conclusion.** HHT is a rare dominant inherited multisystem disease that requires multidisciplinary approach to diagnosis and treatment. Embolization is the method of choice in the treatment of arteriovenous malformations with minor adverse effects and very satisfying therapeutic effect.

### Key words:

telangiectasia, hereditary hemorrhagic; arteriovenous malformations; lung diseases; hemoptysis; diagnosis; embolization, therapeutic; treatment outcome.

### Apstrakt

**Uvod.** Hereditarna hemoragijska teleangiektazija (HHT) ili Osler-Weber-Rendu sindrom je autozomno dominantno oboljenje nastalo usled vaskularne displazije povezane sa poremećajem u signalnom putu transformišućeg faktora rasta  $\beta$  (TGF  $\beta$ ). Klinička posledica jeste poremećaj krvnih sudova u više organa, sa postojanjem teleangiektazija koje uzrokuju dilataciju kapilara i vena. Promene su prisutne od samog rođenja i lokalizovane su po koži i mukozi usne duplje, respiratornog, gastrointestinalnog i urinarnog trakta; mogu napraviti rupture sa posledičnim ozbiljnim krvarenjem koje se može završiti i smrtnim ishodom. Kako postoji poremećaj na krvnim sudovima više organskih sistema, postavljanje dijagnoze je veoma kompleksno i zahteva multidisciplinarni pristup. **Prikaz bolesnika.** Prikazali smo 40-godišnju bolesnicu sa dugogodišnjom evolucijom tegoba, dijagnostikovanu i lečenu u Klinici za pulmologiju Vojnomedicinske akademije u Beogradu, zbog bilateralnih plućnih arteriovenskih malformacija udruženih sa HHT. Urađena je embolizacija u dva akta, nakon čega je došlo do normalizacije kliničkog, radiološkog i funkcijskog nalaza, uz prestanak hemoptizija, intolerancije na napor i uz značajno poboljšanje kvaliteta života. **Zaključak.** HHT je retka, dominantno nasledna multisistemska bolest, koja zahteva multidisciplinarni pristup u dijagnostici i lečenju. Embolizacija je metoda izbora u lečenju arteriovenskih malformacija u plućima, sa neznatnim neželjenim efektima i veoma zadovoljavajućim terapijskim ishodom.

### Ključne reči:

teleangiektazija, nasledna, hemoragijska; arteriovenske malformacije; pluća, bolesti; hemoptizije; dijagnoza; embolizacija, terapijska; lečenje, ishod.

## Introduction

Hereditary hemorrhagic telangiectasia (HHT), also known as Osler-Weber-Rendu syndrome, is an autosomal dominant disease with the prevalence of 1/5,000–10,000 in general population. More common are cases in isolated populations such as the island Curacao in the Netherlands Antilles (1/1,331) with African-Caribbean population, or in isolated regions of the French Alps. The disease is rare with the population of African-Americans<sup>1,2</sup>.

It is basically a vascular dysplasia associated with disorders in the signaling pathway of transforming growth factor (TGF)  $\beta$ . TGF- $\beta$  superfamily of proteins are: TGF  $\beta$ , bone morphogenic protein (BMP) 9, BMP10 and growth differentiation factor (GDF) 2. In order to transmit the signal, it is necessary to achieve binding to the type II receptor that activates – phosphorylates the type I receptor, which further activates the complex of small mothers against decapentaplegic (SMAD) proteins (predominantly SMAD1, SMAD5 and SMAD8). This complex binds to SMAD4 and migrates to the nucleus where it works as a transcription factor for genes that play a role in the development, repairing, angiogenesis and migration of leukocytes.

Five genetic mutations that are responsible for the occurrence of HHT are described. The most common is mutation in the endoglin (ENG) gene (9q34) encoding endoglin (ENG), a glycoprotein predominantly in the TGF  $\beta$ 1 receptors on endothelial cells, which results in altered extracellular part of the proteins – receptors<sup>1–5</sup>. Activin A receptor type II (ACVRL) gene (12q11-14) encodes Alk-1 protein (activin receptor-like kinase 1) also TGF  $\beta$ 1 receptor. In about 80% of patients with HHT, one of the two mutations is present and the level of ALK-1 and ENG on the endothelial membrane is reduced. A higher incidence of pulmonary arteriovenous malformations (AVM) was noted with patients with ENG mutations, while AVMs of liver are more present in ACVRL1 subtype1.

For the last mentioned above, recent studies suggest the association of mutations in ACVRL1 with pulmonary arterial hypertension<sup>6</sup>. Mutation of the malate dehydrogenase 4 (MADH4) gene encoding SMAD 4, intracellular signaling protein of the superfamily of TGF receptors occurs in juvenile polyposis and HHT<sup>7</sup>. With this same gene it is described that the acquired and *de novo* mutations also cause disease. A correlation between the disease and mutations in the gene loci 5q31 and 7p14 also were proven, but not fully understood<sup>1,2,8</sup>.

The clinical consequence is a disorder in blood vessels in multiple organ systems whose clinical presentation suggests the diagnosis of the disease. It is characterized by the existence of telangiectasia caused by dilation of capillaries and veins, they are present from birth, localized on the skin and mucosa of the mouth, respiratory, and gastrointestinal and urinary tract. Any of these innumerable lesions can make a rupture, which rarely causes serious bleeding of upper and lower respiratory, gastrointestinal and urinary tract<sup>1–3</sup>.

Histologically, the most common are cellular infiltrates with the appearance of acute neutrophilic inflammation and vascular capillary dilatation and proliferation<sup>3</sup>.

According to the Curaçao Criteria established in 2000, the definite diagnosis should be based on at least 3 out of 4 of the following criteria: nose bleeding – spontaneous and recurrent; mucocutaneous telangiectasia, including the lips, oral cavity, fingers, and nose; the presence of internal lesions – telangiectasia AVMs, gastric-intestinal AVMs, pulmonary AVMs, cerebral AVMs, spinal AVMs; family history of the phenomena mentioned above.

The diagnosis is considered possible if 2 criteria are present, and it is unlikely in the presence of just one criterion<sup>1,2</sup>. It was found that the same criteria cannot be applied to children because they generally do not have all the manifestations of the disease demonstrated yet.

Nose bleeding and telangiectasis of skin, face and hands are first signs of the disease and they are present in about 95% of patients with HHT. Pulmonary AVMs are found in about 15–50% of these patients, in about 30–70% they are found in the liver, in 10% in the brain and in about 1% in the spinal canal. Of all the causes of pulmonary AVMs, HHT is responsible for 70–80%<sup>1,2,8</sup>.

Due to the existence of changes in the lips and facial skin, the differential diagnosis most often suspects Kaposi sarcoma.

In therapeutic terms there is no specific, causal treatment. When it is necessary, antibiotic therapy is prescribed, compensations of iron and blood transfusion are made, epistaxis can be treated with laser coagulation, a septoplasty is applied, as well as intranasal spray with an inhibitor of vascular growth factor (VGF). Anticoagulant/antiplatelet therapy is generally avoided due to the potential risk of bleeding, but it is considered that there are no absolute contraindications for the same<sup>1</sup>. Surgical treatment of excision and ligation are significant in preventing the sequelae of AVM<sup>1,2</sup>.

Embolization proved to be efficient method with only minor side effects and rare complications during many years of follow-up.

The results are evident immediately after the intervention: malformation exclusion from circulation, improving perfusion in the remaining lung tissue and the improvement of oxygenation. Over the longer follow-up after treatment, reperfusion occurs in around 10% of patients and the increase in new small pulmonary AVMs occurs in 15% of cases, other complications are rare<sup>2, 8–10</sup>. Regarding complications, the choice of embolization materials is very important because of the possibility that the material breaks off and causes thrombosis. A relatively new method, which is still being evaluated, is the use of arteriovenous (AV) occluders for closure of pulmonary AVM.

## Case report

A 40-year-old female patient with the long history of arterial hypertension, recurrent nose bleeding and occasional hemoptysis (the last 10 years) was examined in local primary health care center because of pain in the projection of arches of the ribs and symptoms of respiratory infection. Chest auscultation showed a continuous vascular murmur, paravertebrally on the level of thoracic base. Then the patient was sent to abdominal ultrasound and to abdominal multislice computer tomography

(MSCT), which showed two ovoid formations with the diameter of 23 mm in the right lower pulmonary lobe, localized posteriorly next to the pleura with intensive postcontrast activity of 160 Hounsfield Units (HU). In the left lower lobe, an identical formation next to the pleura and posterior thoracic wall, with diameter of 16 mm was found.

The patient was sent to our clinic for further diagnosis. On hospital admission we found that she had the long history of hypertension, with difficulties to tolerate physical stress in the last 2–3 years. She had frequent epistaxis since childhood and one episode of massive hemoptysis, which were undiagnosed because she did not accept further diagnostic procedures. The family history was positive for nose bleeding and telangiectasis of tongue and mouth with the patient's mother and a few other relatives on the mother's side. There was one case of death due to pulmonary hemorrhage. It was the patient's relative, age 16, and because of this the patient showed concern for her own health and the health of her children. Further treatment included the assistance of a psychologist.

On physical examination, discrete mucocutaneous telangiectasia of lips, oral mucosa, tongue, lips, and few on lower limbs were found (Figure 1).

Auscultatory paravertebrally over posterior thoracic base we found the presence of tunnel-like continual vascular murmur. Mild hypoxemia and decreased oxygen saturation were found.

Laboratory findings revealed microcytic hypochromic anemia  $4.6 \times 10^{12}/L$  red blood cell (RBC) [normal value (NV)  $4.5\text{--}6.5 \times 10^{12}/L$ ]; mean cell volume (MCV) 75.2 fL (NV 76–96 fL); mean corpuscular hemoglobin (MCH) 25.9 pg (NV 27–32 pg); red blood cell distribution width (RDW) 16.6% (NV 11.5–14.5%); Fe 5 mmol/L (NV 6.6–26 mmol/L).

MSCT contrast pulmonary angiography showed hyperdense peripheral zones in posterobasal segments of both lungs with the diameter of  $20 \times 18$  mm for the right and  $28 \times 14$  mm for the left one. After *iv* contrast, feeding and drainage blood vessels were clearly presented (Figure 2).

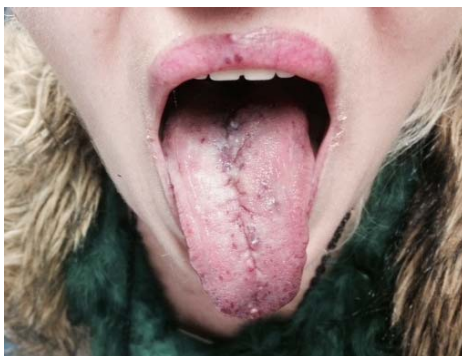

Fig. 1 – Mucocutaneous telangiectasia of the tongue and the lips.

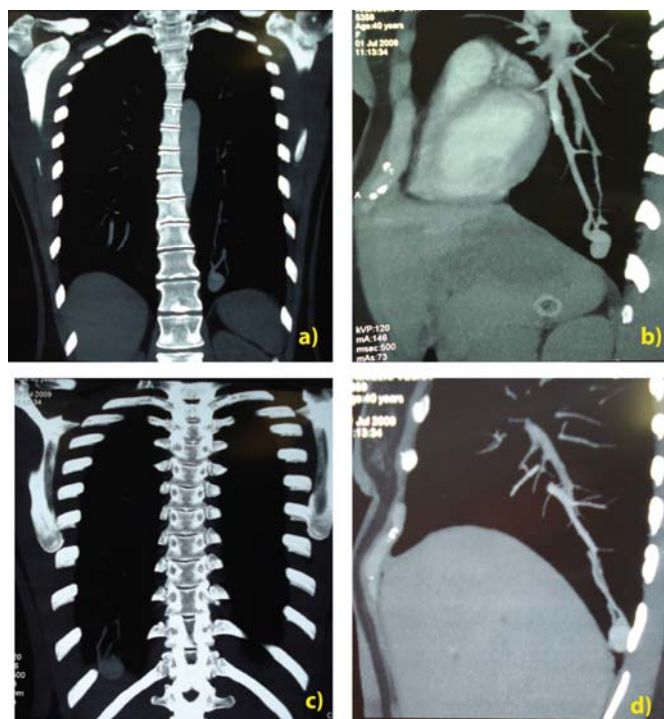


Fig. 2 – Multislice computed tomography (MSCT) contrast pulmonary angiography: a) left lower lobe arteriovenous malformation (coronal section); b) left lower lobe arteriovenous malformation (sagittal section); c) right lower lobe arteriovenous malformations (coronal section); d) right lower lobe arteriovenous malformation (sagittal section).

Screening for other manifestations of the disease was performed: MSCT angiography of endocranium did not show brain AVMs and stool testing for occult blood was negative. Echocardiography findings and morphological findings were normal, without signs of right heart load and indirect pulmonary hypertension. Based on the clinical course and performed analysis, the diagnosis was HHT with bilateral pulmonary vascular malformations.

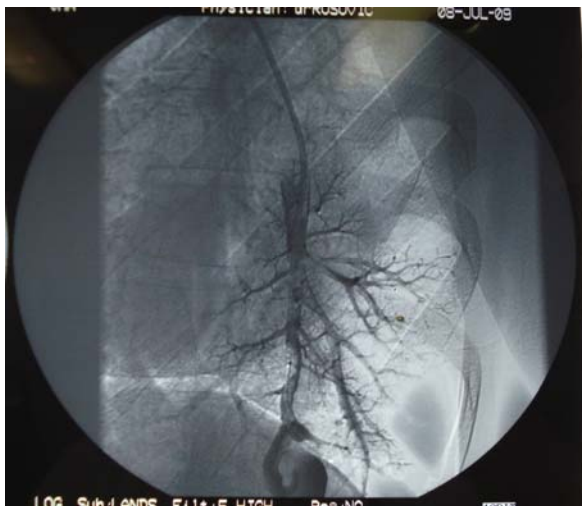Because of the proven bilateral AVMs in the lung parenchyma, it was decided to carry out the treatment of embolization. Active therapeutic approach was selected, pneumoangiography with embolisation of pathological vascular malformations was done in two acts. In the first act, AVM in the left lower lobe and feeding artery was successfully embolized with embolisation coils with dacron tails. This fistula was completely out of circulation.

Control angiography did not show drainage vein, and there was significantly better perfusion of blood vessels for the

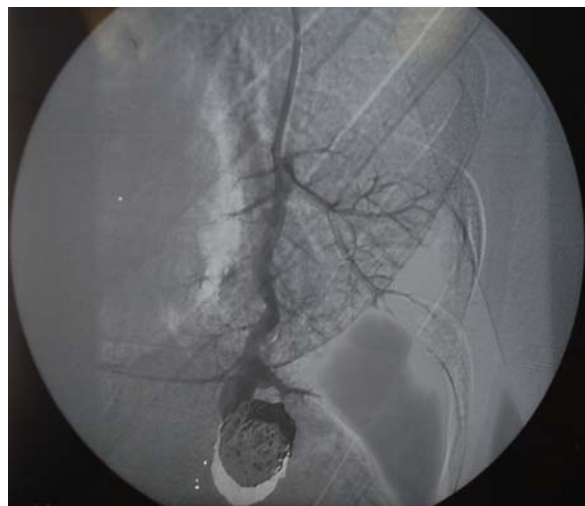left lower lobe (Figures 3–5). After a few days, the embolisation of fistula was performed on the right side of the lungs, but with partial success. Control angiography showed the presence of drainage vein. After the patient's recovery at home, AV malformation in the right lower lobe was reembolised successfully (Figure 6). After this intervention, normalization of clinical findings (the vascular murmur disappeared) and arterial blood oxygen saturation were achieved. Control hospitalization after three months, with iron supplementation therapy, showed a significant improvement in the quality of the patient's life: the patient was not bothered with physical exertion, epistaxis and hemoptysis did not repeat. The patient was without problems and returned to normal life.

### Discussion

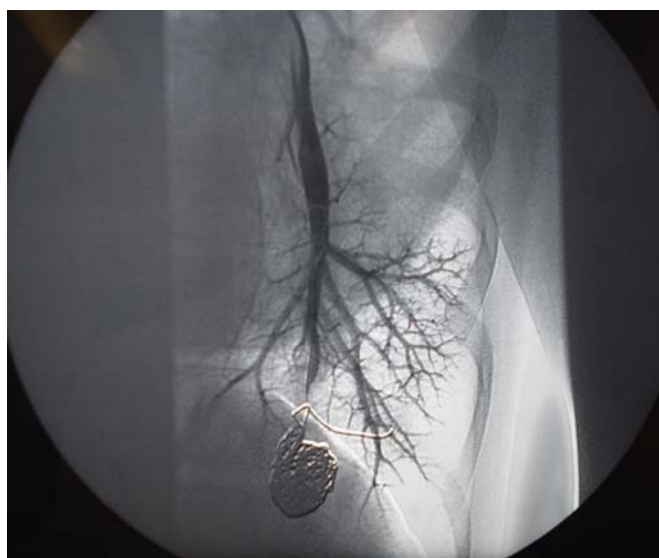After ten years of testing epistaxis, hypertension and hemoptysis, the patient was diagnosed with HHT or Osler-



**Fig. 3 – Left lower lobe arteriovenous malformation catheterization.**

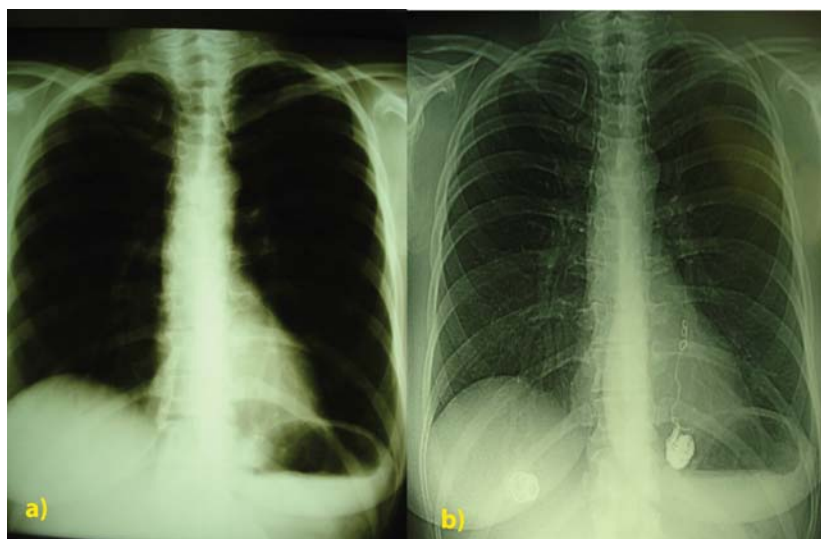


**Fig. 4 – Left lower lobe arteriovenous malformation partially embolized.**



**Fig. 5 – Left lower lobe arteriovenous malformation and feeding vessel embolized, complete out of circulation.**





**Fig. 6 – Chest x-ray findings: a) before, and b) after embolization.**

Weber-Rendu syndrome. MSCT pulmoangiography showed the existence of AVMs on both sides of the lungs, which was the cause of hemoptysis. After the disease diagnosing, due to the extensive changes on both sides of the lungs, the embolization was performed in two acts, which excluded malformations from the circulation and thus perfusion was improved, with subsequent normalization of gases of arterial blood. The patient, who had spent ten years with medical problems, was diagnosed, went through embolization, followed by normalization of clinical, functional and radiographic results, and achieved termination of problems and a significant improvement in the quality of life, and most importantly, the possibility of massive hemoptysis often resulting in death was excluded.

Embolization is the method of choice in the management of AVMs with minor complications.

### Conclusion

Hereditary hemorrhagic telangiectasia is diagnostically undervalued, doctors as well as patients and their families are not aware of the potential for screening and treatment of this disease. The consequences can be severe hemorrhage, brain infarction or death. In the present report, medical history, examination and insisting on additional diagnostics have led to the diagnosis of the disease and favorable treatment outcomes.

### R E F E R E N C E S

1. *Faughnan ME, Palda VA, Garcia-Tsao G, Geisthoff UW, McDonald J, Proctor DD, et al.* International Guidelines for the Diagnosis and Management of Hereditary Haemorrhagic Telangiectasia. *J Med Genet* 2011; 48(2): 73–87.
2. *Lessnau K.* Osler-Weber-Rendu Disease. 2014. Available from: <http://emedicine.medscape.com/article/2048472-overview> [cited 2014 June 2].
3. *Kumar V, Abbas AK, Fausto N, Aster JC.* Robbins and Cotran Pathologic Basis of Disease. 8th ed. Philadelphia PA: Saunders Elsevier; 2010.
4. *Shovlin CL, Hughes JM, Scott J, Seidman CE, Seidman JG.* Characterization of endoglin and identification of novel mutations in hereditary hemorrhagic telangiectasia. *Am J Hum Genet* 1997; 61(1): 68–79.
5. *Folkman J, D'Amore P.A.* Blood vessel formation: What is its molecular basis. *Cell* 1996; 87(7): 1153–5.
6. *Jones G, Robertson L, Harrison R, Ridout C, Vasudevan P.* Somatic mosaicism in ACVRL1 with transmission to several offspring affected with severe pulmonary arterial hypertension. *Am J Med Genet A* 2014; 164(8): 2121–3.
7. *Gallione CJ, Repetto GM, Legius E, Rustgi AK, Schelley SL, Tejpar S, et al.* A combined syndrome of juvenile polyposis and hereditary haemorrhagic telangiectasia associated with mutations in MADH4 (SMAD4). *Lancet* 2004; 363(9412): 852–9.
8. *Govani FS, Shovlin CL.* Hereditary haemorrhagic telangiectasia: A clinical and scientific review. *Eur J Hum Genet* 2009; 17(7): 860–71.
9. *Mager JJ, Overtoom TT, Blauw H, Lammers JW, Westermann CJ.* Embolotherapy of pulmonary arteriovenous malformations: long-term results in 112 patients. *J Vasc Interv Radiol* 2004; 15(5): 451–6.
10. *Ference BA, Shannon TM, White RJr, Zawin M, Burdge CM.* Life-Threatening Pulmonary Hemorrhage With Pulmonary Arteriovenous Malformations and Hereditary Hemorrhagic Telangiectasia. *Chest* 1994; 106(5): 1387–90.

Received on May 15, 2015.

Accepted on July 1, 2015.

Online First May, 2016.