

## ENCEPHALOPATHY DURING H1N1 INFLUENZA A VIRUS INFECTION

Ljiljana Nesic<sup>1</sup>, Biljana Popovska-Jovicic<sup>1</sup>, Ivana Rakovic<sup>1</sup>, Sara Petrovic<sup>1</sup>, Dusan Todorovic<sup>2</sup>, Zeljko Mijailovic<sup>1</sup><sup>1</sup>Clinic for Infectious Diseases, Clinical Centre Kragujevac, Serbia<sup>2</sup>Faculty of Medical Sciences, University of Kragujevac, Serbia

## ENCEFALOPATIJA KOD INFEKCIJE VIRUSOM INFLUENCE A PODTIP H1N1

Ljiljana Nešić<sup>1</sup>, Biljana Popovska-Jović<sup>1</sup>, Ivana Raković<sup>1</sup>, Sara Petrović<sup>1</sup>, Dušan Todorović<sup>2</sup>, Željko Mijailović<sup>1</sup><sup>1</sup>Klinika za infektivne bolesti, Klinički Centar Kragujevac, Srbija,<sup>2</sup>Fakultet medicinskih nauka, Univerzitet u Kragujevcu, Srbija

Received / Priljen: 27.06.2015.

Accepted / Prihvaćen: 27.09.2015.

## ABSTRACT

*Influenza virus type A is known for its capacity to transform its antigenic structure and create new viral subtypes. The clinical picture varies from non-febrile, mild upper respiratory tract infection to severe or fatal pneumonia. Neurological complications include encephalitis, encephalopathy, Reye's syndrome and other neurological diseases. Patients with encephalopathy exhibit a disturbed state of consciousness lasting more than 24 hours, and patients with encephalitis exhibit high temperature, focal neurological signs and pathological CSF results in addition to disturbed state of consciousness.*

*A 54-year old, previously healthy male farmer was hospitalized at the Clinic for Infectious Diseases of the Clinical Centre Kragujevac on the fifth day of disease. In addition to general symptoms of the disease, the clinical picture was dominated by a disturbed state of consciousness (Glasgow Coma Scale score <8). The aetiological agent was an H1N1 influenza A virus, which was isolated from nasopharyngeal secretions. No other causes of infection were demonstrated from both serum and cerebrospinal fluid specimens. Interstitial pneumonia was detected by radiographic examination of the chest. There were also some changes present in the EEG. The patient was cured without consequences.*

*Because our country is in a whirlwind of pandemic H1N1 virus activity, we should think of all the possible complications that this virus can produce regardless of the epidemiological data and the clinical picture.*

**Keywords:** H1N1 virus, neurological complications, diagnosis, disturbed state of consciousness.

## SAŽETAK

*Influenza virus tip A je poznat po sposobnosti menjanja antigenih struktura i stvaranja novih podtipova virusa. Klinička slika varira od nefebričnih, blagih infekcija gornjih disajnih puteva pa sve do teške ili fatalne pneumonije. Neurološke komplikacije uključuju nastanak encefalitisa, encefalopatije, Rejovog sindroma i drugih neuroloških bolesti. Kod bolesnika sa encefalopatijom, prisutan je poremećaj stanja svesti u trajanju dužem od 24 h, a kod bolesnika sa encefalitisom pored poremećenog stanja svesti prisutna je i povišena temperatura, fokalni neurološki znaci i patološki likvorski nalaz.*

*Bolesnik T.J. muškog pola, star 54 godine, prethodno zdrav, poljoprivrednik, hospitalizovan u Infektivnu kliniku KC Kragujevac petog dana bolesti. Pored opštih simptoma, kliničkom slikom dominira poremećaj stanja svesti (Glasgow Coma Scale score <8). Etiološki uzročnik je bio virus Influenze A, H1N1 koji je izolovan iz nazofaringealnog sekreta. I iz seruma i iz likvora nisu izolovani neki drugi uzročnici. Radiografskim pregledom grudnog koša nađena je intersticijalna pneumonija. Prisutne su i promene u elektroencefalogramu. Bolesnik je izlečen bez sekvela.*

*S obzirom da se i naša zemlja nalazi u pandemijskom vrtlogu infekcije virusom H1N1 treba misliti na sve moguće komplikacije koje ovaj virus može dati bez obzira na epidemiološke podatke i kliničku sliku.*

**Ključne reči:** H1N1 virus, neurološke komplikacije, dijagnoza, poremećaj stanja svesti.

## ABBREVIATIONS

CSF - cerebrospinal fluid	AST - aspart aminotransferase
EEG - electroencephalography	ALT - alanine aminotransferase
RT-PCR - reverse transcription polymerase chain reaction	a PTT - Activated Partial Thromboplastin Time
	PT - prothrombin time

UDK: 616.921.5-06; 616.831 / Ser J Exp Clin Res 2016; 17 (1): 71-75

DOI: 10.1515/SJECR-2015-0054

Corresponding author:

Ljiljana Nešić, Milovana Glišića br. 5, 34000 Kragujevac, +381642235404, E-mail: infektivnaklkg@yahoo.com



## INTRODUCTION

The H1N1 influenza A virus is an orthomyxovirus and has a segmented RNA genome (8 segments) (1). Orthomyxoviruses are very sensitive to disinfectants and antiseptics, which is very important from an epidemiological point of view. At a temperature of 54-56°C, H1N1 influenza A deteriorates for half an hour (2). Influenza virus type A is known for its capacity to transform its antigenic structure and create new viral subtypes. The most common subtype is H1N1. Swine flu is the name for the respiratory infection caused by influenza A virus subtype H1N1. This subtype represents the genetic combination of avian, human and swine flu (3). In contrast to the typical swine flu, this form of the virus is transmitted from human to human. It is spread by sneezing, coughing or touching your nose and mouth with unwashed hands. There is no evidence of the transmission of swine flu by eating pork.

The clinical picture of H1N1 infection ranges from non-febrile, mild upper respiratory tract infection to severe or fatal pneumonia. The greatest number of cases typically present with an uncomplicated seasonal flu that resolves spontaneously. Cough, fever, sore throat, fatigue and headache are registered in most of the cases (4). In a large number of patients, gastrointestinal disturbances (nausea, vomiting, and diarrhoea) can occur as well. In the majority of patients, laboratory diagnosis detects moderate leukopenia, accelerated sedimentation, increased transaminase activity and increased creatine phosphokinase (CK). C-reactive protein (CRP) and fibrinogen are within normal values, except in cases of bacterial superinfection. Characteristic radiographic changes of lung parenchyma can also occur and may not correlate with the clinical results.

A large number of authors have described the neurological complications of infection with influenza viruses A and B, but not with infection by influenza A H1N1 (5). However, a number of authors in America and especially in Japan have described neurological complications in patients who are infected with H1N1 influenza. Neurological complications include encephalitis, encephalopathy, Reye's syndrome and other neurological diseases (6). Patients with acute neurological complications had serological confirmation of a new virus and a clinical picture that was dominated by encephalopathy or encephalitis within five days of disease onset (7). Patients with encephalopathy exhibit a disturbed state of consciousness lasting more than 24 hours and patients with encephalitis exhibit a high temperature (over 38°C), focal neurological signs and pathological CSF result in addition to a disturbed state of consciousness (8). Electroencephalographic changes may be indicative of encephalitis and a pathological neuroimaging result is often present as well.

## CASE REPORT

A 54-year old, previously healthy male farmer was hospitalized at the Clinic for Infectious Diseases of the Clini-

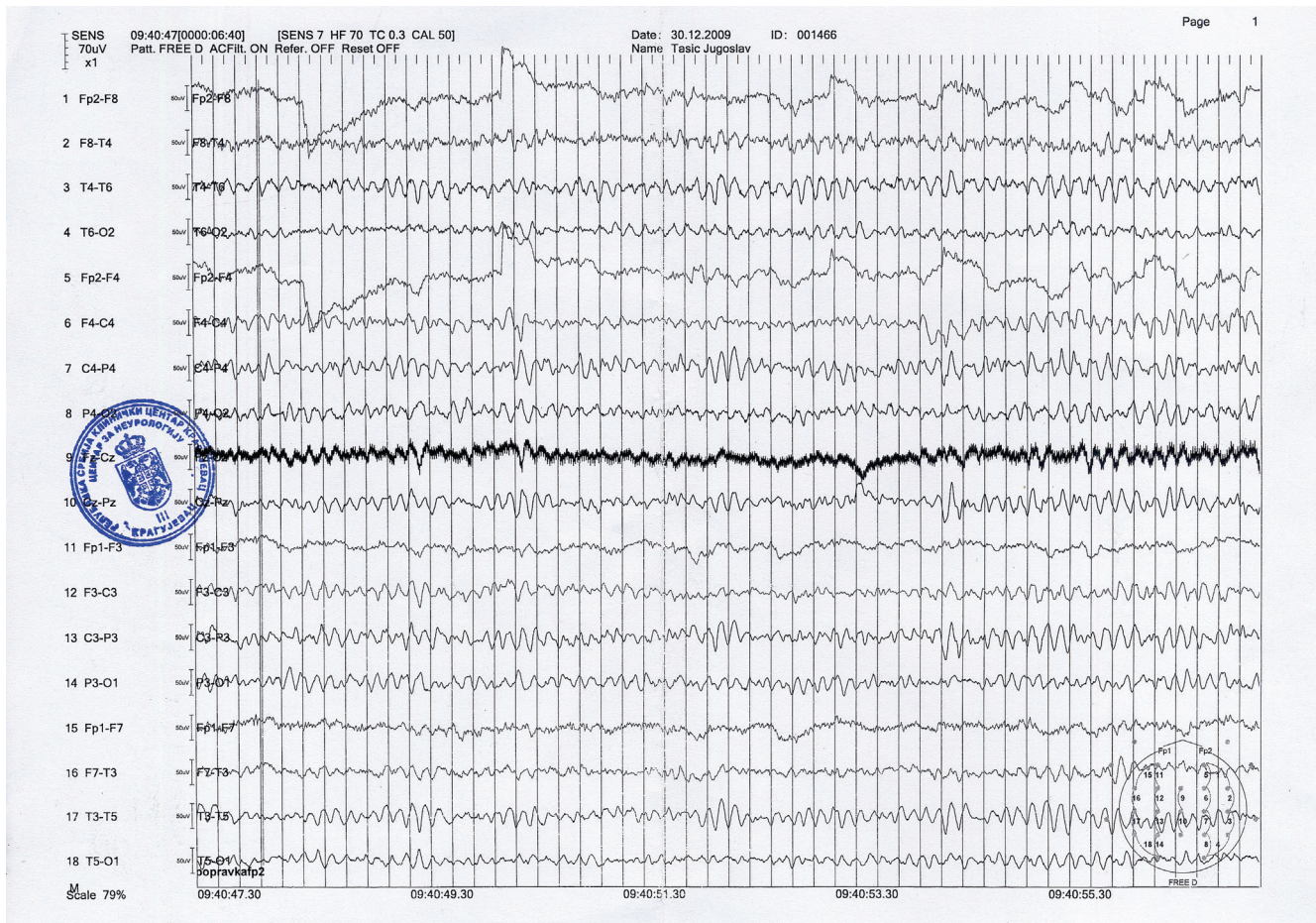
cal Centre Kragujevac on the fifth day of disease. The patient had a high temperature (over 39°C) at home for three days, accompanied by sore throat, muscle pain, extreme exhaustion and occasional dizziness. On the fourth day of the disease, his vertigo intensified and he complained of a headache at times, walked with assistance of others and developed a disturbed state of consciousness in the evening hours. The patient became confused, aggressive and uncommunicative, at which point he was referred to the neurologist of the General Hospital in Jagodina. Because his state of consciousness deepened towards the shallower state of somnolence, he was sent to the Clinic for Infectious Diseases in Kragujevac on suspicion of viral encephalitis.

On admission to the Clinic for Infectious Diseases, the patient was febrile (38.6°C), awake and disoriented in time and space and toward persons. He reacted to external stimuli but verbal communication was not established. His Glasgow Coma Scale score was 11, which indicates a moderate disturbance of the state of consciousness. The patient had tachypnea (respiratory rate 30/min.), cardiovascular stability, TA of 130/70 mmHg, and oxygen saturation of 94%. His pharynx was lightly hyperaemic and rare, bilateral inspiratory crackles were present in the lungs. Apart from a disturbed state of consciousness, other neurological as well as somatic results were within normal limits.

The following laboratory analyses were conducted on admission (reference values are given in parentheses): Er 5.46 x 10/l (4.00 - 6.00), Le 9.4 x 10/l (4.5-10.5), haemoglobin 148 g/l (110-180), Tr 240 x 10/l (150-450), SE 18 / urine b.o., fibrinogen 3.281 g/l (2.0 to 5.0), CRP 18, 0 mg/l (0.0-5.0), AST 128 IU/l (0-40), ALT 79 IU/l (0-40), CK 201 U/l (1-171), urea 3, 2 mmol/l (3.0-8.0), creatinine 79 µmol/l (49-106), glycaemia mmol/l 5.9 / 1 (3.6-6.1), ionogram within the reference values, total protein 67 g/l (64-83), albumin 42 g/l (35-52), procalcitonin <0.05 ng/ml (0.5-2.0), Pt Rec. 13.9 s (10.0-14.09), ARTT SP 27.9 s (25.0 to 35.0), D-dimer 2651 ng/ml (0-250).

Endocranial examination was conducted by magnetic resonance, and no pathological changes were observed except for reductive changes. The patient was diagnosed with viral encephalitis and a lumbar puncture was conducted. Cerebrospinal fluid (CSF) was clear with increased pressure. CSF analysis results were as follows: no cellular elements, protein 1.3 mmol/l and glucose 3.6 mmol/l. Glycaemia of 5.9 mmol/l was observed in the serum. CSF was also taken for virological diagnosis.

In the afternoon, the patient experienced cramps in certain muscle groups, entered into a deepened stage of somnolence and had a Glasgow Coma Scale score of <8, which indicated severe disturbance of the state of consciousness. He was tachypneic (respiratory rate 40/min.) and his oxygen saturation dropped to 89% in spite of continuous oxygen therapy. An anaesthesiologist was consulted and the patient was transferred to the intensive care unit due to imminent respiratory failure. Although the



**Figure 1.** Electroencephalogram showed a diffuse slowing down of waves, particularly over the right hemisphere

clinical picture was not dominated by respiratory symptomatology and epidemiological data had not linked the patient to a case of H1N1, a swab of nasopharyngeal secretions on antigen A H1N1 was taken. With the reaction binding a complement with the antigen of the influenza A H1N1 virus, a positive titre of 1/32 was obtained. RT-PCR in the serum was performed on the same virus and a positive result was obtained. An electroencephalogram was performed and it showed a diffuse slowing down of waves, particularly over the right hemisphere (Figure 1). Oseltamivir, at a dose of 150 mg / 24 h, was immediately added to the current therapy (clarithromycin 500 mg 2x 1, ciprofloxacin amp. 200 mg / 12 h, amoxiclav amp. 1,2 gr / 8 h, durofilin caps. 125 mg / 12 h, verapamil 80 mg 2x1/2, antipyretics, and, v. re-hydration). Subsequently, there was a rapid stabilization of vital functions. The patient was afebrile and his cardiocirculatory status was stable with an oxygen saturation of 98% on 21 / min. of oxygen with a mask and a TA of 150/90 mmHg. However, the patient maintained a disturbed state of mind (verbal contact was not established, and the patient was anxious, turned his head and opened his eyes when called, executed orders, and reacted violently to external stimuli and manipulation). On both sides of the lungs, bronchial breath sounds were present with basilar crackles on both sides. With the exception of qualitative disturbances of consciousness, no

other neurological disturbances were observed. CSF taken for viral diagnosis was negative for herpes simplex virus, parainfluenza virus, influenza B virus and Mycoplasma pneumoniae.

The patient responded favourably to treatment with gradual stabilization of the state of consciousness. On the eighth day of hospitalization, the patient was conscious and oriented to time and space and towards personalities. Additionally, verbal communication was adequate. The patient was discharged from the hospital on the fifteenth day of illness in good general condition and with a satisfactory state of consciousness, laboratory results within the reference values and proper chest radiography results. A repeat electroencephalogram was completed and the result was within normal values.

## DISCUSSION

Respiratory infections caused by influenza A and B viruses can cause neurological manifestations of influenza disease. However, neurological manifestations caused by influenza A H1N1 virus are very rare (9). The pandemic wave that swept through a large number of countries noted a wide variety of clinical manifestations of H1N1 infection, which is the result of its antigenic instability. The



highest percentage of patients had respiratory symptoms that ranged from mild upper respiratory tract infection to severe viral interstitial pneumonia. However, the patient presented in this report had no respiratory symptoms. In this case, the overall clinical presentation was dominated by neurological symptoms, leading to suspicion of encephalitis caused by another aetiological agent. Epidemiological data (absence of contact) did not indicate that infection with H1N1 virus was in question. However, laboratory analysis, chest radiography and CSF results indicated that this was a generalized viral infection. Serodiagnosis confirmed that infection with H1N1 virus was in question, but the presence of the virus was not detected in the cerebrospinal fluid. Serological responses in the cerebrospinal fluid were negative for herpes virus, influenza virus B, parainfluenza virus and *Mycoplasma pneumoniae*. The results of electroencephalograms and magnetic resonance examination of the endocranium also provided evidence of a generalized viral infection. The patient responded well to treatment, resulting in an improvement and stabilization of the state of consciousness on the eighth day of hospitalization. He was discharged from hospital without any consequences.

Our results correlated with data from the literature. Since the beginning of the pandemic wave caused by influenza A H1N1 virus, a rather small number of works which describe neurological manifestations caused by this virus have been published. A group of researchers from a national centre for diagnosing, monitoring and controlling infectious diseases in Texas reported seven cases of H1N1 infection associated with neurological complications (10, 11). The virus was isolated from nasopharyngeal secretions but not from CSF. This finding correlates with our data because the presence of H1N1 virus was not established in our patient's CSF. All diseased patients had severe symptoms of respiratory tract infection that were not observed in our patient. CSF results suggested a generalized viral infection that our patient exhibited. In all seven cases, the clinical picture was dominated by a disturbed state of consciousness (from confusion to somnolence) with the absence of focal neurologic disorders. These clinical manifestations were present in our patient as well. In all seven patients, the electroencephalogram result was obtained and showed a diffuse pathological slowing down, and magnetic resonance examination of the endocranium was within normal limits. All patients were treated with oseltamivir, and all were healed without consequences.

A group of Japanese authors described the neurological manifestations caused by influenza A H1N1 virus in children (12). Children are more often infected with the H1N1 virus than adults (13). All affected children were previously healthy and had flu-like symptoms. Shortly after the appearance of respiratory symptoms, focal neurologic disorders occurred accompanied by disturbances of the state of consciousness. These neurological manifestations were commonly associated with the second or

third day of disease and were correlated with the general difficult condition of the disease. Such a course of the disease in children in Japan left a number of neurological consequences and often led to death (14). It was described that in Japan, approximately 20% of children under 5 years of age who were infected with influenza A H1N1 also developed encephalopathy (13). Typical neurological signs developed 1-2 days after the onset of symptoms of influenza. Manifestations included psychotic behaviour, irritability, loss of consciousness and epilepsy seizures. In these children a complete recovery occurred in 50% of cases, while in 20% of cases the outcome was fatal.

## CONCLUSION

Studies originating from the United States, Japan and some other countries provide data on the neurological manifestations of infection with influenza A H1N1 virus, while there is a very small number of data published in our country. Because our country is in a whirlwind of pandemic H1N1 virus activity, we should think of every possible manifestation that this virus can produce regardless of the epidemiological data and the clinical picture.

## REFERENCES

1. Abdussamad J, Aris-Brosion S. The nonadaptive nature of the H1N1 2009 Swine Flu pandemic contrasts with the adaptive facilitation of transmission to a new host. *BMC Evolutionary Biology* 2011; 11: 6-8.
2. Briese T, Chowdray R, Travassos da Rosa A, et al. Upolu virus and Aransas Bay virus, Two Presumptive Bunyaviruses, Are Novel Members of the Family Orthomyxoviridae. *J Virol.* 2014 ; 88(10): 5298-5309.
3. Khatri1 M, Dwivedi1 V, Krakowka S, et al. Swine Influenza H1N1 Virus Induces Acute Inflammatory Immune Responses in Pig Lungs: a Potential Animal Model for Human H1N1 Influenza Virus. *J. Virol.* 2010; 84 (2): 11210-11218.
4. Petrosillo N, Di Bella S, Drapeau CM, Grilli E. The novel influenza A (H1N1) virus pandemic: An update. *Ann Thorac Med.* 2009; 4(4 ): 163-172.
5. González-Duarte A, Zamora LM, Brito CC, Ramos GG. Hypothalamic abnormalities and Parkinsonism associated with H1N1 influenza infection. *J Neuroinflammation.* 2010; 7: 47.
6. Hayase Y, Tobita K. Influenza virus and neurological diseases. *Psychiatry and Clinical Neurosciences* 1997; 51: 181-184.
7. Whitley R, Gnann J. Viral encephalitis: familiar infections and emerging pathogens. *Lancet* 2002; 359: 507-14.
8. Dalmau J, Lancaster E, Martinez-Hernandez E et al. Clinical experience and laboratory investigations in patients with anti-NMDAR encephalitis. *Lancet Neurol.* 2011 Jan; 10(1): 63-74.



9. Asadi-Pooza A, Yaghoubi E, Nikseresht A, Moghadami M, Honarvar B. The Neurological Manifestations of H1N1 Influenza Infection; Diagnostic Challenges and Recommendations. *Iran J Med Sci.* 2011 Mar; 36(1): 36-39.
10. Maricich SM, Neul JL, Lotze TE, et al. Neurologic complications associated with influenza A in children during the 2003-2004 influenza season in Houston, Texas. *Pediatrics* 2004;114: 626-33.
11. Dawood FS, Jain S, Finelli L, et al. Emergence of a novel swine-origin influenza A (H1N1) virus in humans. *N Engl J Med* 2009; 360: 2605-15.
12. Morishima T, Togashi t, Yokota S, et al. Encephalitis and encephalopathy associated with an influenza epidemic in Japan. *Clin Infect Dis* 2002; 35: 512-7.
13. Wada T, Morishima T, Okumura A, et al. Differences in clinical manifestations of influenza-associated encephalopathy by age. *Microbiol Immunol* 2009; 53: 83-8.
14. Ito Y, Ichiyama T, Kimura H, et al. Detection of influenza virus RNA by reverse transcription-PCR and pro-inflammatory cytokines in influenza-virus-associated encephalopathy. *J Med Virol* 1999; 58: 420-5.