



Giant primary retroperitoneal seminoma: A case report

Veliki primarni retroperitonealni seminom

Milan Jovanović*[†], Nataša Janjušević[†], Darko Mirković*[†], Maja Vulović[‡],
Boško Milev*, Miroslav Mitrović*, Bratislav Trifunović*[†]

*Clinic for General Surgery, Military Medical Academy, Belgrade, Serbia; [†]Faculty of
Medicine of the Military Medical Academy, University of Defense, Belgrade, Serbia;

[‡]Department of Anatomy and Forensic Medicine, Faculty of Medical Sciences,
University of Kragujevac, Kragujevac, Serbia

Abstract

Introduction. Primary extragonadal seminomas are rare tumors. There have been only a few cases of the primary retroperitoneal seminomas reported in the literature up to date. **Case report.** We reported a 56-year-old man with giant primary retroperitoneal seminoma presented with the enlargement of the left side of the abdomen and deep venous thrombosis of the left leg. Computed tomography of the abdomen showed a large tumor occupying the left part of the retroperitoneal space with 23 × 13 cm in diameter. Firm tumor mass having 25 × 15 cm in diameter was surgically removed from the left retroperitoneum. The tumor adhered the *tunica adventitia* of the aorta and it was carefully resected from the aortic wall. The diagnosis of seminoma was made during histopathological examination. The patient underwent chemotherapy. Two years after finished chemotherapy the patient accepted left orchiectomy with the aim of eliminating the possibility of the occult malignancy of the testicle. Histopathological analysis of the testicular tissue was normal and the diagnosis of primary retroperitoneal seminoma was confirmed. **Conclusion.** Despite its small incidence in general population, the diagnosis of retroperitoneal seminoma should be considered in male patients with nonspecific symptoms and with retroperitoneal tumor mass.

Key words:

seminoma; retroperitoneal space; venous thrombosis; diagnosis, differential; digestive system surgical procedures; orchiectomy.

Apstrakt

Uvod. Primarni vantagestisni seminomi su veoma retki tumori. U literaturi je prikazano svega nekoliko slučajeva primarnog retroperitonealnog seminoma. **Prikaz bolesnika.** Prikazali smo bolesnika, starog 56 godina, sa ogromnim primarnim retroperitonealnim seminomom, koji se javio sa uvećanjem leve polovine abdomena i dubokom venskom trombozom leve noge. Na kompjuterizovanoj tomografiji abdomena opisan je tumor veličine 23 × 13 cm. Hirurškim putem uklonjena je čvrsta tumorska masa veličine 25 × 15 cm. Tumor se prilepio za tuniku adventiciju aorte, a pažljivom resekcijom odvojen je od zida aorte. Patohistološki pregled pokazao je da se radi o seminomu. Bolesnik je primio hemioterapiju. Dve godine nakon završene hemioterapije prihvatio je hirurško uklanjanje levog testisa da bi se eliminisala mogućnost postojanja skrivenog malignog tumora testisa. Patohistološkom analizom tkiva testisa nije ustanovljeno prisustvo tumora, tako da je potvrđena dijagnoza primarnog retroperitonealnog seminoma. **Zaključak.** Kod bolesnika muškog pola sa nespecifičnom simptomatologijom i retroperitonealnom tumorskom masom treba misliti i na dijagnozu primarnog retroperitonealnog seminoma uprkos njegovoj maloj incidenciji u opštoj populaciji.

Ključne reči:

seminom; retroperitonealni prostor; tromboza, venska; dijagnoza, diferencijalna; hirurgija digestivnog sistema, procedure; orhiektomija.

Introduction

Testicular cancers are rare tumors in the general population accounting for almost 1% of all cancers in men ¹. Among them, germ cell tumors are the most common malignancies that typically arise in the testicle. However, these tumors could

primary develop extragonadally in 1–2% of all seminomas ². There have been only a few cases of the primary retroperitoneal and mediastinal seminomas reported in the literature up to date ³. In this paper we presented a patient with a rare giant primary retroperitoneal seminoma with the enlargement of the left side of the abdomen and deep venous thrombosis of the left leg.

Case report

A 56-year-old male was admitted to the Medical Military Academy due to suspected deep venous thrombosis of the left leg. The patient complained pain and the swelling of the left leg and temperature of 38.4°C. He also reported painless gradual swelling of the left half of the abdomen during the last two years, which become more severe accompanying with the sudden onset of pain that irradiated into the left lumbar region. Physical examination revealed a firm palpable mass in the left abdominal quadrants. Ultrasound examination confirmed a deep venous thrombosis in the left leg and a solid tumor mass in the abdomen, with no detectable pathological changes in the abdominal organs. Computed tomography (CT) of the abdomen with contrast enhancement showed a large tumor occupying the left part of the retroperitoneal space with 23 × 13 cm in diameter (Figure 1a, b). The tumor expanded beneath the diaphragm in front of the spine, spreading downward to the level of the inferior pole of the left kidney. The kidney was displaced cranially showing no signs of hydronephrosis, while the renal vein was partially compressed by the mass. Lower part of the tumor partially compressed the left iliac blood vessels. The tumor was in close relationship with the abdominal aorta that was also dislocated to the right (Figure 1c). Infiltration of the aortic wall in the length of 2 cm above the bifurcation by the mass was suspected. The patient underwent surgical therapy.

gonadotropin – β -HCG), that were not elevated. The testicles showed no abnormalities during physical and ultrasound examination. Concerning these findings, the urology and oncology consilium of the Medical Military Academy in Belgrade, did not suggest ipsilateral orchiectomy and the patient received three cycles of cisplatin-based chemotherapy. Two years after chemotherapy, the patient underwent left orchiectomy in another hospital. Given that histological analysis was normal, the diagnosis of the primary retroperitoneal seminoma was confirmed. The patient was followed up during the next six years. There was no relapse or metastases of the tumor.

Discussion

After the first case of extragonadal seminoma was described by Frideman⁴ in 1951, there have been only a few reports of primary seminomas located in the retroperitoneum³. Various symptoms caused by the tumor had been described in the literature. They include enlargement of the abdomen, back pain, fever, night sweats, weight loss, venous thrombosis, testicular or groin pain, hematuria, hydrocele. Due to the slow-growing nature of the tumor and nonspecific symptoms, the seminoma has already several centimeters in size at the initial diagnosis. According to the literature, an average tumor size was around 7.2 cm⁵. However, the presented patient had much larger seminoma that has been rarely reported.

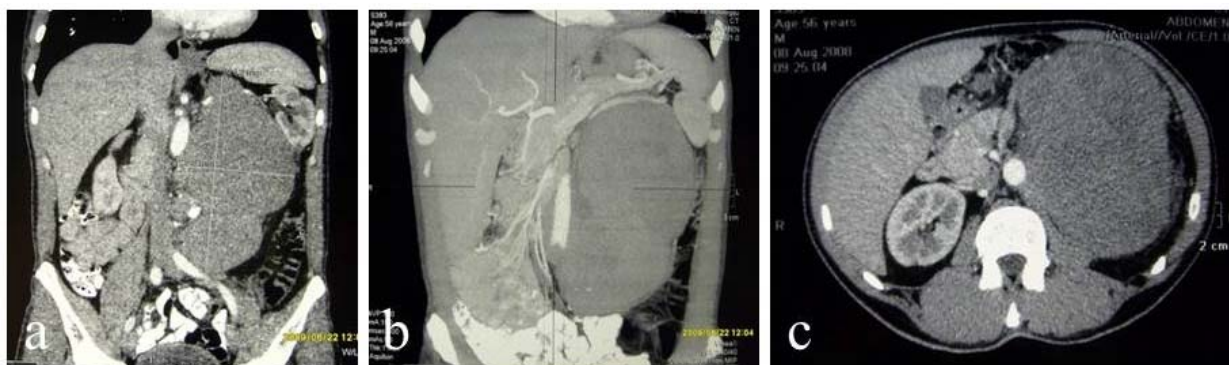


Fig. 1 – Computed tomography shows a solid nonhomogenous tumor mass in the retroperitoneum (a – frontal section), relationship with the surrounding vascular structures (b – frontal section), and the signs of aortic wall infiltration (c – axial section).

During the surgery, a firm tumor mass having 25 × 15 cm in diameter was removed from the left retroperitoneum. The small intestine, the aorta and the inferior vena cava were displaced to the right, whereas the colon descendens was pushed to the left side and partially compressed. The branches of the lumbar plexus were also compressed by the mass. The tumor adhered the *tunica adventitia* of the aorta, so that it was carefully removed from the aortic wall. This part of the aortic wall was sutured due to incomplete lesion occurred during the tumor resection. The inferior mesenteric artery was also affected and subsequently resected. The diagnosis of seminoma was made during histopathological examination. Further evaluation included biochemical analyses, lactate-dehydrogenase (LDH) and tumor markers (alphafetoprotein – AFP, beta-chorionic

Large tumor removal like in this case needs meticulous preoperative diagnostic evaluation and great attention during the surgery. The relationship between the tumor and the surrounding structures, especially with the vital organs, has to be clearly examined prior to the surgery. In this case, the seminoma was found to be adherent to the aortic wall which was not described in similar published cases. Although chemotherapy is considered the treatment of choice for huge extra-gonadal seminomas⁵, we decided to perform a combination of surgery and chemotherapy due to the tumor size and severe symptoms.

In order to confirm primary seminoma in the retroperitoneum, the presence of testicular malignancies, such as metastatic testicular carcinomas, burn-out seminomas, and primary germ cell seminomas, should be excluded. Careful ultrasound

examination is suggested since it may reveal rouge pathological changes in testicles³. However, the findings are usually not specific for the particular tumor and carcinoma *in situ* could not be detected. Although there are eight published cases of metachronous testicular tumors that appeared up to 22 years after the removal of the retroperitoneal seminoma^{2,6}, there are still no consistent suggestions whether diagnostic orchiectomy should be performed in every patient with extragonadal seminoma regardless ultrasound findings. In our case, ipsilateral orchiectomy and histopathological analysis gave the definitive diagnosis of primary retroperitoneal seminoma.

Conclusion

Although rare, the diagnosis of giant primary retroperitoneal seminoma should be considered if CT examination shows a retroperitoneal tumor mass in male patients with nonspecific symptoms. Additionally, each male patient presenting with a retroperitoneal tumor mass of unknown etiology should be examined by the urologist including evaluation of testicular tumor markers because of possible testicular tumor metastases. Surgical removal has to be performed with caution since the tumor may involve the wall of the abdominal aorta.

R E F E R E N C E S

1. Boujelbene N, Cosinschi A, Boujelbene N, Khanfir K, Bhagwati S, Herrmann E, et al. Pure seminoma: A review and update. *Radiat Oncol* 2011; 6(1): 90.
2. Patel A, Wilson L, Rane A. Primary retroperitoneal seminoma presenting with inferior vena caval obstruction. *N Z Med J* 2005; 118(1226): U1758.
3. Chiumento C, Fiorentino A, Tartarone A, Lapadula L, Cainano R, Cozzolino M, et al. A case report of retroperitoneal seminoma and literature review. *J Nucl Med Radiat Ther* 2013; 4(1): 148.
4. Friedman NB. The comparative morphogenesis of extragenital and gonadal teratoid tumors. *Cancer* 1951; 4(2): 265–76.
5. Bokemeyer C, Droz JP, Horwich A, Gerl A, Fossa SD, Beyer J, et al. Extragonadal seminoma. *Cancer* 2001; 91(7): 1394–401.
6. Hatem MA, So B. Primary retroperitoneal seminoma presented as gastrointestinal bleeding. *J Biomed Graph Comp* 2014; 4(4): 8–11.

Received on January 26, 2015.

Revised on March 20, 2015.

Accepted on March 26, 2015.

Online First April, 2015.