

SECONDARY HAEMOPHAGOCYTIC LYMPHOHISTIOCYTOSIS – THE DIFFERENTIAL DIAGNOSIS DILEMMA IN PAEDIATRICS

Rasa Medovic¹, Biljana Vuletic^{1,2}, Zorica Raskovic^{1,2}, Aleksandra Simovic^{1,2}, Jelena Nestorovic–Tanaskovic^{1,2}, Zoran Igrutinovic^{1,2}

¹Pediatric Clinic, Clinical Center Kragujevac

²Department of Pediatrics, Faculty of Medical Sciences, University of Kragujevac

SEKUNDARNA HEMOFAGOCITNA LIMFOHISTIOCITOZA – DIFERENCIJALNO–DIJAGNOSTIČKA DILEMA U PEDIJATRIJI

Raša Medović¹, Biljana Vuletić^{1,2}, Zorica Rašković^{1,2}, Aleksandra Simović^{1,2}, Jelena Nestorović–Tanasković^{1,2}, Zoran Igrutinović^{1,2}

¹Klinika za pedijatriju, Klinički centar Kragujevac

²Katedra za pedijatriju, Fakultet medicinskih nauka, Univerzitet u Kragujevcu

Received / Priljen: 1. 10. 2014.

Accepted / Prihvaćen: 29. 12. 2014.

ABSTRACT

Secondary haemophagocytic lymphohistiocytosis (SHFLH) is a rare, potentially fatal disorder, most commonly caused by the Epstein–Barr virus. It is characterized by neoplastic proliferation of cells that belong to the monocyte–macrophage system and by varied clinical expression.

A girl aged 3 years and 7 months was hospitalized due to continuing high febricity, yellow skin colouring, hepatosplenomegaly and cytopenia in a complete blood count (CBC). Four weeks before hospitalization, she had a lacunar angina and lymphadenopathy.

A low number of erythrocytes, leukocytes and thrombocytes were noted in CBC, with anaemia and the presence of virocytes in a peripheral blood smear. Biochemical blood analyses indicated hyperbilirubinaemia, increased values of transaminases, lactic dehydrogenase, ferritin, triglycerides, D–dimer, acceleration of the activated partial thromboplastin time and decreased values of fibrinogen, with increased values of C–reactive protein and procalcitonin. Using an ultrasound examination of the abdomen, hepatosplenomegaly was perceived; using echocardiographic examination, pericardium layering was noticed; and using a roentgen graphic picture of the lungs, the presence of pleural effusion was detected. In a bone marrow biopsy, the percentage of blasts did not exceed 25%, and rare chemophagocytes were noticed. Using serologic tests, positivity to Epstein–Barr virus in IgM class was demonstrated.

According to the criteria by Histiocyte Society, there were sufficient criteria to establish a diagnosis of SHFLH. With the exception of symptomatic therapies, according to the protocol for SHFLH treatment, a double antibiotic therapy and IV immunoglobulins were given, to which the patient responded with a clinical and laboratory recovery. Therefore, there was no demand for a treatment protocol with cytostatics or bone marrow transplantation.

To resolve a differential diagnosis dilemma in solving cases of uncertain febrile neutropenia.

Key words: haemophagocytic lymphohistiocytosis, Epstein–Barr virus, children

SAŽETAK

Sekundarna hemofagocitna limfohistiocitoza (SHFLH) je redak, potencijalno fatalan poremećaj, pokrenut najčešće Epstein–Barr virusom. Karakteriše se neoplastičnom proliferacijom ćelija monocitno–makrofagnog sistema i različitim kliničkim ispoljavanjem.

Devojčica uzrasta 3 godine i 7 meseci hospitalizovana zbog dugotrajne visoke febrilnosti, žute prebojenosti kože, hepatosplenomegalije i citopenije u kompletnoj krvnoj slici (KKS). Četiri nedelje pre hospitalizacije imala je lakunarnu anginu i limfadenopatiju.

U KKS je uočen nizak broj eritrocita, leukocita i trombocita, uz anemiju i prisustvo virocita u perifernom razmazu krvi. Od biohemijskih analiza krvi detektovana je hiperbilirubinemija, povećane vrednosti transaminaza, laktične dehidrogenaze, feritina, triglicerida, ubrzanje aktiviranog parcijalnog tromboplastinskog vremena, D–dimera i snižene vrednosti fibrinogena, uz povećane vrednosti parametara inflamacije (C–reaktivnog proteina i prokalcitonina). Ultrazvučnim pregledom abdomena uočena je hepatosplenomegalija, ehokardiografskim pregledom perikardno raslojavanje, a rentgenografskim snimkom pluća postojanje pleuralnog izliva. U bioptatu kostne srži procenat blasta nije prelazio 25%, a uočeni su ređi hemofagociti. Serološkim testovima dokazana je pozitivnost na Epstein–Barr virus u IgM klasi.

Prema kriterijumima udruženja Histiocyte Society, postojalo je dovoljno kriterijuma za postavljanje dijagnoze SHFLH. Pored simptomatske terapije, prema protokolu za lečenje SHFLH ordinirana je dvojna antibiotska terapija i i.v. imunoglobulini, na koje je pacijentkinja odrea govala kliničkim i laboratorijskim oporavkom. Nije zah tevala lečenje protokolima citostatika ili transplantaciju kostne srži.

Diferencijalno–dijagnostička dilema u slučaju rešavanja nerazjašnjenih febrilnih neutropenija.

Ključne reči: hemofagocitna limfohistiocitoza, Epstein–Barr virus, deca



INTRODUCTION

Histiocytoses are disorders that are characterized by unknown pathophysiological mechanisms of emergence and by neoplastic proliferation and accumulation of cells from the monocyte–macrophage system (1, 2). There are two groups of immunological cells: histiocytes, which are dendritic cells with primary antigen–presenting cell function, and macrophages, with primary phagocytic function (1). Classification of these diseases is difficult, and currently, the most reliable method is histopathological classification according to the international Histiocyte Society. The classification is accepted by the World Health Organization (1, 3). (Table 1)

Haemophagocytic lymphohistiocytosis belongs to the second class of histiocytoses and is divided into primary (familial or hereditary) and secondary form. There are no clinical or laboratory differences between these two forms of the disease. They are differentiated according to genetic examinations (4, 5).

The familial type of the disease is often comorbid with some immunodeficient conditions, such as Chédiak–Higashi syndrome, Griscelli syndrome, and X–linked lymphoproliferative syndrome. It is autosomal recessive and found in 1 in every 30 to 50 thousand newborns. Genes that encode perforin are established, and they are considered to be responsible for the expression of the primary form. These genes include PRF1, UNC13D, STX11, STXBP2 and RAB27A, which are located on the second arm of chromosome 9 and 10 (4–11).

Emergence of secondary haemophagocytic lymphohistiocytosis is primarily attributed to viruses. In approximately 70% of cases it is caused by the Epstein–Barr virus and less commonly Cytomegalovirus, Humane Herpesvirus, HIV, Parvovirus, viruses of Hepatitis A, B or C, and extremely rarely bacteria (Salmonella, Staphylococcus, Mycobacterium tuberculosis, Brucella, Leptospirosis, Rickettsia prowazekii), fungi (Candida albicans) or parasites (Leishmania). The causes of the disease can be malign, rheumatologic and autoimmune diseases (4, 5, 12–26).

The criteria for making a diagnosis of haemophagocytic lymphohistiocytosis are (presence of 5 to 8 criteria is necessary) (1, 4, 5, 27–30):

1. Temperature $>38^{\circ}\text{C}$ for five days, resistant to the application of antipyretics
2. Splenomegaly according to echosonographic criteria, depending on age and sex (31)
3. Cytopenia ≥ 2 cell lines
 - Haemoglobin (Hb) level $< 90\text{ g/l}$ (newborns < 4 weeks, $\text{Hb} < 100\text{ g/l}$)
 - Number of neutrophils (Neu) $< 1 \times 10^9/\text{l}$
 - Number of thrombocytes (Tr) $< 100 \times 10^9/\text{l}$
4. Hypertriglyceridaemia and/or hypofibrinogenaemia
 - Triglycerides $\geq 3\text{ mmol/l}$
 - Fibrinogen $\leq 1,5\text{ g/l}$
5. Hyperferritinaemia – Ferritin $\geq 500\text{ }\mu\text{g/l}$ (32, 33)
6. Serum concentration CD25 (receptor for IL–2) $\geq 2400\text{ U/ml}$ (32, 34, 35)
7. Decreased or absent activity of NK cells (35)
8. Haemophagocytosis seen through a microscope in a peripheral blood smear, bone marrow aspiration, cytological examination of liquor or biopsy of lymph node (36)

Disease prognosis is uncertain, and the treatment must be started as soon as possible, as the goal is to prevent increased inflammatory response (1, 4, 27, 30, 37).

CASE REPORT

A girl aged 3 years and 7 months was directed to the Pediatric Clinic, Clinical Centre Kragujevac because she had an increased temperature of 40°C , which lasted for two days before admission and rarely responded to the application of antipyretics (Paracetamol). Her symptoms were fatigue, loss of appetite, sickness and vomiting of undigested food content 2–3 times per day, as well as watery stools (2–3 times a day), that were light and had visible mucus. Her parents provided information that her urine was darker than normal and had a brown colour. Basic labo-

Table 1. Classification of histiocytosis

Class	Syndrome	Cell type	Diagnostic characteristics of cells
I	<u>Histiocytosis of Langerhans cells</u> (eosinophilic granuloma, Hand Schuller Christian disease, Letterer–Siwe disease)	Langerhans (dendritic) cells	Birbeck granules under electronic microscope, CD1 positive cells
II	<u>Haemophagocytic lymphohistiocytosis</u> - primary (familial) - secondary	Mononuclear phagocytes	Negative Birbeck granules and CD1, positive nonspecific esterase
III	<u>Malign diseases of histiocytes</u> Acute monocytic leukaemia (FAB M5) Real histiocytic lymphoma	Malign cells of monocytic–macrophagic composition	Malign morphologic characteristics of cells, with cell features from class II
IV	<u>Other histiocytic syndromes (benign)</u> Sinus histiocytosis with massive lymphadenopathy (Rosai–Dorfman disease) Juvenile Xanthogranuloma Reticulohistiocytoma	Mononuclear phagocytes	Negative Birbeck granules and CD1, positive nonspecific esterase



ratory analyses were performed. An examination of urine sediment, conducted using a qualitative method, albumins, urobilinogens and bilirubins were detected. Moreover, in a complete blood count, anaemia (Hb 108 g/l), leucopenia (Le $1,45 \times 10^9/l$), and thrombocytopenia (Tr $56 \times 10^9/l$) were noticed. Apart from antipyretics whilst she was highly febrile, she did not use any medications in the 3 weeks before admission.

Personal anamnesis of the child was without any specifications. Four weeks before the appearance of symptoms, the child was treated with penicillin for a period of 7 days due to the lacunar angina and the swelling of lymphatic nodes on her neck. In the family anamnesis, apart from the data regarding members of her family suffering from hypertension and diabetes mellitus type II, the presence of other hereditary degenerative diseases was negative.

During the physical examination, it was determined that the girl, body weight 16 kg, body height 106 cm and body mass index $14,29 \text{ kg/m}^2$, was conscious, highly febrile ($38,8^\circ\text{C}$), and considerably adynamic, with a subicteric tint of her skin, which showed a decrease in turgor and elasticity. Additionally, she had icteric sclera, coated tongue, slightly hyperemic pharynx, and the lymph nodes of her neck had normal dimensions for her age. She had no signs of haemorrhagic syndrome. Auscultatory findings on the heart and lungs were normal, SaO₂ 96%, number of respirations was 24/min, TA was 95/55 mmHg, and pulse was 132 beats/min. Her abdomen was not painfully sensitive during palpation. Her liver was palpated 4 cm below the rib arch and her spleen on the rib arch. Neurological findings, besides mild somnolence, were normal for her age.

Due to the serious clinical outlook and laboratory parameters, especially the decreased number of neutrophils, the girl was hospitalized in the intensive care unit in the isolation department because she was thought to have a septic condition. There, her vital functions were regularly monitored, intravenous rehydration was started, antipyretic therapy was applied every 6 hours, and to correct the intestinal flora, an antidiarrhoeal diet was introduced with a probiotic preparation.

Upon admission, initial laboratory examinations were performed. She had normal electrolyte and acid–base status. According to the complete blood count that was repeated daily during hospitalization, among pathological values, anaemia was determined (Hb 102...98...94 g/l), with a reduced number of erythrocytes (Er $3,72...3,67...3,52 \times 10^{12}/l$), perceived hypochromia Er in the peripheral blood smear, normal percentage of reticulocytes (Rtc 0,9%) and with negative direct and indirect Coombs tests. Distinct leucopenia was persistent (Le $1,4...1,4...1,9 \times 10^9/l$), with predominance of lymphocytes in the leukocyte formula (Ly $1,1...1,2...1,4 \times 10^9/l$, with 10–20% of atypical lymphocytes in the peripheral blood smear), neutropenia to agranulocytosis (neutrophils $0,25...0,18...0,34 \times 10^9/l$), as well as thrombocytopenia (Tr $44...35...46 \times 10^9/l$).

Among biochemical analyses of the blood, values of total (TBill) and conjugated (DBill) bilirubin ($72 \mu\text{mol/l}$ and $44,2$

$\mu\text{mol/l}$), values of transaminases [aspartate aminotransferase (AST) and alanine aminotransferase (ALT)] and values of lactic dehydrogenase (LDH) were increased during the hospitalization (AST 123...141 U/l, ALT 296...168 U/l, LDH 1364...1270 U/l). Additionally, we found the acceleration of activated partial thromboplastin time (aPTT 32,4...34,7 s). Fibrinogen levels were decreased, whereas there were high levels of D-dimer (fibrinogen 2,017...1,673 g/l, D–dimer 3884,49 ng/ml). Ferritin values were considerably increased, 2409 g/l. Cholesterol values, including HDL and LDL fractions, were within the limits of normal values. However, hypertriglyceridaemia was determined ($4,08 \text{ mmol/l}$). Additionally, hypoalbuminaemia was determined (albumins 22 g/l). Values of glycaemia, urea, creatinine and uric acid were in the referential scope.

Increased values of the following inflammation parameters were detected that persisted in the following days: sedimentation of erythrocytes (SE) 15 mm/lh, C–reactive protein (CRP) 50,2...22,2 mg/l and procalcitonin (PCT) 2,910...1,780 ng/ml [which demanded detailed bacteriological swabs of pharynx and nose, antistreptolysin titre (ASOT), two blood cultures and urinculture] and virological examinations (Cytomegalovirus, Epstein–Barr virus, HIV, Toxoplasma gondii, Hepatitis A, B and C, and *Mycoplasma pneumoniae*).

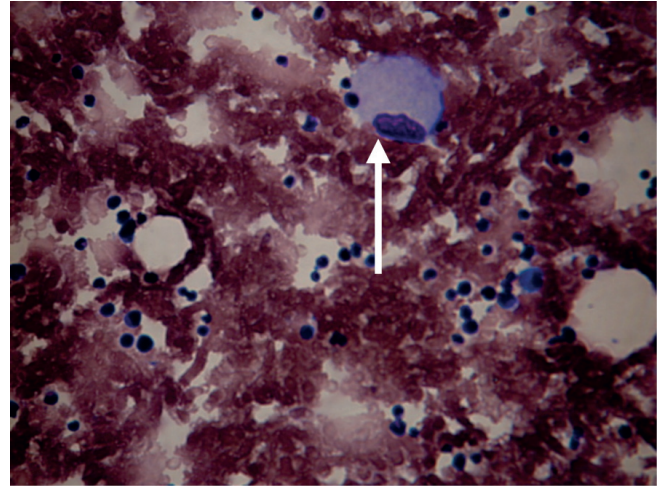
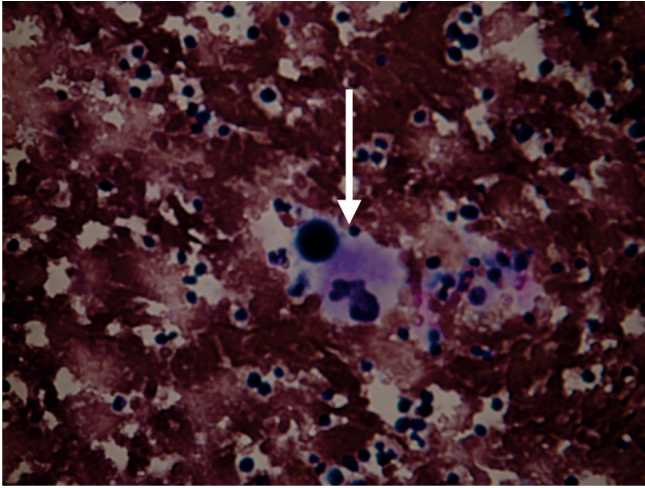
Considering the diagnosis of febrile neutropenia, it was necessary to include a double empirical antibiotic therapy. Therefore, cephalosporin of the third generation was applied – Ceftazidime, with Aminoglicozide and Amikacin (38–40).

Values of immunoglobulin fractions (IgA, IgM, IgG), as well as of the component complements (C3 and C4) were within the limits of referential values for that age.

Using an ultrasound examination of the abdomen, the presence of hepatomegaly (anteroposterior diameter of right lobe 116 mm) and splenomegaly (cranio–caudal diameter 106 mm) were determined, according to the table of normal dimensions for the patient's age and sex (31).

Bone marrow aspiration was performed, and using the microscopic examination of aspirate, cellularity of III–IV degree was determined along with evident productive megakaryocytes and all forms in the development of red and white blood cells. The percentage of blast did not exceed 25%. After 3 days of hospitalization, bone marrow aspiration was repeated and a detailed microscopic examination showed rare haemophagocytes in several places (Pictures 1A. and 1B.). Both peripheral blood and bone marrow aspirate samples were collected for flow cytometry, which was not performed due to technical reasons.

Although the therapy was applied, during the first 3 days, the girl was still highly febrile ($39,5^\circ\text{C}$), inactive, had a loss of appetite, and her skin, visible mucus, urine and stool were slightly discoloured. Furthermore, she suffered from tachydyspnea, with a number of respirations reaching 36/min. She developed a dry and sensitive cough, in bases with weak, quiet breathing sound during auscultations more to the left side, and low oxygen saturations,



Pictures 1A and 1B. Haemophagocytosis in the preparation of bone marrow aspirate

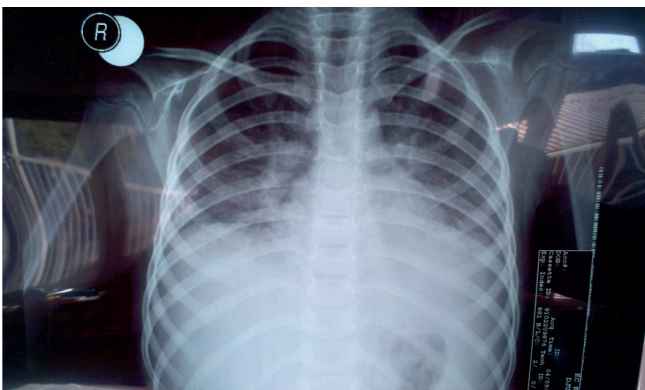
SaO₂ 91–92%. Therefore, roentgenography of the lungs (RTG) was conducted. Paramediastinally zones of consolidations of lung parenchyma with a tendency to merge were noticed on images. A shadow of effusion in the left costophrenic angle up to the level of the fifth rib was also noticed. A repeated recording of the following day showed that the condition was progressing (Pictures 2A and 2B). In light of this, considering the possibility of the emergence of more serious nosocomial infections, current antibiotic therapy was changed, and secondary antibiotics were given according to the protocol– Meropenem and Vancomycin, with antimycotic Fluconazole, and considering an atypical cause of pneumonia, Azithromycin was also applied (38–42).

Moreover, due to the quiet heart tones during auscultation, electrocardiographic examination (the finding was normal for her age), and laboratory observation of heart enzymes [troponin I, creatine kinase (CK) and CK MB, and N-terminal beta natriuretic peptide (NTproBNP) were all within the limits of referential values) were performed. However, at the echocardiographic examination, besides normal heart morphology and contractility, and an ejection fraction of 66%, light tricuspid regurgitation and hy-

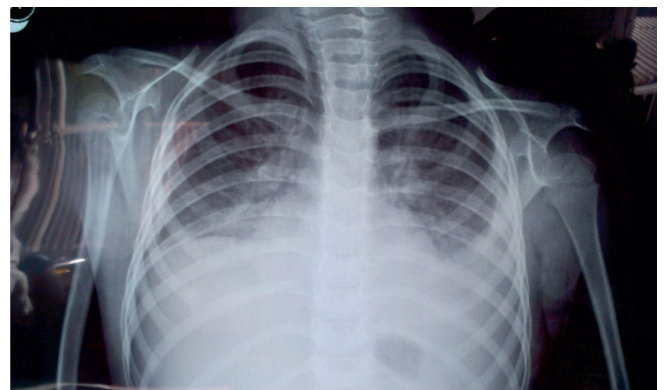
perechogenicity of the pericardium were determined, with minimal layering of the visceral and parietal leaf of 3 mm.

After placement onto the surface, the results of sterile blood cultures and urinculture were ready. The presence of normal flora in the nose and pharynx swab was determined, and ASOT were in the limits of referential values. However, virological analyses proved seronegativity to all considered viruses, except for a highly positive titre to Epstein–Barr virus in the IgM class and a less positive one in the IgG class. Therefore, it was confirmed that infection 4 weeks before hospitalization, which was regarded as lacunar angina and treated with beta lactam antibiotics, was actually infective mononucleosis. These findings led to a suspicion that the girl suffers from secondary haemophagocytic lymphohistiocytosis (SHFLH), which was caused by the Epstein–Barr virus.

According to the treatment protocol for SHFLH (43), IV immunoglobulins were introduced in the therapy. The girl was directed to the referential institution, Institute of Mother and Child Care “Dr Vukan Čupić” in Novi Beograd, due to additional medical diagnoses and possible treatment with cytostatic protocol and/or a possible need for bone marrow transplantation.



Picture 2A. RTG lung 04.09.2013.



Picture 2B. RTG lung 05.09.2013.



During hospitalization at the Institute, there was a spontaneous, steady, both clinical and laboratory recovery of the child, with the application of only symptomatic therapy (the continuation of antibiotic therapy started in Clinical Center Kragujevac and IV rehydration). Therefore, IV immunoglobulin therapy, to which the girl adequately responded, was most likely sufficient. She became afebrile, in better general state, regained her appetite, and there was no more colouring of the skin and mucus. The number of cell lines in CBC was normalized, as well as the biochemical analyses of the blood. With such a condition of the child, bone marrow aspiration was not repeated. On the roentgen graphic picture of lungs it was determined that the finding is in considerable regression with no signs of pulmonary parenchymal consolidation, but with the persistence of a small shadow of pleural effusion in the right costophrenic angle. In the ECHO examination of the heart, the presence of an increased amount of pericardium fluid was not determined. Moreover, in the ECHO examination of abdomen, persistence of splenomegaly was determined, with considerably decreased values (cranial–caudal diameter of 96 mm) and no hepatomegaly (anteroposterior diameter of the right lobe 103 mm). A parameter that is also in favour of a SHFLH diagnosis is soluble anti CD25, whose values were increased over 2400 U/ml.

Due to technical reasons, the activity of NK cells were not determined, and genetic examinations of the primary form of the disease were not undertaken because these analyses are not performed in the Republic of Serbia.

Since then, the girl has been in a good general state with regular physical findings and normal laboratory analyses. She is submitted for regular examinations by the haematologist in charge.

DISCUSSION

Haemophagocytic lymphohistiocytosis was first described in 1939 as histiocytic medullary reticulosis (44). In 1952, a familial type of the disease in two newborn twins was described (45), and 1965 after the simultaneous development of the disease in father and son, it was thought that infection can be important in the pathogenesis of the disease (46). The hereditary form usually emerges until 4 years of age, and according to some authors even until the second year of age. In the cases of anamnesticly known and/or proven infection 3–4 weeks before the beginning of the disease, the secondary form should be considered. In the cases where there are relatives with the same disease, the familial form should be considered. However, it is often the case that the hereditary form is initiated by some viral influences (47). The primary form is found together with some immunodeficient conditions, whilst it is typical for the secondary form to emerge in children with a normal immunological status, which was the case with our female patient. The secondary form may develop into a spontaneous remission, whilst the primary form always necessitates

the application of therapy. Treatment is identical for both forms, which are potentially fatal diseases, and poor prognosis and higher mortality rate are typical of the primary form (1, 29, 30, 48–51).

The Epstein–Barr virus is thought to be responsible for the emergence of secondary haemophagocytic lymphohistiocytosis in approximately 70% of cases. The mechanism of disorder in the proliferation of cytotoxic and helper T lymphocytes is unknown. However, a similar monoclonal proliferation of T lymphocytes was determined in those patients suffering from secondary haemophagocytic lymphohistiocytosis and in EBV+ T cell lymphoma (52). The consequence is a hyper production of proinflammatory cytokines, especially interferon γ , cell factors, tumour necrosis factor α and of various interleukins (IL – 1, 6, 16, 18), decreased inactivation of NK cell functions and to hyper activation and accumulation of macrophages (12, 29, 30, 38, 48–50, 53).

Clinical signs that may indicate the presence of haemophagocytic lymphohistiocytosis are nonspecific. Commonly, high temperature $>38^{\circ}\text{C}$ and fever (in 80% of patients), with a considerably bad general state (fatigue, sleepiness, refusal to eat) are evident. The highly febrile state lasts for several days and is resistant to antipyretics, which was the case with our patient. Sickness, vomiting, and watery stools before hospitalization can be attributed to the general bad condition of the child, to the increase in intra–abdominal pressure due to hepatosplenomegaly and to the influence of mediator released from the monocyte–macrophage system to the cell function of gastrointestinal tract. The girl did not have a generalized lymphadenopathy, that is, besides splenomegaly (in 60%) and hepatomegaly (50%), described in 40% of cases as one of the signs of the diseases (1, 12, 27–30, 37, 50, 51, 54, 55). A common sign that is mentioned is rash, with visible marks on the skin (35–65%), as well as neurological symptomatology in the sense of somnolence, meningismus, ataxia, and even convulsions and epileptic attacks (30%) (56, 57).

Yellow colouring of the skin, a visible mucous membrane, lighter stool and dark coloured urine, and the presence of urobilinogens and bilirubins in the urine indicated hyperbilirubinaemia, which was confirmed in laboratory. The origin of hyperbilirubinaemia and comorbid hepatosplenomegaly was examined. Firstly, a possibility of the existence of a stronger haemolysis of erythrocytes in the enlarged spleen was eliminated by determining the number of Er in CBC, the percentage of reticules in peripheral blood, as well as, direct and indirect Coombs tests. Increased values of transaminases and lactic dehydrogenase indirectly indicated a necrosis of hepatocytes, whilst acceleration of the activated partial thromboplastin time and decreased values of fibrinogens with high values of D–dimer pointed to the decreased synthetic liver function.

In addition to anaemia and thrombocytopenia, in CBC, leucopenia persisted, with a predominance of lymphocytes in leukocyte count, with 10–15% of atypical lymphocytes (so called virocytes), which indicated that it is a viral in-



Table 2. Clinical and laboratory criteria for establishing the diagnosis

Criteria for establishing the diagnosis (7 out of 8)	Auxiliary criteria
1. Temperature above 38,5°C for 9 days 2. Splenomegaly (106 mm) 3. Cytopenia ≥ 2 cell lines Haemoglobin 98 g/l Neutrophils $0,25 \times 10^9/l$ Thrombocytes $45 \times 10^9/l$ 4. Hypertriglyceridaemia and/or hypofibrinogenaemia Triglycerides 4,08 mmol/l 5. Ferritin 2409 $\mu\text{g/l}$ 6. Haemophagocytosis in bone marrow 7. Soluble anti CD25 (receptor for IL-2) ≥ 2400 U/ml	1. IgM EBV positive 2. Pleuritis, pericarditis 3. Decreased values of fibrinogen 4. Increased values of transaminases 5. Increased values of bilirubin 6. Accelerated aPTT 7. Increased values of D-dimer 8. Increased values of LDH 9. Hypoalbuminaemia 10. Hepatomegaly

fection, as well as neutropenia to agranulocytosis. Anamnesic data on non-usage of drugs or on the exposition to toxic materials in the last 3 weeks excluded a possibility of bone marrow aplasia caused by these substances (58).

To exclude the possibility of the emerging malignant haemopathies, in a peripheral blood smear, as well in a microscopic examination of bone marrow biopsy, over 25% developing forms of such cells were not found (59). Moreover, as tumour markers, values of ferritin were increased. However, besides the role of a tumour marker, ferritin was, in this case, considered as an index of inflammation and liver function (60). Additionally, normal levels of uric acid, which is a marker of increased cell degradation of tumour cells (59), were detected. Using an ultrasound examination of the abdomen, the existence of retroperitoneum enlarged lymph cords was not determined. Unfortunately, flow cytometry was not performed due to technical reasons.

Because the girl was regularly vaccinated and had a BCG mark of 3 mm, normal immunological status, was from a good socioeconomic environment, with no evidence of living in a collective group or a possible contact with tuberculosis, the possibility of tuberculosis pleural effusions was not considered. Before and during hospitalization, there was no neurological symptomatology in the female patient apart from light sleepiness that is a consequence of a complete bad condition and high temperature. Therefore, there was no need for diagnostic lumbar puncture, which is also in the diagnostic protocol for SHFLH (30, 37, 50, 51, 56, 57).

The results of sterile blood cultures and urinoculture, which revealed normal flora from the swab of the nose and pharynx and ASOT that was in the limits of referential values, excluded a possibility of a septic state caused by bacterial infection. With a confirmed seronegativity to all considered viruses, except for highly positive titre to Epstein-Barr virus in the IgM class, it was thought that the girl had a case of haemophagocytic lymphohistiocytosis (SHFLH).

To establish a final diagnosis, values of triglycerides that were increased were considered, as well as the values of albumins (according to Huang et al (61), decreased values of albumin will be another criteria for establishing a diagnosis for SHFLH, and it is a good predicative param-

eter of the disease). Hypertriglyceridaemia and hypoalbuminaemia cannot be considered as the cause of pleural and pericardium effusion, with the emergence of chylothorax in the first, or the decrease in colloid-osmotic pressure of plasma in the second case, but the effusion is most surely a consequence of aseptic serositis, i.e., influence of mediator to epithelial cells of pleura and pericardium and their increased secretion (62–64). Moreover, bone marrow aspiration was performed once more, and a detailed and targeted microscopic search of biopsies revealed rare haemophagocytes in several places.

The clinical and laboratory criteria are summarized in table 2. According to international Histiocyte Society, these criteria as well as the auxiliary diagnostic criteria that we also followed in solving differential diagnosis dilemmas are used to diagnose SHFLH (1, 4, 5, 27–30).

Prognosis of the disease is uncertain, and it depends on the age and immunological status of the patient, degree of organs affected, dissemination of the disease, speed of establishing a diagnosis and the response to therapy. The disease can end with a spontaneous recovery, adequate curative treatment, or it could also result in rapid and progressive death, regardless of the applied therapy. Spontaneous recovery is expected in 20–30% of the patients. With an adequate symptomatic and immunosuppressive treatment, recovery is expected in 60–70% of the patients. That percentage is higher after bone marrow transplantation. The mortality rate, depending on the studies, is approximately 25–60% of patients (1, 4, 12, 13, 50, 51, 65–68).

Apart from the symptomatic therapy (IV rehydration with the correction of electrolytic and acid-base status, antipyretics, oxygen therapy, adequate care and diet, transfusion of deplasmatisized erythrocytes and concentrated thrombocytes, antibiotics and antimycotics), immunosuppressive and immunomodulatory therapy are performed (corticosteroids, immunoglobulins, antithymocytic globulin, cyclosporine A) as well as various protocols with cytostatics (initial cytostatic therapy – Etoposide, intrathecal methotrexate, with corticosteroids, and continuous cytostatic therapy – same medications in smaller dosages, according to the treatment protocol suggested by Histiocyte society). As a final measure, allogenic transplantation of bone marrow is suggested (27, 30, 37–43, 68–71). Some



studies have shown efficiency in the application of biologic therapy (72). Antiviral medications (e.g., Acyclovir) do not have significance in the treatment (12, 13, 27, 30).

In our example, besides the applied symptomatic and antibacterial therapy, a therapy with IV immunoglobulins was sufficient, and it is described in the works of other authors (43, 66–68).

Based on the facts reported herein, we can conclude that although hemophagocytic lymphohistiocytosis is a rare disease, one should be aware of it, especially in clinically uncertain conditions, such as in cases of febrile cytopenia, when the patients do not respond to the application of standard symptomatic therapy. Timely diagnosis offers higher chances for survival, with a timely beginning of immunosuppressive, immunomodulatory therapy and possible bone marrow transplantation.

REFERENCES

- Lipton JM, Arceci RJ. Histiocytic disorders. In: Hoffman R, Edward B, eds. Hematology: basic principles and practice. 4th ed. Philadelphia: Churchill Livingstone. 2005; 857–67.
- Ladisch S. Histiocytosis syndrome in childhood. In: Behrman ER, Kliegman MR, Jenson BH. NELSON Textbook of pediatrics, vol 2, 17th ed. Belgrade: Saunders, Bard 2009; 1727–30. (translated)
- Favara BE, Feller AC, Pauli M et al. Contemporary classification of histiocytic disorders. The WHO Committee On Histiocytic/Reticulum Cell Proliferations. Reclassification Working Group of the Histiocyte Society. *Med Pediatr Oncol.* 1997; 29(3): 157–66.
- Verbsky JW, Grossman WJ. Hemophagocytic lymphohistiocytosis: diagnosis, pathophysiology, treatment, and future perspectives. *Ann Med.* 2006; 38(1): 20–31.
- Janka GE. Familial and acquired hemophagocytic lymphohistiocytosis. *Annu Rev Med.* 2012; (63): 233–46.
- Feldmann J, Le Deist F, Ouachée-Chardin M et al. Functional consequences of perforin gene mutations in 22 patients with familial haemophagocytic lymphohistiocytosis. *Br J Haematol.* 2002; 117(4): 965–72.
- Feldmann J, Callebaut I, Raposo G et al. Munc 13–4 is essential for cytolytic granules fusion and is mutated in a form of familial hemophagocytic lymphohistiocytosis (FHL3). *Cell.* 2003; 115(4): 461–73.
- Ohadi M, Lalloz MR, Sham P et al. Localization of a gene for familial hemophagocytic lymphohistiocytosis at chromosome 9q21.3–22 by homozygosity mapping. *Am J Hum Genet.* 1999; 64(1): 165–71.
- Dufourcq-Lagelouse R, Jabado N, Le Deist F et al. Linkage of familial hemophagocytic lymphohistiocytosis to 10q21–22 and evidence for heterogeneity. *Am J Hum Genet.* 1999 Jan; 64(1): 172–9.
- Stapp SE, Dufourcq-Lagelouse R, Le Deist F et al. Perforin gene defects in familial hemophagocytic lymphohistiocytosis. *Science.* 1999; 286(5446): 1957–9.
- Kogawa K, Lee SM, Villanueva J, Marmer D, Sumegi J, Filipovich AH. Perforin expression in cytotoxic lymphocytes from patients with hemophagocytic lymphohistiocytosis and their family members. *Blood.* 2002; 99(1): 61–6
- Ansuini V, Rigante D, Esposito S. Debate around infection-dependent hemophagocytic syndrome in pediatrics. *BMC Infect Dis.* 2013; (13): 13–15.
- Fisman DN. Hemophagocytic syndromes and infection. *Emerg Infect Dis.* 2000; 6(6): 601–8.
- Janka G, Imashuku S, Elinder G, Schneider M, Henter JL. Infection- and malignancy-associated hemophagocytic syndromes. Secondary hemophagocytic lymphohistiocytosis. *Hematol Oncol Clin North Am.* 1998; 12(2): 435–44.
- Danish EH, Dahms BB, Kumar ML. Cytomegalovirus-associated hemophagocytic syndrome. *Pediatrics.* 1985; 75(2): 280-3.
- Bhatia S, Bauer F, Bilgrami SA. Candidiasis-associated hemophagocytic lymphohistiocytosis in a patient infected with human immunodeficiency virus. *Clin Infect Dis.* 2003; 37(11): 161–6.
- Watanabe T, Okazaki E, Shibuya H. Influenza A virus-associated encephalopathy with haemophagocytic syndrome. *Eur J Pediatr.* 2003; 162(11): 799–800.
- Kaya Z, Oztürk G, Gürsel T, Bozdayi G. Spontaneous resolution of hemophagocytic syndrome and disseminated intravascular coagulation associated with Parvovirus B19 infection in a previously healthy child. *Jpn J Infect Dis.* 2005; 58(3): 149–51.
- Tuon FF, Gomes VS et al. Hemophagocytic syndrome associated with hepatitis A: case report and literature review. *Rev Inst Med Trop Sao Paulo.* 2008; 50(2): 123–7.
- Brastianos PK, Swanson JW, Torbenson M, Sperati J, Karakousis PC. Tuberculosis-associated haemophagocytic syndrome. *Lancet Infect Dis.* 2006; 6(7): 447–54.
- Cascio A, Giordano S, Dones P, Venezia S, Iaria C, Zii-no O. Haemophagocytic syndrome and rickettsial diseases. *J Med Microbiol.* 2011; 60(Pt 4): 537–42.
- Gosh JB, Roy M, Bala A. Infection associated with Hemophagocytic Lymphohistiocytosis triggered by nosocomial infection. *Oman Med J.* 2009; 24(3): 223–5.
- Cascio A, Pernice LM et al. Secondary hemophagocytic lymphohistiocytosis in zoonoses. A systematic review. *Eur Rev Med Pharmacol Sci.* 2012; 16(10): 1324–37.
- Gagnaire MH, Galambrun C, Stéphan JL. Hemophagocytic syndrome: a misleading complication of visceral leishmaniasis in children – a series of 12 cases. *Pediatrics.* 2000; 106(4): E58.
- Onishi R, Namiuchi S. Hemophagocytic syndrome in a patient with rheumatoid arthritis. *Intern Med.* 1994; 33(10): 607–11.
- Wong KF, Hui PK, Chan JK, Chan YW, Ha SY. The acute lupus hemophagocytic syndrome. *Ann Intern Med.* 1991; 114(5): 387–90.



27. Henter JL, Horhe A, Arico M et al. HLH–2004: Diagnostic and therapeutic guidelines for hemophagocytic lymphohistiocytosis. *Pediatr Blood Cancer*. 2007; 48(2): 124–31.
28. Henter JL, Elinder G, Ost A. Diagnostic guidelines for hemophagocytic lymphohistiocytosis. The FHL Study Group of the Histiocyte Society. *Semin Oncol*. 1991; 18(1): 29–33.
29. Rosado FG, Kim AS. Hemophagocytic lymphohistiocytosis: an update on diagnosis and pathogenesis. *Am J Clin Pathol*. 2013; 139(6):713–27.
30. Tang YM, Xu XJ. Advances in hemophagocytic lymphohistiocytosis: pathogenesis, early diagnosis/differential diagnosis, and treatment. *Scientific World Journal*. 2011; 11: 697–708.
31. Konuş OL, Ozdemir A, Akkaya A, Erbaş G, Celik H, Işık S. Normal liver, spleen and kidney dimensions in neonates, infants, and children: evaluation with sonography. *AJR Am J Roentgenol*. 1998; 171(6): 1693–8.
32. Rademacher C, Hartmann D, Spiethoff A, Jakobs R. Ferritin and soluble interleukin–2–receptor in the diagnosis of fever of unknown origin. *Dtsch Med Wochenschr*. 2014; 139(1-2): 23–7.
33. Lehmborg K, McClain KL, Janka GE, Allen CE. Determination of an appropriate cut-off value for ferritin in the diagnosis of hemophagocytic lymphohistiocytosis. *Pediatr Blood Cancer*. 2014 Apr 21. [Epub ahead of print] PubMed PMID: 24753034.
34. Imashuku S, Hibi S et al. Soluble interleukin-2 receptor: a useful prognostic factor for patients with hemophagocytic lymphohistiocytosis. *Blood*. 1995; 86(12): 4706–7.
35. Wang LL, Hu YX, Chen WF et al. Significance of soluble interleukin-2 receptor and NK cell activity in patients with hemophagocytic lymphohistiocytosis. *Zhongguo Shi Yan Xue Ye XueZaZhi*. 2012; 20(2): 401–4.
36. Sloma I, Vincent H, Addebous A, Rivoisy C, Turhan GA, Michot JM. Haemophagocytic histiocyte in a peripheral blood film. *Br J Haematol*. 2014; 165(2): 163.
37. Jabado N, McCusker C, Basile Gde S. Pediatric hemophagocytic syndromes: a diagnostic and therapeutic challenge. *Allergy Asthma Clin Immunol*. 2005; 1(4): 142–60.
38. Kobayashi S, Ito M, Sano H et al. Clinical analysis of combination therapy for febrile neutropenic patients in childhood cancer. *Pediatr Int*. 2013; 55(1): 65–71.
39. Raghavendra M, Hoeg RT, Bottner WA, Agger WA. Management of neutropenic fever during a transition from traditional hematology/oncology service to hospitalist care. *WMJ*. 2014; 113(2): 53–8.
40. Hung KC, Chiu HH, Tseng YC et al. Monotherapy with meropenem versus combination therapy with ceftazidime plus amikacin as empirical therapy for neutropenic fever in children with malignancy. *J Microbiol Immunol Infect*. 2003; 36(4): 254–9.
41. Biondi E, McCulloh R, Alverson B, Klein A, Dixon A, Ralston S. Treatment of Mycoplasma Pneumonia: A Systematic Review. *Pediatrics*. 2014; 133(6):1081–90.
42. Aytaç S, Yildirim I, Ceyhan M et al. Risks and outcome of fungal infection in neutropenic children with hematologic diseases. *Turk J Pediatr*. 2010; 52(2): 121–5.
43. Rajajee S, Ashok I, Manwani N, Rajkumar J, Gowrishankar K, Subbiah E. Profile of Hemophagocytic Lymphohistiocytosis; Efficacy of Intravenous Immunoglobulin Therapy. *Indian J Pediatr*. 2014 May 9. [Epub ahead of print] PubMed PMID: 24806152.
44. Scott R, Robb-Smith A. Histiocytic medullary reticulosis. *Lancet*. 1939; (2): 194–8.
45. Farquhar J, Claireaux A. Familial haemophagocytic reticulosis. *Arch Dis Child*. 1952; 27(136): 519–525.
46. Boake WC; Card WH, Kimmey JF. Histiocytic Medullary Reticulosis, Concurrence in Father and Son. *Arch Intern Med*. 1965; 116(2): 245–52.
47. Henter JL, Ehrnst A, Andersson J, Elinder G. Familial hemophagocytic lymphohistiocytosis and viral infections. *Acta Paediatr*. 1993; 82(4): 369–372.
48. Vaiselbuh SR, Bryceson YT, Allen CE, Whitlock JA, Abila O. Updates on histiocytic disorders. *Pediatr Blood Cancer*. 2014; 61(7): 1329–35.
49. Janka GE, Lehmborg K. Hemophagocytic lymphohistiocytosis: pathogenesis and treatment. *Hematology Am Soc Hematol Educ Program*. 2013; 2013: 605–11.
50. Chandrakasan S, Filipovich AH. Hemophagocytic lymphohistiocytosis: advances in pathophysiology, diagnosis and treatment. *J Pediatr*. 2013; 163(5): 1253–9.
51. Balwierz W, Czogała M, Pawińska–Wasikowska K, Cwiklińska M, Walicka–Soja K. Hemophagocytic lymphohistiocytosis: diagnostic problems in pediatrics. *Przegl Lek*. 2010; 67(6): 417–24.
52. Real E, Gomez A, Alcaraz MJ, Saez AI, Pastor E, Grau E. Fulminant hemophagocytic syndrome as presenting feature of T–cell lymphoma and Epstein–Barr virus infection. *Haematologica*. 2000; 85(4): 439–40.
53. Usmani GN, Woda BA, Newburger PE. Advances in understanding the pathogenesis of HLH. *Br J Haematol*. 2013; 161(5): 609–22.
54. Guo X, Li Q, Zhou CY, Zhao YN. Clinical analysis of Epstein–Barr virus–associated hemophagocytic syndrome in children. *Zhongguo Shi Yan Xue Ye XueZaZhi*. 2013; 21(2): 460–4.
55. Liapis K, Apostolidis J, Delimpasis S. EBV–associated hemophagocytic syndrome. *Am J Hematol*. 2011; 86(5): 422.
56. Henter JL, Nennesmo I. Neuropathologic findings and neurologic symptoms in twenty–three children with hemophagocytic lymphohistiocytosis. *J Pediatr*. 1997; 130(3): 358–65.
57. Haddad E, Sulis ML, Jabado N, Blanche S, Fischer A, Tardieu M. Frequency and severity of central nervous system lesions in hemophagocytic lymphohistiocytosis. *Blood*. 1997; 89(3): 794–800.
58. Janković G. Aplastic anemia. In: D. Manojlovic. *Internal Medicine*, 5th ed. Belgrade: The Institute for Textbooks, 2009; 1019–21.



59. Čolović M. Leucemias. In: D. Manojlovic. Internal Medicine, 5th ed. Belgrade: The Institute for Textbooks, 2009; 1031–43.
60. Aulbert E, Fromm H, Hornemann H. Ferritin in acute leukemia. Serum ferritin concentration as a nonspecific tumor marker for M1 and M2 myeloid leukemia. *Med Klin (Munich)*. 1991; 86(6): 297–304.
61. Huang SC, Chen JS, Cheng CN, Yang YJ. Hypoalbuminemia is an independent predictor for hemophagocytic lymphohistiocytosis in childhood Epstein–Barr virus–associated infectious mononucleosis. *Eur J Haematol*. 2012; 89(5): 417–22.
62. Eid A, Keddissi JI, Kinasewitz GT. Hypoalbuminemia as a cause of pleural effusions. *Chest* 1999; 115(4): 1066–9.
63. Tutor JD. Chylothorax in infants and children. *Pediatrics*. 2014; 133(4):722–33.
64. Popović G. Pleural effusions: a special review of pleural effusions in extrapulmonary disease. *Pneumon* 2010; 47(1-2): 73–80.
65. Kogawa K, Sato H, Asano T et al. Prognostic factors of Epstein–Barr virus–associated hemophagocytic lymphohistiocytosis in children: report of the Japan Histiocytosis Study Group. *Pediatr Blood Cancer*. 2014; 61(7): 1257–62.
66. Ishii E, Ohga S et al. Nationwide survey of hemophagocytic lymphohistiocytosis in Japan. *Int J Hematol*. 2007; 86(1): 58–65.
67. Chen CJ, Huang YC et al. Hemophagocytic syndrome: a review of 18 pediatric cases. *J Microbiol Immunol Infect*. 2004; 37(3): 157–63.
68. Bakhshi S, Pautu JL. EBV associated hemophagocytic lymphohistiocytosis with spontaneous regression. *Indian Pediatr*. 2005; 42(12): 1253–5.
69. Imashuku S. Treatment of Epstein–Barr virus–related hemophagocytic lymphohistiocytosis (EBV–HLH); update 2010. *J Pediatr Hematol Oncol*. 2011; 33(1): 35–9.
70. Marsh RA, Jordan MB, Filipovich AH. Reduced–intensity conditioning haematopoietic cell transplantation for haemophagocytic lymphohistiocytosis: an important step forward. *Br J Haematol*. 2011; 154(5): 556–63.
71. Shiraiishi A, Ohga S, Doi T et al. Treatment choice of immunotherapy or further chemotherapy for Epstein–Barr virus–associated hemophagocytic lymphohistiocytosis. *Pediatr Blood Cancer*. 2012; 59(2): 265–70.
72. Balamuth NJ, Nichols KE, Paessler M, Teachey DT. Use of rituximab in conjunction with immunosuppressive chemotherapy as a novel therapy for Epstein Barr virus–associated hemophagocytic lymphohistiocytosis. *J Pediatr Hematol Oncol*. 2007; 29(8): 569–73.