

# Acute Iliac and Femoral Arterial Thrombosis Secondary to Total Hip Arthroplasty

Nikola Fatic<sup>1\*</sup>, Nenad Zornic<sup>2</sup>, Nemanja Radojevic<sup>1</sup>, Nikola Bulatovic<sup>1</sup>

<sup>1</sup>Clinical Centre of Montenegro, Faculty of Medicine, University of Montenegro, Podgorica, Montenegro; <sup>2</sup>Clinical Centre of Kragujevac, Faculty of Medicine, University of Kragujevac, Kragujevac, Serbia

## Abstract

**Citation:** Fatic N, Zornic N, Radojevic N, Bulatovic N. Acute Iliac and Femoral Arterial Thrombosis Secondary to Total Hip Arthroplasty. OA Maced J Med Sci. 2014 Dec 15; 2(4):632-634. http://dx.doi.org/10.3889/oamjms.2014.113

**Key words:** acute thrombosis; iliac artery; femoral artery; hip arthroplasty.

**\*Correspondence:** Fatic, Nikola, MD, Surgeon resident, Department of Vascular Surgery, Clinical Centre of Montenegro, Ljubljanska 1, 20000 Podgorica, Montenegro. +382 69 181 032. E-mail: nikolafatic@hotmail.com

**Received:** 09-Oct-2014; **Revised:** 21-Nov-2014; **Accepted:** 13-Nov-2014; **Online first:** 04-Dec-2014

**Copyright:** © 2014 Nikola Fatic, Nenad Zornic, Nemanja Radojevic, Nikola Bulatovic. This is an open access article distributed under the terms of the Creative Commons Attribution License, which permits unrestricted use, distribution, and reproduction in any medium, provided the original author and source are credited.

**Competing Interests:** The authors have declared that no competing interests exist.

In the presented case report, we evaluated the mechanism of the external iliac, the common femoral and the superficial femoral arterial thrombosis secondary to total hip arthroplasty. A 75-year-old female suffered from 5.5 cm shorter left lower limb and same side coxarthrosis. Next day after arthroplasty and equalisation of the lower limbs, an acute ischemia of the treated leg was presented. Multiscan CT angiography revealed the presence of the external iliac, the common femoral and the superficial femoral arterial thrombosis. From the best of our knowledge, it seems to be the only case of this arterial segment thrombosis after total hip arthroplasty and equalisation of the lower limbs reported.

## Introduction

Approximately 100,000 total hip reconstructions are done annually in the United States [1]. Although they are rare, vascular injuries happen with total hip arthroplasty (THA) [2]. Arterial injury associated with elective orthopedic joint surgery is more common during redo procedures and in patients with preexisting atherosclerosis [3].

Vascular accidents occurring in the course of hip surgery may reach potentially catastrophic dimensions by posing an immediate and sudden threat to life and limb [4, 5]. Despite arterial repair/bypass, limb morbidity is common and related to preexisting occlusive disease or extent of arterial thrombosis [3]. Forehand use of Doppler ultrasound, multiscan CT angiography and aggressive revascularization are critical to achieving limb salvage.

The aim of this study was to present a case with acute iliac and femoral arterial thrombosis secondary to total hip arthroplasty.

## Case Report

A 75-year-old woman proceeded to the left total hip arthroplasty because of the coxarthrosis. In the age of seven she had a injury of the left femur, followed by a surgery procedure, that caused shortening of left lower limb. On physical examination, before orthopedic procedure, left lower limb was 5.5 cm shorter than right. The patient underwent to total hip arthroplasty and elongation of the shorten leg. The surgery was successful in reaching the equal length of both legs. The next day after the procedure the pulses on the left femoral, popliteal, and dorsalis pedis arteries were impalpable. Neurological examination revealed sensory deficit on the same lower limb, as well as paresis. A multiscan CT angiography of the abdominal aorta and left lower limbs showed complete occlusion – thrombosis of the left external iliac, common and superficial femoral artery without collateral blood supply of the lower limb (Figure 1).

The patient underwent to the transfemoral and transpopliteal balloon catheter thrombectomy with good anterograd and retrograd flow and 5 cm resection of localised contusion part of femoral

superficial artery in infrainguinal region which has been replaced with Dacron graft 6 mm. Fasciotomy of lower limb was performed, too, as a standard procedure. After the surgery patient used Clexane for seven days to protect deep vein thrombosis as well as thrombosis of the graft. After seven days we suggested to patient to use Plavix as a standard anti aggregation therapy.

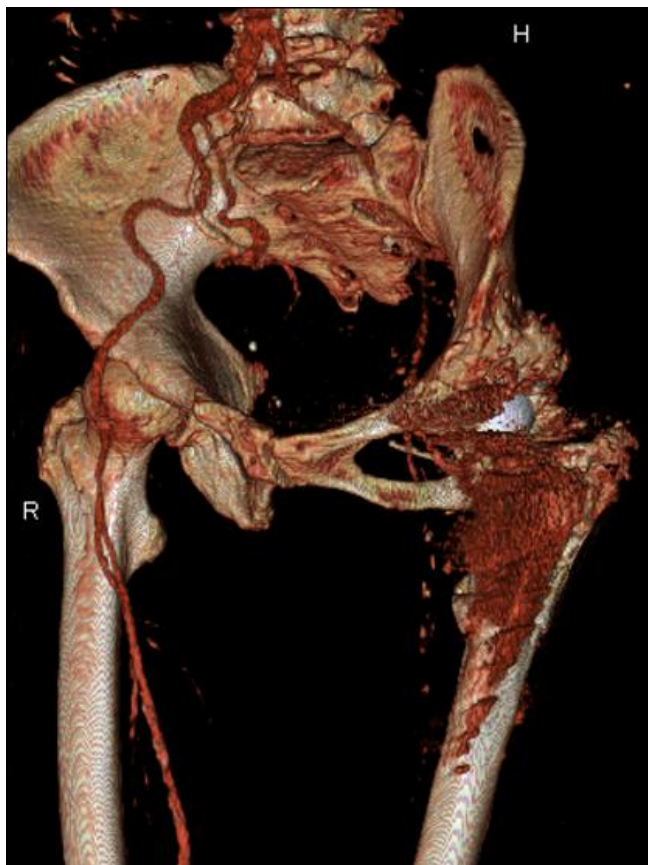


Figure 1: Multiscan CT angiography in the patient with acute iliac and femoral arterial thrombosis secondary to total hip arthroplasty.

Pathohistological examination using hematoxylin-eosin stains of the resected part of superficial femoral artery showed a contusion, superficial lacerations, denudation and atherosclerotic changes of the arterial endothelium throughout the affected vessels.

After the surgery, Color doppler scan showed successful revascularization of the left lower limb. The neurological symptoms resolved after the surgery. The Color doppler scan were performed at the hospital again prior to discharge, and repeated in the first and third month after the injury without showing any complication.

## Discussion

Vascular injuries during orthopedic hip surgery are rare. However, they must always be feared because they threaten the limb or even the life.

In the case under review here, the patient had shorter left lower limb as a consequence of injury and surgical procedure performed on left femur as a child. Equalisation of the lower limbs, after total hip arthroplasty for coxarthrosis, caused traumatic elongation of the arterial blood vessels, as well as nerves of lower limb. Furthermore, it caused contusion and superficial lacerations and denudation of atherosclerotic plaques on the arterial endothelium with consequent acute thrombosis. The elongation of the ischiadic nerve caused paresis.

Wilson JS et al. showed that arterial thrombosis was the most common abnormality identified (78%), followed by laceration/avulsion (11%) and pseudoaneurysm development (11%), and involved the iliac, common femoral, profunda and superficial femoral, popliteal, or tibial arteries after total knee arthroplasty (TKA) and THA [3]. Calligaro KD et al., among 23,199 TKA procedures (13,618 total, 11,953 primary, 1665 revision) and THR procedures (9581 total, 7812 primary, 1769 revision), showed acute arterial complications developed in 32 patients (0.13%), associated with 24 TKA procedures (0.17%) and 8 THA procedures (0.08%;  $p = .0609$ ) [6]. Leiva L et al. showed the most frequent locations of arterial lesion after hip arthroplasty were the external iliac artery, the common femoral artery, the internal iliac artery, and the deep femoral artery. The clinical presentation was internal bleeding (50%), acute limb ischemia (37%), and subacute limb ischemia (13%). The surgical interventions were bypass (50%), arteriorrhaphy (25%), primary repair (12.5%), and thrombectomy and patching (12.5%). One case was reoperated 6 years later, as they found a false anastomotic aneurysm in a previous ilio-femoral bypass. The death and amputation rates were 0% [2].

Duration of symptoms is of crucial importance in the treatment approach [7]. Blaisdell et al. [8] presented a concept of early heparinization to prevent the proximal and the distal propagation of thrombus combined with delayed intervention. Open surgical techniques for salvage of an ischemic limb include: balloon catheter thrombectomy, bypass procedures to direct blood flow beyond the occlusion, endarterectomy with or without patch angioplasty and intraoperative isolated limb thrombolysis. Unfortunately, the ability to rapidly restore arterial flow to the extremity with an operative procedure represents a significant insult to medically compromised individuals – one that all too frequently culminates in patient demise [9-11].

Pharmacologic thrombolysis and, more recently, percutaneous mechanical thrombectomy (PMT) hold potential in this regard. The introduction of catheter-directed locally-administered thrombolytic agents has challenged three decades of dominance of the Fogarty catheter thrombectomy. Thrombolysis with such agents as urokinase, rt-PA, streptokinase, and reteplase has been investigated in uncontrolled trials as a therapeutic alternative to operation for

acute peripheral arterial occlusion [7, 12-17].

In the presented case, the transfemoral and transpopliteal balloon catheter thrombectomy, with localised resection of superficial femoral artery and replacmnet with Dacron graft 6 mm , with fasciotomy of lower leg has been chosed due to the age of the patient and early confirmation of the diagnosis.

In a conclusion, this case emphasizes jatrogenic leason of the femoral superfital artery coused by to extensive traction, and the need for a high index of suspicion for vascular injuries following manipulation of limbs with underlying arterial thrombosis. Traction of low limb shouldn't be more then 2 cm. Equalization maneuvers for hip arthroplasty, should modified to minimize trauma and elongation of the arterial blood vessels and nerves of lower limbs. Serial postarthroplasty neurovascular exams are essential for identification and prompt management of neurovascular complications.

## References

1. Shoenfeld NA, Stuchin SA, Pearl R, Haveson S. The management of vascular injuries associated with total hip arthroplasty. *J Vasc Surg.* 1990;11:549-55.
2. Leiva L, Arroyo A, Gil J, Rodríguez AI, Abarrategui C, Lobato M, Gesto R. Arterial trauma in hip arthroplasty. *Cir Esp.* 2008;83:125-8.
3. Wilson JS, Miranda A, Johnson BL, Shames ML, Back MR, Bandyk DF. Vascular injuries associated with elective orthopedic procedures. *Ann Vasc Surg.* 2003;17:641-4.
4. Abularrage CJ, Weiswasser JM, Dezee KJ, Slidell MB, Henderson WG, Sidawy AN. Predictors of lower extremity arterial injury after total knee or total hip arthroplasty. *J Vasc Surg.* 2008;47:803-7; discussion 807-8.
5. Nachbur B, Meyer RP, Verkkala K, Zürcher R. The mechanisms of severe arterial injury in surgery of the hip joint. *Clin Orthop Relat Res.* 1979;141:122-33.
6. Calligaro KD, Dougherty MJ, Ryan S, Booth RE. Acute arterial complications associated with total hip and knee arthroplasty. *J Vasc Surg.* 2003;38:1170-7.
7. The STILE Trial: results of a prospective randomized trial evaluating Surgery versus Thrombolysis for Ischemia of the Lower Extremity. *Ann Surg.* 1994;220:251-266.
8. Blaisdell FW, Steele M, Allen RE. Management of acute lower extremity arterial ischemia due to embolism and thrombosis. *Surgery.* 1978;84:822-834.
9. Campbell WB, Rider BMF, Szymanska TH. Current management of acute leg ischemia: results of audit by the Vascular Surgical Society of Great Britain and Ireland. *Brit J Surg.* 1999;85:1498-1503.
10. Nypaver TJ, Whyte BR, Endean ED, et al. Nontraumatic lower-extremity acute arterial ischemia. *Am J Surg.* 1998;176:147-152.
11. Pemberton M, Varty K, Nydahl S, et al. The surgical management of acute limb ischemia due to native vessel occlusion. *Eur J Vasc Endovasc Surg.* 1999;17:72-76.
12. Ouriel K, Shortell CK, DeWeese JA, et al. A comparison of thrombolytic therapy with operative revascularization in the initial treatment of acute peripheral arterial ischemia. *J Vasc Surg.* 1994;19:1021-1030.
13. Ouriel K, Veith FJ, Sasahara AA, for the Thrombolysis or Peripheral Arterial Surgery (TOPAS) investigators. A comparison of recombinant urokinase with vascular surgery as initial treatment for acute arterial occlusion of the legs. *N Engl J Med.* 1998;338:1105-1111.
14. Hopfner W, Vicol C, Bohndorf K, et al. Shredding embolectomy thrombectomy catheter for treatment of acute lower-limb ischemia. *Ann Vasc Surg.* 1999;13:426-435.
15. Wagner H-J, Müller-Hülsbeck S, Pitton MB, et al. Rapid thrombectomy with a hydrodynamic catheter: results from a prospective, multicenter trial. *Radiology.* 1997;205:675-681.
16. Silva JA, Ramee SR, Collins TJ, et al. Rheolytic thrombectomy in the treatment of acute limb-threatening ischemia: immediate results and six-month follow-up of the multicenter Angiojet registry. *Cathet Cardiovasc Diagn.* 1998;45:386-393.
17. Henry M, Amor M, Henry I, et al. The Hydrolyser thrombectomy catheter: a single-center experience. *J Endovasc Surg.* 1998;5:24-31.