*Endocrine Journal* 2014, **61** (11), 1079-1086

**ORIGINAL**

# Surgical management of well-differentiated thyroid carcinoma in children and adolescents: 33 years of experience of a single institution in Serbia

Radan Dzodic[1), 2)], Marko Buta[1)], Ivan Markovic[1), 2)], Dusica Gavrilovic[3)], Milovan Matovic[4)], Igor Djurisic[1)], Zorka Milovanovic[5)], Gordana Pupic[5)], Slobodan Tasic[6)] and Nikola Besic[7)]

[1)] *Department of Surgical Oncology, Institute of oncology and radiology of Serbia, Serbia*
[2)] *University of Belgrade School of Medicine, Belgrade, Serbia*
[3)] *Department of biomedical statistics, Institute of oncology and radiology of Serbia, Serbia*
[4)] *Department of nuclear medicine, Clinical centar of Kragujevac, University of Kragujevac, School of Medicine, Serbia*
[5)] *Department of Pathology, Institute of oncology and radiology of Serbia, Serbia*
[6)] *Department of nuclear medicine, Institute of oncology and radiology of Serbia, Serbia*
[7)] *Department of Surgical Oncology, Institute of Oncology, Ljubljana, Slovenia*

**Abstract.** Well-differentiated thyroid carcinoma in children and adolescents is rare but demonstrates aggressive behavior. Gross lymph node metastases and distant metastases are common upon first clinical presentation. During a 33-year period (1981-2014) at the Institute of Oncology and Radiology of Serbia, 62 children and adolescents underwent surgery due to well-differentiated thyroid carcinoma. Mean age was 16.7 (range 7-21) years. At the time of diagnosis 6% of patients had lung metastases. Total thyroidectomy or completion thyroidectomy was performed for all patients followed by central neck dissection and frozen section examination of jugular-carotid compartments. Median follow-up was 10.9 (range 0.69-33.05) years and median tumor size was 20 (range 2-60) mm. Papillary carcinoma was found in 96%, and follicular and Hürthle cell carcinoma in 2% of patients. Multifocal tumors were found in 50% and capsular invasion in 60% of patients. Lymphonodal metastases in either central or lateral neck compartments were found in 73% of patients. Multifocality and capsular invasion were significantly more frequent in patients less than 16 years of age (both $p<0.01$). Median disease-free interval had not been reached and overall survival rate was 100%. Well-differentiated thyroid carcinoma in children and adolescents is characterized by a high rate of loco-regional aggressiveness, multifocality, capsular invasion, lymph node metastases and distant metastases at the time of diagnosis. Adequate surgical approaches should be performed for both primary and recurrent disease in young patients with well-differentiated thyroid carcinoma in order to achieve loco-regional disease control and longer disease-free survival.

*Key words:* Well differentiated thyroid carcinoma, Pediatric thyroid cancer, Surgical treatment

**DIFFERENTIATED** thyroid carcinoma is rare in pediatric population ranging from 0.5-3% [1]. Hogan *et al*. used the Surveillance, Epidemiology, and End Results (SEER) registry of the National Cancer Institute-U.S.A., from 1973 to 2004, to show an increase in the annual incidence of pediatric thyroid carcinoma by 1.1% per year [2]. Data from Great Britain report increase in thyroid cancer incidence in boys aged 0-14 from 0.2 to 0.6 and in girls from 0.3 to 0.5 persons per million [3]. Pediatric thyroid carcinoma clinically behaves different from the carcinomas in the adult population. Thyroid nodules in children and adolescents are almost ten times more often malignant than in adults [4]. Lymphonodal involvement is commonly present at first clinical presentation (35%-83%) and pulmonary metastases could be encountered in up to 16% [5-10]. The local and distance recurrence

Submitted May 13, 2014; Accepted Jul. 18, 2014 as EJ14-0226
Released online in J-STAGE as advance publication Aug. 12, 2014
Correspondence to: Marko Buta, M.D., Institute of Oncology and Radiology of Serbia, Department of Surgery, Pasterova 14, 11000 Belgrade, Serbia. E-mail: markobuta@gmail.com

Abbreviations: RAI, radioactive iodine; PTC, papillary thyroid carcinoma; CT, computed tomography; FNAb, fine needle aspiration biopsy; WBS, whole body scan; TT, total thyroidectomy; CND, central neck dissection; MRND, modified lateral neck dissection; SLN, sentinel lymph node; SD, standard deviation; DFI, disease free interval; OS, overall survival; FTC, follicular thyroid carcinoma; TSH, thyroid-stimulating hormone; Tg, thyroglobulin

may occur even after several years and the prognosis of these patients is relatively good even if distant metastases are present [11].

In this retrospective study we present single institution experience in the management of 62 patients under the age of 21 with well-differentiated thyroid carcinoma. We analyzed the clinical features, effectiveness of our surgical approach, radioactive iodine (RAI) therapy, thyroxin suppressive-substitutional treatment and long-term outcome of our patients with review of the literature.

## Materials and Methods

We enrolled 62 patients (14 boys and 48 girls) with the mean age of 16.7 (range 7-21) years who were treated at the Institute of Oncology and Radiology of Serbia from 1981 to 2014. Age distribution of patients is presented in Fig. 1.

The patients were divided into two groups: children under or equal to 16 (24 patients) and adolescents over 16 (38 patients). The female to male ratio was 2:1 in the children group, 5.3:1 in adolescent group and 3.4:1 as overall ratio. Median follow-up time was 10.9 years (Table 1).

Two patients had history of neck irradiation. One patient was diagnosed with papillary thyroid carcinoma (PTC) at the age of 17, twelve years after diagnosis of acute lymphoblastic leukemia for which was treated by whole body irradiation with 12Gy at the age of 5 and bone marrow transplantation at the age of 7. Another patient was treated by chemotherapy and 25Gy external radiotherapy due to Hodgkin's lymphoma at the age of 14, two years prior to diagnosis of PTC.

Patients were preoperatively staged according to TNM classification and regular work-up included cervical and abdominal echosonography, chest X-ray, indirect laryngoscopy, and complete thyroid hormone analysis including antibodies, thyroglobulin, calcitonin and parathyroid hormone. Chest computed tomography (CT) scan was performed in cases of suspected lung metastases. Five patients were preoperatively diagnosed as PTC by fine-needle aspiration biopsy (FNAb), while 11 by lateral neck lymph node surgical biopsy. Four patients were suspected to have pulmonary metastases at initial clinical presentation which were confirmed by CT scan and postoperative whole body scan (WBS) with RAI (Table 2).

All patients underwent total thyroidectomy (TT) or near TT. Central neck dissection (CND) was performed in all cases of thyroid carcinoma. Modified radical neck dissection (MRND) was performed after intraoperative frozen section confirmation of malignancy of non-palpable sentinel lymph nodes (SLN), or in cases when metastases were confirmed by lateral neck lymph node biopsy [12]. All patients underwent postoperative WBS with 0.5-3mCi of RAI. Indications for postoperative RAI ablation were extrathyroid carcinoma spread, lymph node metastases, and/or iodine uptake more than 2% after WBS. All patients are on lifelong L-thyroxin suppressive-substitutional therapy.

### *Statistical methodology*

For normal distribution data testing, the Kolmogorov-Smirnov and Shapiro-Wilk tests were used. Descriptive

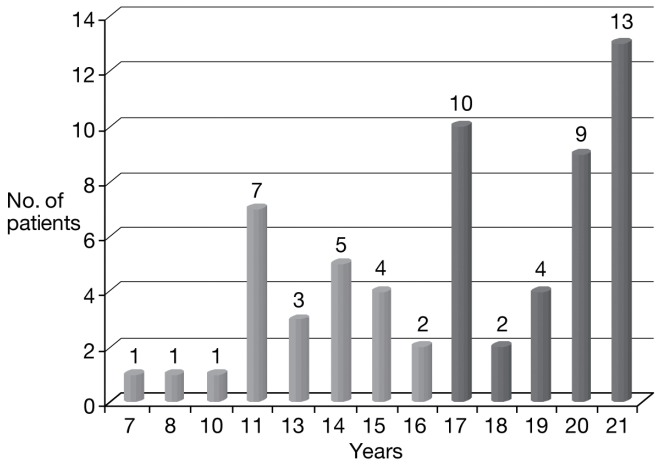


**Fig. 1** Age distribution of patients

**Table 1** Patients characteristics, initial pulmonary metastases and follow-up

| | Total | Children (≤16) | Adolescents (>16) |
|---|---|---|---|
| Patient characteristics | | | |
| Sex | | | |
| Male | 14 (23%) | 8 (33%) | 6 (16%) |
| Female | 48 (77%) | 16 (67%) | 32 (84%) |
| Age (years) | | | |
| Mean (SD) | 16.74 (3.83) | 12.62 (2.41) | 19.34 (1.63) |
| Median (Range) | 17 (7 – 21) | 13 (7 – 16) | 20 (7 – 21) |
| Initial pulmonary mets | | | |
| Without | 58 (94%) | 21 (88%) | 37 (97%) |
| With | 4 (6%) | 3 (12%) | 1 (3%) |
| Follow-up (years) | | | |
| Mean (SD) | 11.96 (7.70) | 11.83 (8.38) | 12.04 (7.35) |
| Median (Range) | 10.9 (0.7 –33.1) | 10.1 (2.0 –29.4) | 11.2 (0.7 – 33.1) |
| Total | 62 (100%) | 24 (100%) | 38 (100%) |

methods of statistical analysis (frequencies, percentages, mean, median, standard deviation [SD] and range) were used to summarize the data. The statistical significance level was set at $p<0.05$. Pearson $\chi^2$ test, Fisher Exact test and Wilcoxon rank sum test were used for testing the differences between age groups. Curves of probabilities for disease-free interval (DFI) and overall survival (OS) were constructed using the Kaplan-Meier product-limit method. The Log-rank test was used for testing differences between age groups for DFI. Data analysis was performed using the statistical program R version 3.0.2 (2013-09-25) -- "Frisbee Sailing"; Copyright (C) 2013; The R Foundation for Statistical Computing Platform: i386-w64-mingw32/i386 (32-bit); downloaded: 07.02.2014).

## Results

Over 90% of our patients had one of the three clinical presentations: palpable tumor in the thyroid gland, cervical lymphadenopathy or both. Treatment strategy is presented in Table 2. We have performed 44/62 (71%) MRND: 18/24 (75%) in children and 26/38 (69%) in adolescents (Pearson $\chi^2$ test; $\chi^2_1=0.31$; $p=0.58$). Bilateral MRND was performed slightly more often in children (29%) than adolescents group (16%) but without statistically significant differences (Table 2).

We had 8/62 (13%) patients with transitory hypocalcaemia which was normalized during four postoperative weeks and no patients had permanent hypocalcaemia. None of the patients had postoperative bleeding. In one child we had to resect recurrent laryngeal nerve due to infiltration of pT4a papillary thyroid carcinoma.

Over 96% of patients had PTC, one patient was diagnosed as follicular thyroid carcinoma (FTC) and one as Hürthle cell carcinoma based on the findings of capsular and vascular invasion. All patients were postoperative staged according to pTNM classification (Table 3). We have found that 71% of children and 63% of adolescents had metastases in the central neck compartment. The same percentage (71%) of children had metastases in the lateral neck region in comparison to 66% in the group of adolescents. There was no statistically significant difference in frequency of central, lateral or combination of the two between the age groups. Multifocality and capsular invasion were significantly more common in children (79% and 83%) than in adolescents (32% and 45%) (both $p<0.01$; Table 3).

Forty two patients (68%) underwent postopera-

**Table 2** Treatment and follow-up

| | Total | Children (≤16) | Adolescents (>16) |
|---|---|---|---|
| Surgery | | | |
| Thyroid | | | |
| Total thyroidectomy | 60 (97%) | 24 (100%) | 36 (95%) |
| Near total thyroidectomy | 2 (3%) | 0 (0%) | 2 (5%) |
| CND | 62 (100%) | 24 (100%) | 38 (100%) |
| SLN | | | |
| No | 33 (53%) | 15 (62%) | 18 (47%) |
| Yes | 29 (47%) | 9 (38%) | 20 (53%) |
| MRND | | | |
| No | 18 (29 %) | 6 (25%) | 12 (31%) |
| Unilateral MRND | 31 (50%) | 11 (46%) | 20 (53%) |
| Bilateral MRND | 13 (21%) | 7 (29%) | 6 (16%) |
| RAI therapy | | | |
| No | 20 (32%) | 6 (25%) | 14 (37%) |
| Yes | 42 (68%) | 18 (75%) | 24 (63%) |
| No of RAI treatments | | | |
| Mean (SD) | 1.95 (1.56) | 2.22 (1.90) | 1.75 (1.26) |
| Median (Range) | 1 (1 – 7) | 1 (1 – 7) | 1 (1 – 6) |
| Postoperative external RT | | | |
| No | 60 (97%) | 23 (96%) | 37 (97%) |
| Yes | 2 (3%) | 1 (4%) | 1 (3%) |
| Total | 62 (100%) | 24 (100%) | 38 (100%) |

**Table 3** pTNM classification and pathohistological characteristics of thyroid carcinomas

| Characteristic | Total | Children (≤16) | Adolescents (>16) |
|---|---|---|---|
| Thyroid carcinoma type | | | |
| PTC | 60 (96%) | 24 (100%) | 36 (94%) |
| FTC | 1 (2%) | 0 (0%) | 1 (3%) |
| Hurtle cell | 1 (2%) | 0 (0%) | 1 (3%) |
| pTNM classification | | | |
| pT | | | |
| T1a | 8 (13%) | 3 (12%) | 5 (21%) |
| T1b | 22 (36%) | 6 (25%) | 16 (42%) |
| T2 | 12 (19%) | 5 (12%) | 7 (19%) |
| T3 | 13 (21%) | 6 (25%) | 7 (19%) |
| T4 | 7 (11%) | 4 (17%) | 3 (8%) |
| pN | | | |
| pN0 | 17 (27%) | 6 (25%) | 11 (29%) |
| pN1a | 3 (5%) | 1 (4%) | 2 (5%) |
| pN1b | 42 (68%) | 17 (71%) | 25 (66%) |
| pM | | | |
| M0 | 58 (94%) | 21(88%) | 37 (97%) |
| M1 | 4 (6%) | 3(12%) | 1 (3%) |
| Multifocality | | | |
| No | 31 (50%) | 5 (21%) | 26 (68%) |
| Yes | 31 (50%) | 19 (79%) | 12 (32%) |
| Capsular invasion | | | |
| No | 25 (40%) | 4 (17%) | 21 (55%) |
| Yes | 37 (60%) | 20 (83%) | 17 (45%) |
| Central lymph nodes | | | |
| Negative | 21 (34%) | 7 (29%) | 14 (37%) |
| Positive | 41 (66%) | 17 (71%) | 24 (63%) |
| Lateral lymph nodes | | | |
| Negative | 20 (32%) | 7 (29%) | 13 (34%) |
| Positive | 42 (68%) | 17 (71%) | 25 (66%) |
| Central and lateral ln | | | |
| Negative | 17 (27%) | 6 (25%) | 11 (29%) |
| Lateral+ | 4 (6%) | 1 (4%) | 3 (8%) |
| Central+ | 3 (5%) | 1 (4%) | 2 (5%) |
| Central&Lateral+ | 38 (62%) | 16 (67%) | 22 (58%) |
| Total | 62 (100%) | 24 (100%) | 38 (100%) |

tive RAI ablation therapy due to extrathyroid carcinoma spread, lymph node metastases and/or iodine uptake more than 2% after WBS. Five patients had therapeutic RAI therapy due to pulmonary metastases. Median number of applied doses was 1.95 (range doses: 30-100) mCi, and median cumulative dose was 175mCi. All patients are on lifelong L-thyroxin suppressive-substitutional therapy. Two patients had postoperative radiotherapy due to pT4a thyroid carcinoma.

Forty eight patients out of 58 (83%) without initial pulmonary metastases are still disease free, with the median follow-up of 9.7 (range 1.98-33.05) years. Other 10/58 (17%) patients without initial pulmonary metastases developed local recurrence and one of them at the same time developed pulmonary metastases. For this subgroup, the median (range) for DFI and follow-up were respectively 1.25 (0.25-12.33) years and 14.85 (0.69-29.41) years.

Median DFI in children, adolescents and both groups combined is presented by Kaplan-Meier curves in Figs. 2 and 3. All patients are alive and there is no statistically significant difference in DFI between children and adolescents (Log-rank test; $\chi^2_1$=0.157; $p$=0.691; Fig. 2).

In our series 11/62 (18%) patients had locoregional recurrence and characteristics of these patients and treatment strategy are given in Table 4. Five patients (No. 2, 5, 6, 7 and 8) were not initially operated at our Institute and were sent to our clinic after being diagnosed as local recurrence. In this subgroup of patients all of them had initial tumor capsular invasion and 8/11 (73%) patients had extrathyroid tumor spread. After surgical treatment all patients received RAI treatment.

One patient (No. 1) developed a recurrence in the lymph nodes and soft tissues 148 months after ini-

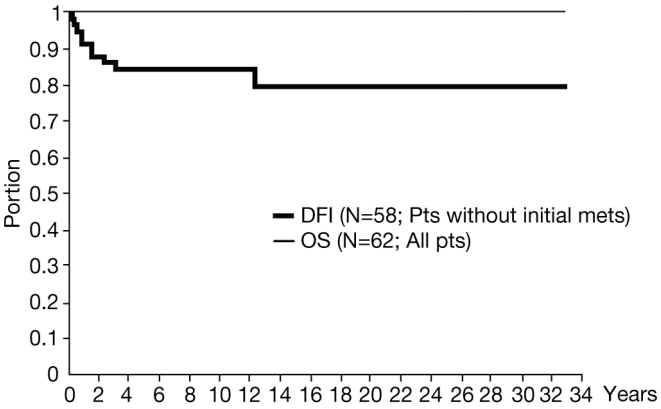


**Fig. 2** Disease free interval and overall survival in all patients

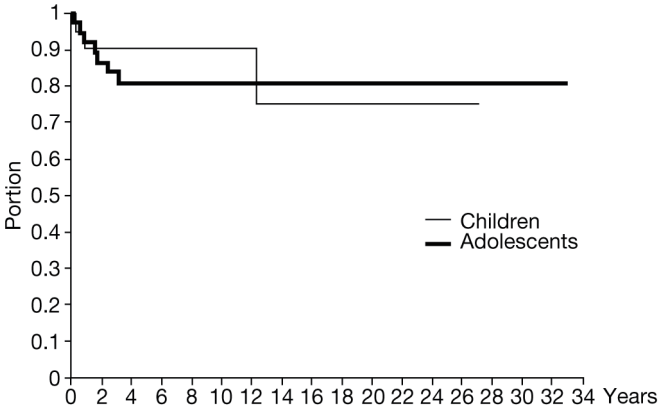


**Fig. 3** Disease free interval in children and adolescents

**Table 4** Patients with locoregional recurrence - characteristics

| No | Pts char. | | Initial Surgery | pTNM | | | Extra thyr spread | Reop | Recurrence type | | RAI No | Time to relapse (months) |
|---|---|---|---|---|---|---|---|---|---|---|---|---|
| | Age | Sex | | pT | pN | pM | | | Thyroid Bad | Lateral neck | | |
| 1. | 11 | F | TT, CND, MRND | 1b | 1b | No | No | MRND | | + (pd), pulm mets | 3 | 148 |
| 2. | 11 | F | TT, CND, MRND | 4 | 1b | Yes | Yes | CND, MRND bil | + (pd) | + (pd) | 6 | 22 |
| 3. | 13 | M | TT, CND, MRND | 4 | 1b | No | Yes | MRND | | + (pd) | 3 | 11 |
| 4. | 14 | F | TT, CND, MRND | 3 | 1b | No | Yes | MRND | | + (pd) | 3 | 5 |
| 5. | 17 | F | Near TT, MRND | 2 | 1b | No | No | CND, MRND contra lat. | + | + | 4 | 38 |
| 6. | 18 | M | TT | 3 | 1a | No | Yes | CND, SLNB bil | + | | 1 | 7 |
| 7. | 18 | F | TT | 3 | 1b | No | Yes | CND, MRND | + | + | 2 | 19 |
| 8. | 19 | F | TT | 4 | 1b | No | Yes | MRND bil | + | + | 1 | 20 |
| 9. | 21 | F | TT, CND, MRND bil | 1b | 1b | No | No | MRND | | + (pd) | 1 | 3 |
| 10. | 21 | M | TT, CND, MRND | 3 | 1b | No | Yes | MRND | | + | 3 | 11 |
| 11. | 21 | M | TT, CND, MRND bil | 4 | 1b | No | Yes | MRND | | + (pd) | 3 | 29 |

* TT, total thyroidectomy; Near TT, near total thyroidectomy; CND, central neck dissection; MRND, modified radical neck dissection; bil, bilateral; pd, previously dissected

tial surgery of pT1bN1b PTC and after application of one dose 60mCi of RAI. Pulmonary metastases were detected on postoperative WBS and the patient received two doses of RAI postoperatively (120mCi).

One patient (No. 2) out of four who had initial pulmonary metastases developed recurrence in both central and lateral, previously dissected neck compartments, 22 months after initial surgery. Patient received two doses of RAI (200mCi) before local recurrence and 4 doses of RAI after reoperation (240mCi).

We have observed five recurrences in the thyroid bed and 10 recurrences in the lateral neck region. All thyroid bed recurrences were observed in patients not initially operated in our hospital. Out of 5 patients who had central neck recurrence, 4 patients (No. 5, 6, 7 and 8) did not have central neck dissection performed. Patient No. 5 had thyroid bed recurrence 22 months after central neck dissection performed in other institution. None of the patients operated in our institute had thyroid bed recurrence. Out of 10 patients with lateral neck recurrences, six were observed in previously dissected neck regions. Four (No. 2, 6, 7, 8) out of ten patients with lateral neck recurrence were not initially operated at our institution (Table 4).

All patients who had reoperation due to local recurrence did not have recurrent disease again.

Initial pulmonary metastases were present in 4 patients and in one patient lung metastases were detected 148 months after initial surgery. After surgical procedure, which for all of them included total thyroidectomy, central neck dissection and bilateral modified neck dissection all patients received RAI treatment and lifelong L-thyroxin, thyroid-stimulating hormone (TSH) suppressive therapy. All patients are alive and have stable disease. Four out five patients with lung metastases have thyroglobulin (Tg) level under 2ng/mL after RAI therapy and are disease free. Only one patient with pulmonary metastases has Tg level 67ng/mL which remains stable after initial treatment with two times 100mCi and seven times with low doses of RAI (30mCi). Maximum dosage applied in one patient was 440mCi (Table 4, patient No. 5). Median follow-up for patients with initial pulmonary metastases is 12.43 (range 9.48-22.21) years.

## Discussion

In this study we demonstrated our surgical experience in treatment of thyroid carcinoma in children and adolescents. Thyroid carcinoma in pediatric population is rare and it occurs almost ten times less frequent than in adult population [2]. It is characterized by a higher recurrence rate than in adult population and although it presents often with initial distant metastases or advanced loco-regional disease, the prognosis is surprisingly favorable. Twenty four children and 38 adolescents were treated over the 33-year period in a single institution with a mean follow-up of 112 months. The overall female to male ratio was 3.4:1 which is similar to other published studies [11, 13, 14]. All our patients are alive.

One of the most described risk factors for developing differentiated thyroid carcinoma in childhood is radiation exposure, particularly exposure to low doses of head and neck irradiation (less than 30Gy) [15-17]. The latency period between radiation exposure and developing a thyroid carcinoma is between 10 and 20 years [18, 19], but after Chernobyl nuclear reactor explosion in 1986, the latency period was significantly shorter, 5 years [20-23].

In our series two patients were exposed to neck irradiation due to the treatment of acute lymphoblastic leukemia and Hodgkin's lymphoma with 12 and 25Gy with the latency period of 12 and 2 years, respectively.

There is an ongoing discussion regarding the most optimal treatment for this population of patients and all conclusions and therapeutic strategies have been formed based on retrospective data, small cohort studies and adult guidelines. There are no published randomized prospective therapeutic trials yet [11, 14, 24-39]. Surgery of thyroid carcinoma in children varies among institutions regarding the surgery on thyroid gland and the lymph nodes. Many authors prefer procedures less than total thyroidectomy [13, 25, 40, 41]. Our surgical strategy is similar to the management of adult differentiated thyroid carcinoma. Total or near total thyroidectomy and central lymph node dissection were performed in all patients after rapid frozen section confirmation of thyroid carcinoma. In a series reported by Enomoto *et al*. [25] total thyroidectomy was performed in 8%, by Wada *et al*. [41] in 25%, by Hay *et al*. [13] in 38% and by Ito *et al*. [40] in 54% of patients. The extent of surgery on central and lateral lymph nodes also varies among series. In our series, central lymph node dissection was performed in all patients similar to the series reported by Ito *et al*., while in other series it was not routinely performed [25].

In our study loco-regional recurrence was observed in 18%, which is in accordance with other studies [25,

33-41].

Indications for RAI treatment also vary in different series. There is a striking difference among Western countries and Japan where is some series [40] RAI was applied only in the presence of pulmonary metastases.

As shown in Table 3, only one of 20 patients (5%) with N0 or N1a and three of 25 (12%) patients without extrathyroid extension recurred. One might argue that these patients could be defined as low-risk patients and that our surgical approach is over-aggressive, but four out of five central neck recurrences were observed in patients who did not have CND. This justifies our approach that total thyroidectomy and central neck dissection are mandatory due to the fact that thyroid bed recurrences are potentially life threatening. This is the only series in which sentinel lymph node biopsy has been routinely applied for decision making for lateral neck dissection [12].

We believe that our more extensive surgical approach on the thyroid gland, central and lateral lymph nodes is responsible for our institution relatively low recurrence rate of 10% which is significantly lower than in other series [34]. In addition, none of our patients had permanent postoperative hypocalcaemia or accidental recurrent laryngeal nerve damage.

We claim that patients have a better outcome of local disease control if operated by a high volume, experienced thyroid surgeon, restating that the surgeon is a factor of prognosis in surgical oncology [42].

## Conclusion

Well-differentiated thyroid carcinoma in children and adolescents is characterized with high rate of loco-regional aggressiveness, multifocality, capsular invasion, lymph node metastases and distant metastases at the time of diagnosis. Adequate surgical approach should be performed by experienced surgical team in both primary and recurrent disease in young patients with well-differentiated thyroid carcinoma in order to achieve loco-regional disease control, minimize post-operative complications and accomplish longer disease-free survival.

## Acknowledgments

We thank Prof Akira Miyauchi for valuable comments and suggestions during the process of writing the manuscript and especially in the discussion section.

Written consents for surgery were given by patient's parents.

This study was supported by Grant 111601 from the Ministry of Education and Science, Republic of Serbia.

## Disclosure

None of the authors have any potential conflicts of interest associated with this research.

## References

1. Halac I, Zimmerman D (2005) Thyroid nodules and cancers in children. *Endocrinol Metab Clin North Am* 34: 725-744.
2. Hogan AR, Zhuge Y, Perez EA, Koniaris LG, Lew JI, et al. (2009) Pediatric thyroid carcinoma: incidence and outcomes in 1753 patients. *J Surg Res* 156: 167-172.
3. McNally RJ, Blakey K, James PW, Gomez Pozo B, Basta NO, et al. (2012) Increasing incidence of thyroid cancer in Great Britain, 1976-2005: age-period-cohort analysis. *Eur J Epidemiol* 27: 615-622.
4. Niedziela M (2006) Pathogenesis, diagnosis and management of thyroid nodules in children. *Endocr Relat Cancer* 13: 427-453.
5. Welch Dinauer CA, Tuttle RM, Robie DK, McClellan DR, Svec RL, et al. (1998) Clinical features associated with metastasis and recurrence of differentiated thyroid cancer in children, adolescents and young adults. *Clin Endocrinol (Oxf)* 49: 619-628.
6. Hallwirth U, Flores J, Kaserer K, Niederle B (1999) Differentiated thyroid cancer in children and adolescents: the importance of adequate surgery and review of literature. *Eur J Pediatr Surg* 9: 359-363.
7. Bingol-Kologlu M, Tanyel FC, Senocak ME, Buyukpamukcu N, Hicsonmez A (2000) Surgical treatment of differentiated thyroid carcinoma in children. *Eur J Pediatr Surg* 10: 347-352.
8. Robie DK, Welch Dinauer CA, Tuttle RM, Ward DT, Parry R, et al. (1998) The impact of initial surgical management on outcome in young patients with differentiated thyroid cancer. *J Pediatr Surg* 33: 1134-1138.
9. Jarzab B, Handkiewicz-Junak D, Wloch J, Kalemba B, Roskosz J, et al. (2000) Multivariate analysis of prognostic factors for differentiated thyroid carcinoma in children. *Eur J Nucl Med* 27: 833-841.
10. Alessandri AJ, Goddard KJ, Blair GK, Fryer CJ, Schultz KR (2000) Age is the major determinant of recurrence

in pediatric differentiated thyroid carcinoma. *Med Pediatr Oncol* 35: 41-46.
11. Zimmerman D, Hay ID, Gough IR, Goellner JR, Ryan JJ, et al. (1988) Papillary thyroid carcinoma in children and adults: long-term follow-up of 1039 patients conservatively treated at one institution during three decades. *Surgery* 104: 1157-1166.
12. Dzodic R, Markovic I, Inic M, Jokic N, Djurisic I, et al. (2006) Sentinel lymph node biopsy may be used to support the decision to perform modified radical neck dissection in differentiated thyroid carcinoma. *World J Surg* 30: 841-846.
13. Hay ID, Gonzalez-Losada T, Reinalda MS, Honetschlager JA, Richards ML, et al. (2010) Long-term outcome in 215 children and adolescents with papillary thyroid cancer treated during 1940 through 2008. *World J Surg* 34: 1192-1202.
14. Haveman JW, van Tol KM, Rouwé CW, Piers DA, Plukker JT (2003) Surgical experience in children with differentiated thyroid carcinoma. *Ann Surg Oncol* 10: 15-20.
15. Ron E, Lubin JH, Shore RE, Mabuchi K, Modan B, et al. (1995) Thyroid cancer after exposure to external radiation: a pooled analysis of seven studies. *Radiat Res* 141: 259-277.
16. Tucker MA, Jones PH, Boice JD Jr, Robison LL, Stone BJ, et al. (1991) Therapeutic radiation at a young age is linked to secondary thyroid cancer. *Cancer Res* 51: 2885-2888.
17. Davies SM (2007) Subsequent malignant neoplasms in survivors of childhood cancer: Childhood Cancer Survivor Study (CCSS) studies. *Pediatr Blood Cancer* 48: 727-730.
18. Sigurdson AJ, Ronckers CM, Mertens AC, Stovall M, Smith SA, et al. (2005) Primary thyroid cancer after a first tumour in childhood (the Childhood Cancer Survivor Study): a nested case-control study. *Lancet* 365: 2014-2023.
19. Dolphin GW (1968) The risk of thyroid cancers following irradiation. *Health Phys* 15: 219-228.
20. Ron E (2007) Thyroid cancer incidence among people living in areas contaminated by radiation from the Chernobyl accident. *Health Phys* 93: 502-511.
21. Demidchik YE, Saenko VA, Yamashita S (2007) Childhood thyroid cancer in Belarus, Russia, and Ukraine after Chernobyl and at present. *Arq Bras Endocrinol Metabol* 51: 748-762.
22. Williams ED (2006) Chernobyl and thyroid cancer. *J Surg Oncol* 94: 670-677.
23. Reiners C, Biko J, Haenscheid H, Hebestreit H, Kirinjuk S, et al. (2013) Twenty-Five Years After Chernobyl: Outcome of Radioiodine Treatment in Children and Adolescents With Very High-Risk Radiation-Induced Differentiated Thyroid Carcinoma. *J Clin Endocrinol Metab* 98: 3039-3048.
24. Cooper DS, Doherty GM, Haugen BR, Kloos RT, Lee SL, et al. (2009) Revised American Thyroid Association management guidelines for patients with thyroid nodules and differentiated thyroid cancer. *Thyroid* 19: 1167-1214.
25. Enomoto Y, Enomoto K, Uchino S, Shibuya H, Watanabe S, et al. (2012) Clinical features, treatment, and long-term outcome of papillary thyroid cancer in children and adolescents without radiation exposure. *World J Surg* 36: 1241-1246.
26. Stevens C, Al-Mahmeed H, Blair G, Prasil P, Haider F, et al. (2008) The Canadian Pediatric Thyroid Nodule Study: an evaluation of current management practices. *J Pediatr Surg* 43: 826-830.
27. Rivkees SA, Mazzaferri EL, Verburg FA, Reiners C, Luster M, et al. (2011) The Treatment of Differentiated Thyroid Cancer in Children: Emphasis on Surgical Approach and Radioactive Iodine Therapy. *Endocr Rev* 32: 798-826.
28. Veiga LH, Lubin JH, Anderson H, de Vathaire F, Tucker M, et al. (2012) A pooled analysis of thyroid cancer incidence following radiotherapy for childhood cancer. *Radiat Res* 178: 365-376.
29. Corrias A, Mussa A (2013) Thyroid nodules in pediatrics: which ones can be left alone, which ones must be investigated, when and how. *J Clin Res Pediatr Endocrinol* 5 Suppl 1: 57-69.
30. Niedziela M (2006) Pathogenesis, diagnosis and management of thyroid nodules in children. *Endocr Relat Cancer* 13: 427-453.
31. Schlumberger M, De Vathaire F, Travagli JP, Vassal G, Lemerle J, et al. (1987) Differentiated thyroid carcinoma in childhood: long-term follow-up of 72 patients. *J Clin Endocrinol Metab* 65: 1088-1094.
32. Leboulleux S, Hartl D, Baudin E, Schlumberger M (2012) Differentiated thyroid cancer in childhood. *Bull Cancer* 99: 1093-1099 (In French).
33. Park S, Jeong JS, Ryu HR, Lee CR, Park JH (2013) Differentiated thyroid carcinoma of children and adolescents: 27-year experience in the yonsei university health system. *J Korean Med Sci* 28: 693-699.
34. Thompson GB, Hay ID (2004) Current strategies for surgical management and adjuvant treatment of childhood papillary thyroid carcinoma. *World J Surg* 28: 1187-1198.
35. Handkiewicz-Junak D, Wloch J, Roskosz J, Krajewska J, Kropinska A, et al. (2007) Total thyroidectomy and adjuvant radioiodine treatment independently decrease locoregional recurrence risk in childhood and adolescent differentiated thyroid cancer. *J Nucl Med* 48: 879-888.
36. Vassilopoulou-Sellin R, Goepfert H, Raney B, Schultz PN (1998) Differentiated thyroid cancer in children and adolescents: clinical outcome and mortality after long-term follow-up. *Head Neck* 20: 549-555.

37. Ceccarelli C, Pacini F, Lippi F, Elisei R, Arganini M, et al. (1988) Thyroid cancer in children and adolescents. *Surgery* 104: 1143-1148.
38. Dinauer CA, Breuer C, Rivkees SA (2008) Differentiated thyroid cancer in children: diagnosis and management. *Curr Opin Oncol* 20: 59-65.
39. Welch Dinauer CA, Tuttle RM, Robie DK, McClellan DR, Svec RL, et al. (1998) Clinical features associated with metastasis and recurrence of differentiated thyroid cancer in children, adolescents and young adults. *Clin Endocrinol (Oxf)* 49: 619-628.
40. Ito Y, Kihara M, Takamura Y, Kobayashi K, Miya A, et al. (2012) Prognosis and prognostic factors of papillary thyroid carcinoma in patients under 20 years. *Endocr J* 59: 539-545.
41. Wada N, Sugino K, Mimura T, Nagahama M, Kitagawa W (2009) Treatment strategy of papillary thyroid carcinoma in children and adolescents: clinical significance of the initial nodal manifestation. *Ann Surg Oncol* 16: 3442-3449.
42. Pasieka JL (2000) The surgeon as a prognostic factor in endocrine surgical diseases. *Surg Oncol Clin N Am* 9: 13-20.